



Maxillary sinus mucocele: A case report

Tayebeh Ghasemi¹, Farzaneh Bolandparva^{1*}, Majid Beshkar²

1. Department of Oral and Maxillofacial Surgery, School of Dentistry, Tehran University of Medical Sciences, Tehran, Iran.

2. Craniofacial Research Center, Shariati Hospital, Tehran University of Medical Sciences, Tehran, Iran.

ARTICLE INFO

Article Type: Case Report

Received: 23 Apr. 2018

Revised: 28 May. 2018

Accepted: 15 Jul. 2018

*Corresponding author:

Farzaneh Bolandparva

Department of Oral and Maxillofacial Surgery,
School of Dentistry, Tehran University of Medical
Sciences, Tehran, Iran.

Tel: +98-21-84902473

Fax: +98-21-84902473

Email: f.bolandparva@gmail.com

ABSTRACT

Maxillary sinus mucocele is a benign uncommon cyst which is caused by the progressive accumulation of mucous. It presents with a slowly expanding growth and is asymptomatic at the beginning. Its signs and symptoms are nonspecific and mostly due to pressure effects on the orbit or other facial structures. The etiology of sinus mucocele formation is not well known. However, it is proposed that its formation might be due to obstruction of the ostium by inflammation or previous procedures such as Caldwell-Luc surgery. Endoscopic marsupialization of the mucocele is the procedure of choice, even though complicated cases are best treated by intraoral open procedures. We present a case of huge maxillary mucocele with a history of previous maxillary sinus surgery. Presentation and classic treatment are discussed.

Keywords: Mucocele, Maxillary sinus.

Introduction

Mucocele of the paranasal sinus is an epithelial lined, mucus containing sac that can fill the sinus completely and even expand the sinus walls. The fronto-ethmoid sinuses (89%) are the most commonly affected while the maxillary sinuses are less commonly involved (1%) [1]. It presents with a slowly expanding growth and is asymptomatic at the beginning. It develops as a result of an obstruction of the maxillary sinus or other paranasal sinuses due to chronic sinusitis, polyps, bone tumors, trauma or previous surgeries [2,3]. When the ostium is closed for a prolonged period of time, without any possibility of aeration and drainage, mucus accumulates gradually. This causes pressure that progressively expands the sinus, which in the long term can result

in bone deformation and destruction. Expansion takes place through the site of least resistance, which in the maxillary sinus is generally the medial and posterior walls [4]. Clinically, it can be associated with swelling of the cheek, diplopia and dental problems. It is generally painless and, when present, pain indicates infection of the mucocele [5]. It develops gradually, and has a higher incidence between the third and fourth decade of life, and there is no reported sex predilection [4,6]. Mucoceles in the maxillary sinuses are relatively rare, with prevalence ranging from 3 to 10% [7], and they are often secondary to scars from previous surgeries (e.g., Caldwell Luc procedure) [8-10].

Clinical Case

A 52-year-old male patient without any past medical history, was referred with a complaint of painless swelling in the right malar area. He had a history of maxillary sinus surgery about 13 years ago. Histopathologic evaluation of a recent incisional biopsy revealed a diagnosis of mucocele. A swelling in the right malar area and deepening of nasolabial fold (Fig 1) was observed in the clinical examination of the face. Intraoral examination showed that osseous borders of the right maxilla were expanded toward the vestibular space, extending from the second molar area to the midline. It is worth noting that the Overlying mucosa was free of lesion and had a normal color.

The Swelling was hard and firm to the touch, both on the vestibular and palatal sides. Computed tomography (CT) of the nose and paranasal sinus demonstrated large expansile homogenous mass measured 53*40 mm, involving the right maxillary sinus pushing its medial wall medially and occluding the right nasal cavity. There was mucosal thickening with deviation of nasal septum. Superior convexity and cortical thinning in the right orbital floor was evident. Bony defect in right zygomatic buttress and posterior portion of right palatine bone was also evident (Fig 2). Based on clinical, radiological features and previous biopsy a provisional diagnosis of a cystic lesion of right maxillary sinus compatible with mucocele was made. Treatment plan included excisional biopsy together with the curettage of the borders via a vestibular approach due to the large size of the lesion, under general anesthesia. During surgery, mucous discharged from the lesion (Fig 3). Histopathology of the cyst wall confirmed our diagnosis of mucocele demonstrating an exudate of neutrophils and macrophages, enmeshed in fibrin, with foci of hemorrhage and lined with pseudostratified ciliated columnar epithelium (Fig 4).

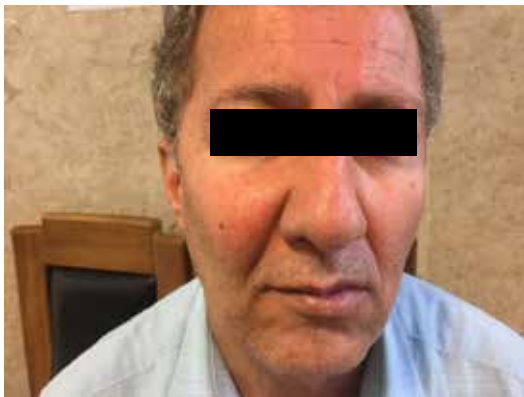

Fig 1. Swelling of the right malar area.

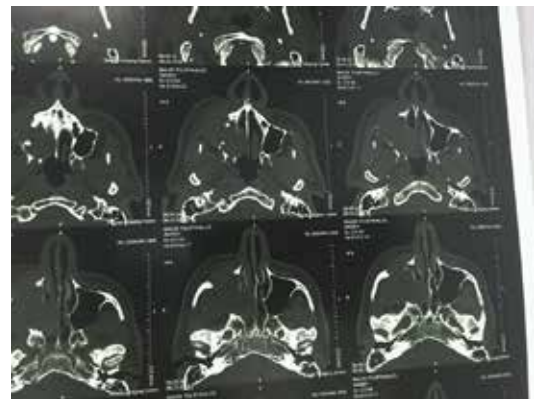
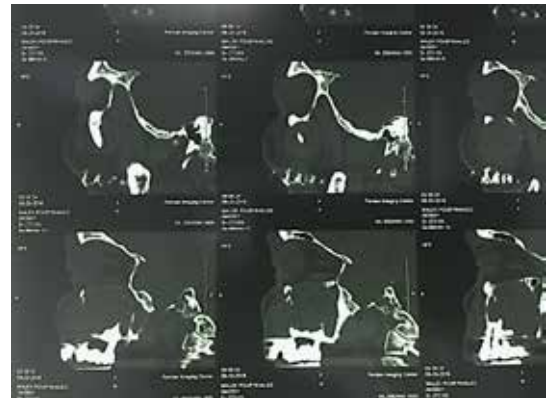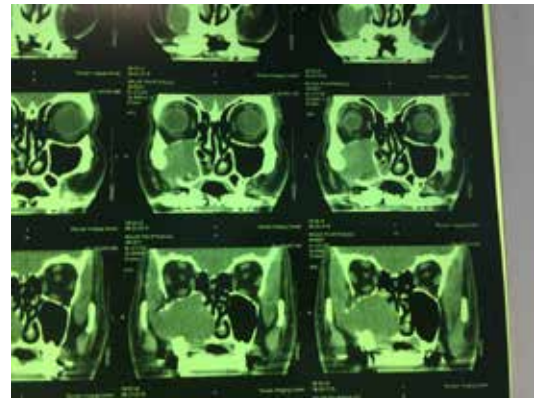


Fig 2. Axial & coronal & sagittal cuts of CT showing the extension of the lesion.

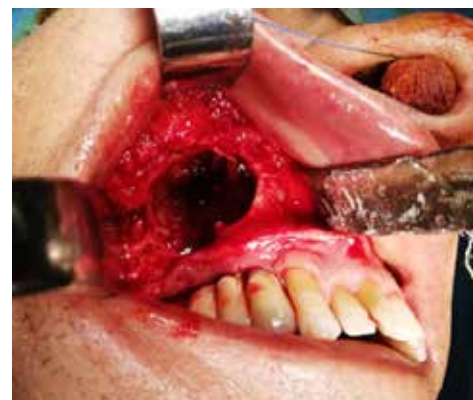

Fig 3. Intraoral view after enucleation and curettage.

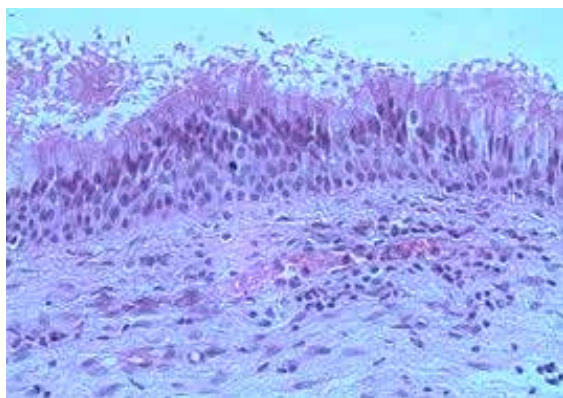


Fig 4. Histopathologic view of mucocele.

Discussion

Mucoceles result from an obstruction of the sinus ostia and drainage pattern, with accumulation of mucus within the sinus cavity. Continual accumulation causes it to expand due to the pressure. Maxillary sinus mucoceles are rare, with an incidence of 3–10% worldwide. They are usually sterile and painless with pain implying infection [1,11]. CT is the preferred imaging modality. In the early phases, diagnosis is fortuitous, taking place almost exclusively when a CT of the paranasal sinuses is taken [12], where mucocele appears as an expanded, airless sinus filled with homogeneous material. The walls of the sinus may be either normal or remodeled, with thickening, thinning and erosion to various degrees often within the same sinus. The distinction between a mucocele and a mucous retention cyst can be made by the presence of air outlining the upper surface of the retention cyst [11,13]. Expansion occurs as a result of positive pressure within the mucocele. Local production of bone resorption factors such as prostaglandins, interleukin1 and tumor necrosis factor have also been identified at the interface between the mucocele and bone. These may cause intraorbital or intracranial extension [14–16].

If there is expansion and destruction of the bone, the differential diagnosis includes malignant conditions, such as adenoid cystic carcinoma, plasmacytoma, rhabdomyosarcoma, lymphoma, schwannoma and odontogenic tumors [17]. In our patient, the lesion thinned all walls of the maxillary sinus. We argue that a large mucocele can cause bone erosion, but the homogeneous nature of the maxillary lesion, together with the preservation of the layers of mucosa adjacent to the eroded bone, reveal the benign nature of the lesion. Recommended treatment for mucoceles of the maxillary sinus without extension is endoscopic drainage with a broad antrostomy of the middle meatus. A Caldwell Luc surgical approach may also be necessary

in cases with extension into the soft tissues of the face or the pterygopalatine fossa, or when it has not been successfully drained through endoscopic surgery of the maxillary sinuses [18].

Conflict of Interest

There is no conflict of interest to declare.

References

- [1] Lund VJ. Mucoceles. In: Gleeson M, editor. Scott Brown's Otorhinolaryngology, Head and Neck Surgery. 7th ed. London: Hodder Arnold; 2008. p. 15318.
- [2] Costan VV, Popescu E, Stratulat SI. A new approach to cosmetic/esthetic maxillofacial surgery: surgical treatment of lateral exophthalmos due to maxillary uni sinus mucocele. *J Craniofac Surg*. 2013 May; 24(3): 914-916.
- [3] Mohan S. Frontal Sinus Mucocele with Intracranial and Intraorbital Extension: A Case Report. *J Maxillofac Oral Surg* [Internet] 2012; 11(3):337–339. Cited: 2016 Feb 16.
- [4] Fu CH, Chang KP, and Lee TJ. The difference in anatomical and invasive characteristics between primary and secondary para-nasal sinus mucoceles. *Otolaryngol Head Neck Surg* 2007; 136:621–625.
- [5] Mendelsohn DB, Glass RBJ, Hertzanu Y. Giant maxillary antralmucocele. *J Laryngol Otol*. 1984; 98:305-310.
- [6] Stiernberg CM, Bailey BJ, Calhoun KH, Quinn FB. Management of invasive frontoethmoidal sinus mucoceles. *Arch Otolaryngol Head Neck Surg* 1986; 112:1060–1063.
- [7] Natvig K, Larsen TE. Mucocele of the paranasal sinuses—a retrospective clinical and histological study. *J Laryngol Otol* 1978; 2:1075–1082.
- [8] Garg AK, Mugnolo GM, Sasken H. Maxillary antralmucocele and its relevance for maxillary sinus augmentation grafting: a case report. *Int J Oral Maxillofac Implants* 2000; 15(2):287-90.
- [9] Hasegawa M, Kuroishikawa Y. Protrusion of post-operative maxillary sinus mucocele into the orbit: case reports. *Ear Nose Throat J* 1993; Nov, 72(11):752-4.
- [10] Tuli I, Pal I, Chakraborty S, Sengupta S. Persistent deciduous molar as an etiology for a maxillary sinus mucocele. *Indian J Otolaryngol Head Neck Surg* [Internet] 2011; 63 (Suppl 1): 6-8. Cited:

2016 Feb16.

- [11] Tuli IP, Pal I, Chakraborty S, Sengupta S. Persistent deciduous molar as an etiology for a maxillary sinus mucocele. *Indian J Otolaryngol Head Neck Surg* 2011; 63(Suppl 1):6.8.
- [12] Som PM, Curtin HD. *Head and neck imaging*. 4th ed. v1. St. Louis: Mosby: Mosby, 838–840.
- [13] Eggesbø HB, Ringertz S, Haanaes OC, Dølvik S, Erichsen A, Stiris M, et al. CT and MR imaging of the paranasal sinuses in cystic fibrosis. Correlation with microbiological and histopathological results. *Acta Radiol* 1999; 40:15462.
- [14] Jones NS. Management of the frontal sinus. In: Lund VJ, editor. *Cummings Otolaryngology Head and Neck Surgery*. 5th ed. Philadelphia: Mosby Elsevier; 2010. p. 783.
- [15] Diaz F, Latchow R, Duvall AJ 3rd, Quick CA, Erickson DL. Mucoceles with intracranial and extracranial extensions. Report of two cases. *J Neurosurg* 1978; 48:284.8.
- [16] Zainine R, Loukil I, Dhaouadi A, Ennaili M, Mediouni A, Chahed H, et al. Ophthalmic complications of nasosinusmucoceles. *J Fr Ophtalmol* 2014; 37:938.
- [17] Busaba NY, Salman SD. Maxillary sinus mucoceles: clinical presentation and long-term results of endoscopic surgical treatment. *Laryngoscope* 1999; 109:1446–1449.
- [18] Bockmuhl U, Kratzsch B, Benda K, Draf W. Surgery for paranasal sinus mucoceles: efficacy of endonasal micro-endoscopic management and long term results of 185 patients. *Rhinology* 2006; 44:62–67.

Please cite this paper as:

Ghasemi T, Bolandparva F, Beshkar M; Maxillary sinus mucocele: A case report. *J Craniomax Res* 2018; 5(3): 139-142