



Evaluation of six radiomorphometric indices

Farzaneh Mosavat ¹, Alper Sinanoglu ², Zahra Khodadadi ^{1*}, Zahra Sadeghi Sabzevari ³

1. Department of Oral and Maxillofacial Radiology, School of Dentistry, Tehran University of Medical Sciences, Tehran, Iran.

2. Department of Oral and Maxillofacial Radiology, Faculty of Dentistry, Kocaeli University, Kocaeli, Turkey.

3. DDS, Private Office, Tehran, Iran.

ARTICLE INFO

Article Type:
Original Article

Received: 11 Oct. 2022

Revised: 2 Nov. 2022

Accepted: 10 Dec. 2022

*Corresponding author:

Zahra Khodadadi

Department of Oral and Maxillofacial Radiology,
School of Dentistry, Tehran University of Medical
Sciences, Tehran, Iran.

Tel: +98-912-0312467

Fax: +98-21-84902473

Email: z-khodadadi@razi.tums.ac.ir

ABSTRACT

Purpose: Aging is accompanied by the gradual loss of teeth, which can cause several orofacial changes. This study aimed to compare panoramic radiomorphometric indices between dentate and totally edentulous patients.

Materials and Methods: One hundred panoramic radiographs were analyzed to measure six indices using Clinview 9.3 software: the gonial angle (GA), antegonial angle (AGA), condylar height (CH), ramus height (RH), mental index (MI), and mandibular cortical index (MCI). An independent sample t-test and Chi-square was used to compare the means of the measured data between dentate and edentate subjects and genders.

Results: In both genders, dentate people had greater left CH ($p=0.05$) and left GA ($p=0.03$). Men had greater RH in the dentate and edentate groups ($p<0.001$). No correlation was found between groups and genders in MCI scores.

Conclusion: CH index assessment as the function of the masticatory muscles and GA as residual ridge resorption were decreased in edentulous people. The findings highlight the importance of oral hygiene education and prosthetic rehabilitation of the edentulous.

Keywords: Digital panoramic; Morphometric; Edentulous; Indices.

Introduction

The mandible undergoes several morphological changes due to aging accompanied with gradual loss of teeth and may become edentulous [1]. This chronic resorption process is affected by several factors such as gender, age, genetics, underlying disorders, edentulous period, sequence of tooth loss and other unfamiliar factors. Previous studies demonstrated that mandibular morphology changes as a result of tooth loss [2]. The wide use of panoramic radiography and its advantag-

es such as its availability, swiftness and low cost have led researchers to investigate the use of different qualitative and quantitative indices to assess mandibular bone quality. Considering dentition type, measurements of antegonial angle (AGA) presented a resorption pattern in edentulous patients [3]. The mandibular cortical index (MCI) was also suggested to be affected by age and edentulism [4]. Another study concluded that edentate patients had longer condylar height (CH) in comparison with dentate group

but ramus height (RH) showed no statistical differences between two groups. A flat mandibular plane, increased posterior facial height and an acute gonial angle (GA) was found to be associated with strong function of masseter and anterior temporal muscle [5]. There are only a few studies investigating GA and AGA in edentulous patients with conflicting results. GA was reported to be widened in edentulous patients [6], whereas another study stated that GA was not affected by gender and tooth loss [7].

Patients with a history of osteoporotic fractures also have shown more resorption and thinning in lower cortex of the mandible [8]. The radiographic features of the jaws can be affected by osteoporotic process, so the correlation between the degree of osteoporosis and the mandibular morphology can be determined with the evaluation of the thickness of mandibular inferior cortex. This assessment may provide an extraordinary opportunity for early osteoporotic diagnosis [9]. From another perspective, such morphometric investigations of mandible are also beneficial for prosthetic and preprosthetic surgical treatment planning procedures. For specific orthognathic surgery osteotomies which are performed GA site, the resorption pattern of this specific area may become prerequisite. In addition, such morphometric data regarding the differences in the mandibular morphology between men and women can also be used for forensic purposes and anthropometry [4,10]. Considering the limited number of studies investigating the relationship of GA, AGA, MCI, CH and RH of edentulous patients, this present study aimed to evaluate dimensional and morphological changes of the mandible based on digital panoramic radiographs in dentate and totally edentate patients.

Materials and Methods

This cross-sectional study was approved by Ethical Committee of Tehran University of Medical Sciences. The study retrospectively evaluated 100 panoramic images of 50 dentate and fifty totally edentate patients from the database of the Department of Oral and Maxillofacial Radiology, Faculty of Dentistry, Tehran University of Medical Science.

Image Acquisition

The panoramic radiographs were taken with the same digital panoramic machine (Planmeca Proline cc 2002, Helsinki, Finland). Adjustments were performed for each individual for the best image quality operating with 66-72 kVp, 10-14 sec and 8-14 mA exposure parameters.

Case Selection

For the edentulous group, totally edentate patients with repaired sockets of extracted teeth were included in the study. For the dentate group, patients with all posterior teeth except third molar were included in the study. Patients with systemic diseases effecting bone density and history of trauma or surgery in oral and maxillofacial area were excluded from the study. Low quality images with any distortion and images with undetectable areas of condylar head, posterior border of the ramus and mandibular lower border were also excluded.

Morphometric Measurements

All measurements were conducted by an experienced oral radiologist. One month after the first assessment, all measurements were repeated for calculating intraobserver agreement.

1- Gonial angle (GA): The angle formed by the junction of two lines. One of the line tangent to the lower border of the mandible and another tangent to the posterior border of the ramus on each side [11]. (Fig. A.1).

2- Antegonial angle (AGA): It is measured by determining two lines parallel to the antegonial angle region in the intersection of the antegonial notch's deepest point [12]. (Fig. A.2).

3- Mental index (MI): the lower border cortex width of the mandible at the mental foramen area using Ledgerton et al. technique [13,14]. (Fig. A.3).

4- Mandibular cortical index (MCI): this index represents the porosity and morphology of the mandibular lower cortex and was determined by observation the deepest point of the antegonial notch at both sides of the mandible according to Klemetti's classification mentioned below [15] (Fig. B):

C1: The endosteal margin of the mandibular cortex is even and sharp on right and left sides. (Fig. B1).

C2: The endosteal margin has semilunar defects (resorption cavities) with cortical residues. (Fig. B2).

C3: The cortical layer contains heavy endosteal cortical residues and is clearly porous. (Fig. B3).

5- Condylar height (CH): Two line drawn perpendicular to the ramus tangent line at the level of the most lateral aspect and most superior part of the condyle. The distance between these lines is CH. (Fig. C).

6- Ramus height (RH): Two lines drawn perpendicular

to the ramus tangent line (a line tangent to the posterior border of mandibular ramus) at the level of the most lateral points of the mandibular condyle and ramus. RH was the vertical distance between these lines. (Fig. C).

Statistical Analysis

Statistical analysis was performed using SPSS version 24.0. An independent sample t test, Chi square and Two-way analysis and ANOVA of variance were carried out to compare the means of the GA, AGA, MI, MCI, CH and RH between dentate and edentate patients as well as between both genders. To evaluate intraobserver reliability, intraclass correlation coefficient (ICC) was used for measuring the 30 randomly selected panoramic images which were assessed two times at a 4 weeks' interval. Statistical significance level was accepted as p lower than 0.05.

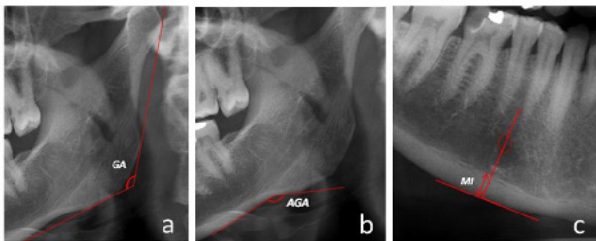


Fig. A.1: Gonial angle (GA).

Fig. A.2: Antegonial angle (AGA).

Fig. A.3: MI measurement.

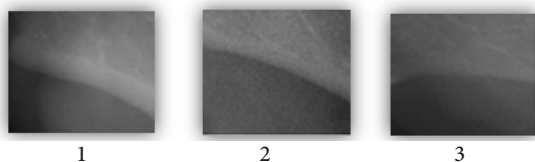


Fig. B: MCI: 1: Normal, 2: Mild, 3: Sever.

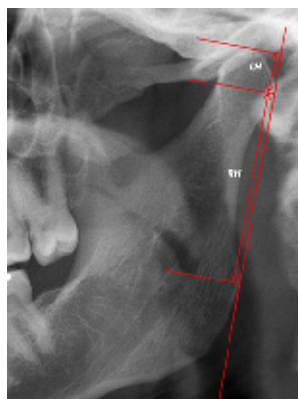


Fig. C: CH and RH measurement.

Results

After evaluating abundant radiographs, 100 panoramic images with the inclusion criteria were analyzed. The age and sex in two groups were relatively matched. The subjects age ranged between 40 to 67 years, with a mean (standard deviation) of 57.14 (± 7.51) and 39-65 years, with a mean (standard deviation) of 49.08 (± 6.85) in the edentulous and dentate group, respectively. The study sample was included of 50 patients in edentulous group among which 26 (52%) were women and 24 (48%) men and 50 patients in dentate group composed of 25 (50%) women and 25 (50%) men.

The mean and standard deviation of CH in the dentate and edentate groups of both genders on both sides are shown in Table A. Women had greater CH in both groups on both sides, but no significant differences were observed. In the condylar height of both genders. The difference between dentate and edentate groups was significant on left side ($p < 0.05$). Intraobserver reliability was 0.95 and 0.88 for RCH and LCH respectively both represented excellent agreement. The values obtained for RH of the different groups and genders are shown on Table B. Considering dentition type, dentate group had greater RH on both sides with no significant differences. Whereas the difference between men and women on both sides was statistically significant and men had longer ramus ($p < 0.05$). Intraobserver reliability was 0.90 for RRH and 0.97 for LRH. Gonial angles did not differ among genders on the left side. While on the right side, men had greater gonial angle in both dentate and edentate groups and this difference was significant in edentate group (p -dentate group < 0.05 , p -edentate group > 0.05) (Table C). The ICC value for Intraobserver reliability of RGA and LGA was 0.86 and 0.94 respectively. The AGA measurements of dentate/edentate group, stratified by sex, for both sides are displayed on Table D. Considering gender, women in both dentate and edentate groups had greater antegonial angle on both sides and no significant difference on both sides were found. Dentate group had greater antegonial angle on right side. Intraobserver reliability for AGA was 0.76 on the right side and 0.90 on the left side. The MI analysis showed no statistically significant difference between dentate and edentate groups. Also, there was no difference between men and women MI in both groups and both sides except RMI in edentate group, in which men had greater MI. Intra observer reliability measured for MI and the results was 0.92 on the right and 0.84 on the left side (Table E). Table F shows the number of the patients in three different MCI categories.

ries. All subcategories of MCI including C1, C2, and C3 were observed in both dentate and edentate groups. Categories of C2 and C3 were more frequent in dentate and edentate groups in both genders and sides. There

were no significant differences between genders and groups on both sides. Intra observer reliability measured for MCI was similarly 0.95 on both sides.

Table A. RCH and LCH measurements of both genders in both groups.

Dentition	Gender	LCH (±SD)	RCH (±SD)
Edentate	Male	6.75 (±1.90)	6.83 (±1.64)
	Female	7.10 (±1.14)	6.87 (±1.50)
Dentate	Male	7.84 (±2.35)	7.28 (±1.86)
	Female	8.06 (±1.43)	7.87 (±1.92)

LCH: Left Condyle Height; RCH: Right Condyle Height; SD: Standard deviation.

Table B. RRH and LRH measurements of both genders in both groups.

Dentition	Gender	LRH (±SD)	RRH (±SD)
Edentate	Male	45.73 (±3.84)	44.85 (±4.05)
	Female	39.84 (±5.47)	39.80 (±5.59)
Dentate	Male	46.22 (±4.12)	45.18 (±4.31)
	Female	41.67 (±4.83)	41.08 (±3.70)

LRH: Left Ramus Height; RRH: Right Ramus Height; SD: Standard deviation.

Table C. RGA and LGA measurements of both genders in both groups.

Dentition	Gender	LGA (±SD)	RGA (±SD)
Edentate	Male	123.98 (±9.02)	126.92 (±7.12)
	Female	123.82 (±9.06)	119.33 (±9.89)
Dentate	Male	126.84 (±6.76)	123.53 (±6.94)
	Female	127.99 (±7.15)	123.17 (±7.09)

LGA: Left Gonial Angle; RGA: Right Gonial Angle; SD: Standard deviation.

Table D. RAGA and LAGA measurements of both genders in both groups.

Dentition	Gender	LAGA (±SD)	RAGA (±SD)
Edentate	Male	158.04 (±7.85)	158.63 (±6.67)
	Female	161.72 (±8.20)	161.26 (±6.43)
Dentate	Male	160.03 (±8.63)	157.03 (±7.32)
	Female	160.49 (±4.37)	159.06 (±5.17)

LAGA: Left Antegonial Angle; RAGA: Right Antegonial Angle; SD: Standard deviation.

Table E. RMI and LMI measurements of both genders in both groups.

Dentition	Gender	LMI (±SD)	RMI (±SD)
Edentate	Male	3.08 (±1.03)	3.33 (±1.05)
	Female	3.28 (±1.16)	3.18 (±0.96)
Dentate	Male	3.48 (±0.77)	3.63 (±0.73)
	Female	3.61 (±0.73)	3.54 (±0.68)

LMI: Left Mental Index; RMI: Right Mental Index; SD: Standard deviation.

Table F. MCI classifications of both genders in both groups.

Dentition	Gender	RMCI			LMCI		
		C1 (%)	C2 (%)	C3 (%)	C1 (%)	C2 (%)	C3 (%)
Edentate	Male	7 (29.17%)	17 (70.83%)	0 (0.00%)	7 (29.17%)	16 (66.67%)	1 (4.17%)
	Female	7 (26.92%)	16 (61.54%)	3 (11.54%)	9 (34.62%)	16 (61.54%)	1 (3.84%)
Total		14 (28.00%)	33 (66.00%)	3 (6.00%)	16 (32.00%)	33 (66.00%)	2 (4.00%)
Dentate	Male	9 (36.00%)	16 (64.00%)	0 (0.00%)	10 (40.00%)	15 (60.00%)	0 (0.00%)
	Female	9 (36.00%)	15 (60.00%)	1 (4.00%)	15 (60.00%)	9 (36.00%)	1 (4.00%)
Total		18 (36.00%)	31 (62.00%)	1 (2.00%)	25 (50.00%)	24 (48.00%)	1 (2.00%)

LMCI: Left Mandibular Cortical Index; RMCI: Right Mandibular Cortical Index; SD: Standard deviation.

Discussion

Mandibular bone is accepted to be in a constant state of remodeling throughout life which can be traced via evaluation of some morphological and anatomical parameters. Considering evaluation of mandible, the panoramic radiograph has been used as the method of choice for some parameters measurements in previous studies [16]. Panoramic images can prevent the superimposition of contralateral structures, which is inevitable in lateral cephalometric radiographs hence panoramic seems to be better technique in this manner [17].

The condylar height (CH) has been used to evaluate the vertical skeletal patterns in. In overall, after loss of teeth, the function of masticatory jaw muscles decreases which can change the morphology of the mandibular bone and it justifies that dentate patients had greater condylar height rather than edentates [16,18]. In accordance, in this present study there was significant difference between dentate and edentate groups, especially on left side. However, insignificant higher CH in partially edentulous than fully dentate group was reported [19]. Considering the genders, Huuonen et al. reported that men had greater CH than women [18]. In our study, women had greater CH in both groups on both sides, but no significant differences were detected.

Ramus height (RH) was reported to be affected by factors as aging and edentulism. Various studies reported that RH in senile dentate patients were higher, in regard to edentate [6,16,18,20,21]. An RH increase in 20-39 years old participants [22] which decrease with age in dentate group [22] is reported. Somehow, it is in accordance with Bahija et al. reporting lower RH with increasing in age in dentate group [19]. Decreased RH is associated with reduction in development of mandible which may have led to mandibular condyle degeneration and facial asymmetry [23]. In the present study, dentate group had greater RH than edentates

and there was no significant difference between them on both sides. Although, some studies found significant difference between men and women on both sides [23-25]. The results of our study showed that edentulous patients have not only decreased RH but also lower CH. Similarly, Fouda et al. found lower CH in edentate females, however, larger CH in edentate males [21]. Also, some other studies reported that considering genders, men had significantly larger ramus height [18,22]. This finding supports the results of our study and may be related to the stronger masticatory muscles in men which prevents the bone from resorption. Furthermore, bone resorption occurs more frequently in women especially after menopause due to hormonal changes.

According to the results of our study, although dentate group in both genders had greater gonial angle (GA) on both sides, no significant difference was found between the dentate and edentate groups on the left side. Many previous studies have reported non-widening of the GA in edentates [5,6,26-28]. Lonberg et al. demonstrated that GA was increased in dentate group [29]. Also, some studies reported statistically insignificant relation of dentition and GA value [7,30,31]. Conversely, other studies have shown that GA size increases in edentates [11,17,18,21,24,32]. Moreover, higher GA in partially edentates in comparison to fully dentate participants has been reported [19]. Also, some studies found higher GA with increase in age [10,19,22]. Based on the literature, GA undergoes decreasing phase in the following years after tooth extraction [17]; also, there is another study reporting decrement of GA until 55 years and increase of it above 65 years [31]. These variations in findings suggests that GA size differs due to dentate/edentate state, age, the use of denture and duration of edentulism [6,17,31]. According to our results on the right side, men had greater GA in both dentate and edentate groups which is in agreement with some previous studies [22,29,33].

Otherwise, some previous studies reported higher GA [7,30,34], but lower AGD versus males [30]. This contradiction can be attributed to the sample size of studies and not categorizing participants by age [33]. It can be explained by downward and backward rotation of mandible in women versus forward mandibular rotation in men [35]. An obtuse growth potential of the lower jaw is broadly determined by GA size, while a large GA, represents higher growth potential of mandible. As men have greater mandible, so we expect to they have greater GA [36]. Some studies found that females had greater antegonial angle (AGA) size compared to males [7,10,11,37]. In our study, we get similar results, which can be related to skeletal muscle activity. The antegonial region can be affected by bone resorption as result of the decreased muscle fiber tensions [27,38]. These losses of muscle mass and strength occurs more in women. This decrease may be related with systemic factors, vitamin D deficiency which is more frequent in post-menopausal women and aging.

Dutra et al. found that dentates had greater AGA size than edentates which conflicts our results [7]. The difference is because of the method of dentate group selection; in their study only mandibular teeth were considered to determine dentition type. Tozoglu et al. found that the edentate subjects had greater AGA than dentate subjects and supports our results [11]. Some evidence suggested that due to the muscle atrophy, the number of muscle cells and fibers at AG site decrease and masticatory muscle function is reduced in edentate patients. As a result of this loss, the antegonial region may become more sensitive to bone resorption.

In the term of mental index (MI), we found that regarding dentition type there was no significant difference in the MI of both genders, which is in accordance with Akay et al. [39] that concluded there is not a statistically significant relation in early posterior mandibular tooth loss in young adult and any change of MI. Some studies found that dentates had greater MI than edentates and supports our results and may be because of masticatory muscles' function which supports bone from resorption in dentate group [40]. In dentate patients, all masticatory muscles have a role in mastication. The masseter and temporal muscle weakness are related to loss of teeth. The edentulousness duration and probably low masticatory power may be due to the alteration of MI index. Metabolic bone loss is correlated with the reduction of cortical bone thickness. Some studies found that men had greater MI than women which support our findings [14,40]. Metabolic effects due to hormonal changes of women affect bone and

hence, the MI index. Therefore, possible preventive measures must be taken to avoid extractions and to preserve the bone structure and morphology of mandible. The mandibular cortical index (MCI) delineates the amount of porosity in the cortical layer in the mandibular base and is represent the bone mineral density [41,42]. Some studies found as age increased and the number of teeth decrease, the number of the C2 and C3 categories increased. Furthermore, they said dentition type and age can be considered as one of the great significant indicator which influence MCI [4,11,40]. These findings are consistent with present study. Although, C2 Category was more frequently seen in dentate and edentate groups in both genders on both sides but C3 in edentates and C1 in dentate group was common category. There is a lifelong remodeling in the mandibular cortex. The remodeling is an extremely accurate process which preserve a balance among bone resorption and formation. This balance alters with increasing age and loss of functional dentition resulting in decreasing MCI index. Some studies reported that MCI values were significantly influenced by gender [40,41], which is in agreement with our results. Although, there were no significant differences between genders, but, C3 category was more frequent in females than in males. We did not record any information on duration, sequence of tooth loss, and wearing or not wearing of dentures. Also, we do not have any information about interarch and intraocclusal relationships. Further investigations in a larger sample size would be necessary to confirm our findings.

Conclusions

Considering our results for dentate and edentate groups, it can be concluded that tooth loss leads to morphological changes in mandible and maintaining natural dentition is an important goal. The findings of this study highlight the significance of conventional or implant-retained prosthetic rehabilitation of totally edentate patients to maintain functioning of the masticatory muscles.

Conflict of Interest

There is no conflict of interest to declare.

References

- [1] N. G. Chander, "Prudential analysis of methods in the selection of teeth for complete denture," *J Indian Prosthodont Soc*, vol. 21, no. 3, p. 215, 2021.
- [2] Z. Aytekin and S. G. Yilmaz, "Evaluation of os-

- seous changes in dental panoramic radiography using radiomorphometric indices in patients with hyperthyroidism,” *Oral Surg Oral Med Oral Pathol Oral Radiol Endod*, vol. 133, no. 4, pp. 492-499, 2022.
- [3] A. Bakan, P. Kervancıoğlu, İ. Bahşi, and E. D. Yalçın, “Comparison of the Gonial Angle With Age and Gender Using Cone-Beam Computed Tomography Images,” *Cureus*, vol. 14, no. 5, 2022.
- [4] A. Gulsahi, B. Yuzugullu, P. Imirzalıoğlu, and Y. Genç, “Assessment of panoramic radiomorphometric indices in Turkish patients of different age groups, gender and dental status,” *Dentomaxillofac Radiol*, vol. 37, no. 5, pp. 288-292, 2008.
- [5] Q.-F. Xie and A. Ainamo, “Correlation of gonial angle size with cortical thickness, height of the mandibular residual body, and duration of edentulism,” *J Prosthet Dent*, vol. 91, no. 5, pp. 477-482, 2004.
- [6] R. Okşayan, B. Asarkaya, N. Palta, İ. Şimşek, O. Sökücü, and E. İşman, “Effects of edentulism on mandibular morphology: evaluation of panoramic radiographs,” *Sci. World J.*, vol. 2014, 2014.
- [7] V. Dutra, J. Yang, H. Devlin, and C. Susin, “Mandibular bone remodelling in adults: evaluation of panoramic radiographs,” *Dentomaxillofac Radiol*, vol. 33, no. 5, pp. 323-328, 2004.
- [8] I. Karadag and H. G. Yilmaz, “Evaluation of change in trabecular bone structure surrounding dental implants by fractal dimension analysis and comparison with radiomorphometric indicators: a retrospective study,” *PeerJ*, vol. 10, p. e13145, 2022.
- [9] T. F. Tozum and A. Taguchi, “Role of dental panoramic radiographs in assessment of future dental conditions in patients with osteoporosis and periodontitis,” *N Y State Dent J*, vol. 70, no. 1, p. 32, 2004.
- [10] S. Ghosh, M. Vengal, K. M. Pai, and K. Abhishek, “Remodeling of the antegonial angle region in the human mandible: a panoramic radiographic cross-sectional study,” *Med Oral Patol Oral Cir Bucal*, vol. 15, no. 5, pp. e802-e807, 2010.
- [11] Ü. Tozoğlu and B. Çakur, “Evaluation of the morphological changes in the mandible for dentate and totally edentate elderly population using cone-beam computed tomography,” *Surg. Radiol. Anat.*, vol. 36, no. 7, pp. 643-649, 2014.
- [12] S. Geary, F. Selvi, S.-K. Chuang, and M. August, “Identifying dental panoramic radiograph features for the screening of low bone mass in postmenopausal women,” *Int J Oral Maxillofac Surg*, vol. 44, no. 3, pp. 395-399, 2015.
- [13] D. Ledgerton, K. Horner, H. Devlin, and H. Worthington, “Radiomorphometric indices of the mandible in a British female population,” *Dentomaxillofac Radiol*, vol. 28, no. 3, pp. 173-181, 1999.
- [14] P. Govindraju and P. Chandra, “Radiomorphometric indices of the mandible—an indicator of osteoporosis,” *J Clin Diagn Res*, vol. 8, no. 3, p. 195, 2014.
- [15] E. Klemetti, S. Kolmakov, and H. Kröger, “Pantomography in assessment of the osteoporosis risk group,” *Eur. J. Oral Sci.*, vol. 102, no. 1, pp. 68-72, 1994.
- [16] J.-K. Joo, Y.-J. Lim, H.-B. Kwon, and S.-J. Ahn, “Panoramic radiographic evaluation of the mandibular morphological changes in elderly dentate and edentulous subjects,” *Acta Odontol. Scand.*, vol. 71, no. 2, pp. 357-362, 2013.
- [17] N. Yanıkoğlu and B. Yılmaz, “Radiological evaluation of changes in the gonial angle after teeth extraction and wearing of dentures: a 3-year longitudinal study,” *Oral Surg Oral Med Oral Pathol Oral Radiol Endod*, vol. 105, no. 6, pp. e55-e60, 2008.
- [18] S. Huuonen et al., “Influence of edentulousness on gonial angle, ramus and condylar height,” *J. Oral Rehabil.*, vol. 37, no. 1, pp. 34-38, 2010.
- [19] B. Bahija et al., “Mandibular morphological variations in partially edentulous adult patients: An orthopantomographic study,” *Int. j. med. health res.*, vol. 8, no. 11, pp. 67-74, 2019.
- [20] D. H. Enlow, H. J. Bianco, and S. Eklund, “The remodeling of the edentulous mandible,” *J Prosthet Dent*, vol. 36, no. 6, pp. 685-693, 1976.
- [21] S.-M. Fouda, M. M. Gad, M. El Tantawi, J. I. Virtanen, K. Sipila, and A. Raustia, “Influence of tooth loss on mandibular morphology: A cone-beam computed tomography study,” *J. Clin. Exp. Dent.*, vol. 11, no. 9, p. e814, 2019.
- [22] R. Bhuyan, S. Mohanty, S. K. Bhuyan, A. Pati, S. Priyadarshini, and P. Das, “Panoramic radiograph

- as a forensic aid in age and gender estimation: Preliminary retrospective study,” *J Oral Maxillofac Pathol*, vol. 22, no. 2, p. 266, 2018.
- [23] J. Subtelny, “The degenerative, regenerative mandibular condyle: facial asymmetry,” *J. craniofac. genet. dev. biol., Suppl.*, vol. 1, pp. 227-237, 1985.
- [24] V. Sairam, G. R. Potturi, B. Praveen, and G. Vikas, “Assessment of effect of age, gender, and dentoalveolar changes on mandibular morphology: A digital panoramic study,” *Contemp. Clin. Dent.*, vol. 9, no. 1, p. 49, 2018.
- [25] N. Taleb and M. Beshlawy, “Mandibular ramus and gonial angle measurements as predictors of sex and age in an Egyptian population sample: A digital panoramic study,” *J Forensic Res*, vol. 6, no. 5, pp. 1-7, 2015.
- [26] G. Ceylan, N. Yanikoglu, A. B. Yilmaz, and Y. Ceylan, “Changes in the mandibular angle in the dentulous and edentulous states,” *J Prosthet Dent*, vol. 80, no. 6, pp. 680-684, 1998.
- [27] V. Dutra, H. Devlin, C. Susin, J. Yang, K. Horner, and A. R. C. Fernandes, “Mandibular morphological changes in low bone mass edentulous females: evaluation of panoramic radiographs,” *Oral Surg Oral Med Oral Pathol Oral Radiol Endod*, vol. 102, no. 5, pp. 663-668, 2006.
- [28] M. Uma, R. Shetty, and K. K. Shenoy, “Cephalometric: evaluation of influence of edentulousness on mandibular morphology: a comparative study,” *J. Indian Prosthodont. Soc.*, vol. 13, no. 3, pp. 269-273, 2013.
- [29] P. Lönberg and K. M. Lindskog, “Changes in the size of the lower jaw on account of age and loss of teeth,” *Acta genet. stat. med.*, vol. 2, pp. 1-90, 1951.
- [30] V. Krishnan, L. Sreela, P. Mathew, and T. S. Prasad, “Radiographic evaluation of remodeling of mandible in adult South Indian population: Implications in forensic science,” *J. Forensic Dent. Sci.*, vol. 11, no. 3, p. 137, 2019.
- [31] R. H. Chole, R. N. Patil, S. Balsaraf Chole, S. Gondivkar, A. R. Gadgail, and M. B. Yuwanati, “Association of mandible anatomy with age, gender, and dental status: a radiographic study,” *int. sch. res. notices*, vol. 2013, 2013.
- [32] H.-P. Chang, Z. Kinoshita, and T. Kawamoto, “A study of the growth changes in facial configuration,” *Eur J Orthod.*, vol. 15, no. 6, pp. 493-501, 1993.
- [33] O. Bulut, N. Freudenstein, B. Hekimoglu, and S. Gurcan, “Dilemma of Gonial Angle in Sex Determination: Sexually Dimorphic or Not?,” *Am J Forensic Med Path*, vol. 40, no. 4, pp. 361-365, 2019.
- [34] P. H. Shah, R. Venkatesh, C. B. More, and V. Vaishnavee, “Age-and sex-related mandibular dimensional changes: A radiomorphometric analysis on panoramic radiographs,” *Indian J Dent Res*, vol. 31, no. 1, p. 113, 2020.
- [35] N. G. Pecora, T. Baccetti, and J. A. McNamara Jr, “The aging craniofacial complex: a longitudinal cephalometric study from late adolescence to late adulthood,” *Am J Orthod Dentofacial Orthop*, vol. 134, no. 4, pp. 496-505, 2008.
- [36] M. Ashkenazi, L. Taubman, and A. Gavish, “Age-Associated Changes of the Mandibular Foramen Position in Anteroposterior Dimension and of the Mandibular Angle in Dry Human Mandibles,” *Anat Rec (Hoboken)*, vol. 294, no. 8, pp. 1319-1325, 2011.
- [37] S. Osato, I. Kuroyama, S. Nakajima, T. Ogawa, and K. Misaki, “Differences in 5 anatomic parameters of mandibular body morphology by gonial angle size in dentulous Japanese subjects,” *Ann. Anat. ANN ANAT*, vol. 194, no. 5, pp. 446-451, 2012.
- [38] H. A. C. S. D. M. J. d. u. e. H. T. B. V. M. P. S. W. C. M. B. V.-M. P. B. R. M. T. M. N. Michael Newman Anne B Goodpaster Bret H, “Longitudinal study of muscle strength, quality, and adipose tissue infiltration,” *Am. J. Clin. Nutr.*, vol. 90, no. 6, pp. 1579-1585, 2009.
- [39] G. Akay, Z. Akarslan, O. Karadag, and K. Gungor, “Does tooth loss in the mandibular posterior region have an effect on the mental index and panoramic mandibular index?,” *Eur Oral Res*, vol. 53, no. 2, p. 56, 2019.
- [40] G. Bozdog and S. Sener, “The evaluation of MCI, MI, PMI and GT on both genders with different age and dental status,” *Dentomaxillofac Radiol*, vol. 44, no. 9, p. 20140435, 2015.
- [41] E. Hastar, H. H. Yilmaz, and H. Orhan, “Evaluation of mental index, mandibular cortical index and panoramic mandibular index on dental panoramic radiographs in the elderly,” *Eur. J. Dent.*, vol. 5, no. 1, p. 60, 2011.

- [42] P. van der Stelt, "Panoramic radiographs in dental diagnostics," *Ned Tijdschr Tandheelkd.*, vol. 123, no. 4, pp. 181-187, 2016.

Please cite this paper as:

Mosavat F, Sinanoglu A, Khodadadi Z, Sadeghi Sabzevari Z. Evaluation of six radiomorphometric indices. *J Craniomax Res* 2023; 10(1): 9-17