



## Ridge split considerations for the horizontally deficient alveolar ridges according to a new classification for the alveolar ridge width

Amin Yamani <sup>1</sup>, Ata Garajei <sup>2\*</sup>, Azadeh Emami <sup>3</sup>, Shiva Adelinia <sup>4</sup>

1. Oral and Maxillofacial Surgeon, Private Practice, Tehran, Iran.

2. Department of Oral and Maxillofacial Surgery, School of Dentistry and Department of Head and Neck Surgical Oncology and Reconstructive Surgery, The Cancer Institute, School of Medicine, Tehran University of Medical Sciences, Tehran, Iran .

3. Department of Anesthesiology, Iran University of Medical Sciences, Tehran, Iran.

4. Dentist, Private Practice, Isfahan, Iran.

### ARTICLE INFO

#### Article Type: Original Article

Received: 30 May 2016

Revised: 4 Jul 2016

Accepted: 16 Aug 2016

#### \*Corresponding author:

Ata Garajei  
The Cancer Institute, Imam Hospital Complex,  
Keshavarz Blvd., Tehran, Iran.

Tel: +98-21-66581544

Fax: +98-21-66428655

Email: atagarajei@tums.ac.ir

### ABSTRACT

**Introduction:** Among many techniques advocated for the horizontally deficient alveolar ridges, ridge split technique has many advantages.

**Materials and Methods:** Here, the main treatment management strategy of the horizontally collapsed ridges, the ridge split approach, is discussed in detail according to our new ridge width classification, with the goal of assisting an operator in choosing the proper bone augmentation technique.

**Results:** Success rate was more than 97 percent with using our protocol in treatment of cases in this study.

**Conclusion:** Choice of the technique is dependent ultimately on operator experience and surgical comfort. The ridge split has many advantages, including lack of donor site morbidity and graft stability over time.

**Key words:** Ridge-split, Alveolar ridge.

### Introduction

With tooth loss, the alveolar bone undergoes an irreversible and progressive process known as resorption, ensuring an unfavorable loss of bone width and height. As a result the ideal three dimensional (3D) implant placement may be compromised. Different bone augmentation techniques are employed to increase the residual ridge height and width so that the implant can be placed in the ideal three dimensional (3D) and restoratively driven position. It has been shown that although bone collapse after tooth loss is usually three dimensional (3D), horizontal deficiency or width loss develops to a larger extent [1-2].

Alveolar width deficiency can represent loss of buccal (la-

bial), cortical, medullary bone or both. Deficiency of the buccal cortex (cortical plate) after tooth extraction can present significant difficulty in implant reconstruction [3-4]. The buccal cortical plate with a thickness of 2 mm next to an implant appears to have a higher risk of subsequent resorption [5]. A variety of implant driven bone augmentation techniques for the deficient alveolar bone have been proposed [6-8]. Four of these techniques are frequently performed [1] guided bone regeneration (GBR)/particulate bone grafting [9,10], [2]. Onlay block bone grafting with intraoral source such as chin, ramus, posterior mandible, zygomatic buttress and maxillary tuberosity [11-13], [3] ridge split/bone grafting procedure [14-16] and [4] alveolar distraction osteogenesis [17-19].

Most of these techniques are designed to improve horizontal bone loss before or simultaneously with dental implant placement. This article categorizes ridge split/bone graft treatment augmentation techniques for horizontally deficient alveolar ridges according to our new classification for the alveolar ridge width.

## Material and Methods

Assessment of the alveolar ridge before initiation of the treatment plan is important to establish a proper diagnosis. Initial clinical evaluation supported by radiographic images helps to distinguish two dimensional (2D) versus three dimensional (3D) alveolar bone deficiencies. Alveolar bone should be assessed clinically for a rough width and height analysis and inter arch occlusal relationships. Alveolar width can be measured with different calipers on top of the thin mucosa or by ridge mapping through it. Panoramic (2D) images are often sufficient. In some implant cases a three dimensional (3D) or volumetric bone evaluation with cone beam computerized tomography (CBCT) is needed.

Classification of the alveolar ridges:

Bone resorption is one of the most important consequences that occurs following tooth loss. After tooth loss, tensile and compressive forces on the alveolar ridge are eliminated and this cause alveolar ridge resorption. The alveolar ridge undergoes accelerated bone loss within the first year of tooth extraction. Resorption of mandibular bone occurs at a faster and greater extent than maxillary bone. Posterior mandibular alveolar ridge resorbs four times faster than that of the anterior mandibular alveolar ridge.

In 1988, Cawood and Howell [20] suggested an anatomic classification of the edentulous jaws for pre-prosthetic surgery. It proposed six classes and detailed the changes that the edentulous alveolar process in the anterior and posterior maxilla and mandible undergo after teeth extraction (the pattern of resorption). In 1989, Jensen [21] proposed an implant driven site classification by bone quality and quantity and proximity to vital structures. In 2002, Wang and Al-Shammari [22] described a practical (therapeutically oriented) classification of alveolar ridge defects, that is, horizontal, vertical, and combination defects, proposing the edentulous ridge expansion approach (ridge-split) for the horizontal and combination defects of the alveolar ridge.

Here we present a classification based on the remaining height and width of the alveolar bone (according to cone beam computerized tomography (CBCT) measurements), hard tissue intervention technique and the different types of implants that can be utilized. In class A (Abundant bone) alveolar bone is favorable (width>6mm, height>13mm). No intervention is needed. Root form implants are suggested.

In Class B (Barely sufficient): remaining alveolar bone has 2.5 to 5 mm width and more than 13 mm height. In these cases bone has atrophied mildly to moderately. A variety of interventions can be employed such as: reducing 2mm of residual alveolar bone height (osteotomy), increasing alveolar bone width with interpositional grafts, block bone grafts, GBR, alveolar ridge splitting technique, or utilizing mini or blade implants. Osteotomy and osteoplasty can be used in class I & class II of the Kennedy classification. It is important to evaluate bone density carefully before osteotomy. By reducing cortical bone primary stability of implants will be questionable.

Using mini implants is another option for treating these kinds of cases. Although the surgery process is simple; horizontal and vertical forces on mini implants are more destructive. Aesthetics and hygiene are compromised, too. Sometimes for a molar tooth substitution of two mini implants are needed, so the cost to the patient is higher.

If the remaining bone width is between 2.5 to 4 mm onlay bone grafts can be used. Grafts can be harvested from an intra-oral source (chin, retro-molar region, coronoid process and tuberosity) or an extra-oral source (hip, skull, ribs). Requiring a second site for graft harvest, donor site morbidity and lengthening of treatment procedure are problems that can occur with this method. When the remaining alveolar ridge is narrow, blade implants are helpful. Cavity preparation for blade implants is different. Prognosis of these types of implants is poor and failure probability is high. GBR is another way to treat these kinds of alveolar ridges. Autologous or autogenous bone grafts with membrane are used to cover implants surfaces. Stability of implants and grafts is crucial.

Class C (compromised bone): This group is more common on mandibular and posterior maxillary alveolar ridges. Implanting is a routine treatment in these regions.

a) C<sub>h</sub>: If alveolar bone height is less than 10 mm it is

called “C<sub>h</sub>”. “C<sub>h</sub>” is more common on the posterior maxillary alveolar ridge because of pneumatization.

b) C<sub>w</sub> : If alveolar bone width is less than 2.5 mm but height is sufficient it is called “C<sub>w</sub>”.

In “C<sub>w</sub>” cases treatment options are: converting “C<sub>w</sub>” to “C<sub>h</sub>” type by osteoplasty, or using onlay grafts. For “C<sub>h</sub>” type alveolar ridges subperiosteal implants, ridge augmentation techniques, ramus frame implants and transosteal implants can be utilized. Class D (Deficient bone): alveolar process resorbs completely and basal bone atrophies too. Muscular and facial deformity occurs. Before any treatment basal bone height and width reconstruction is required (Chart 1).

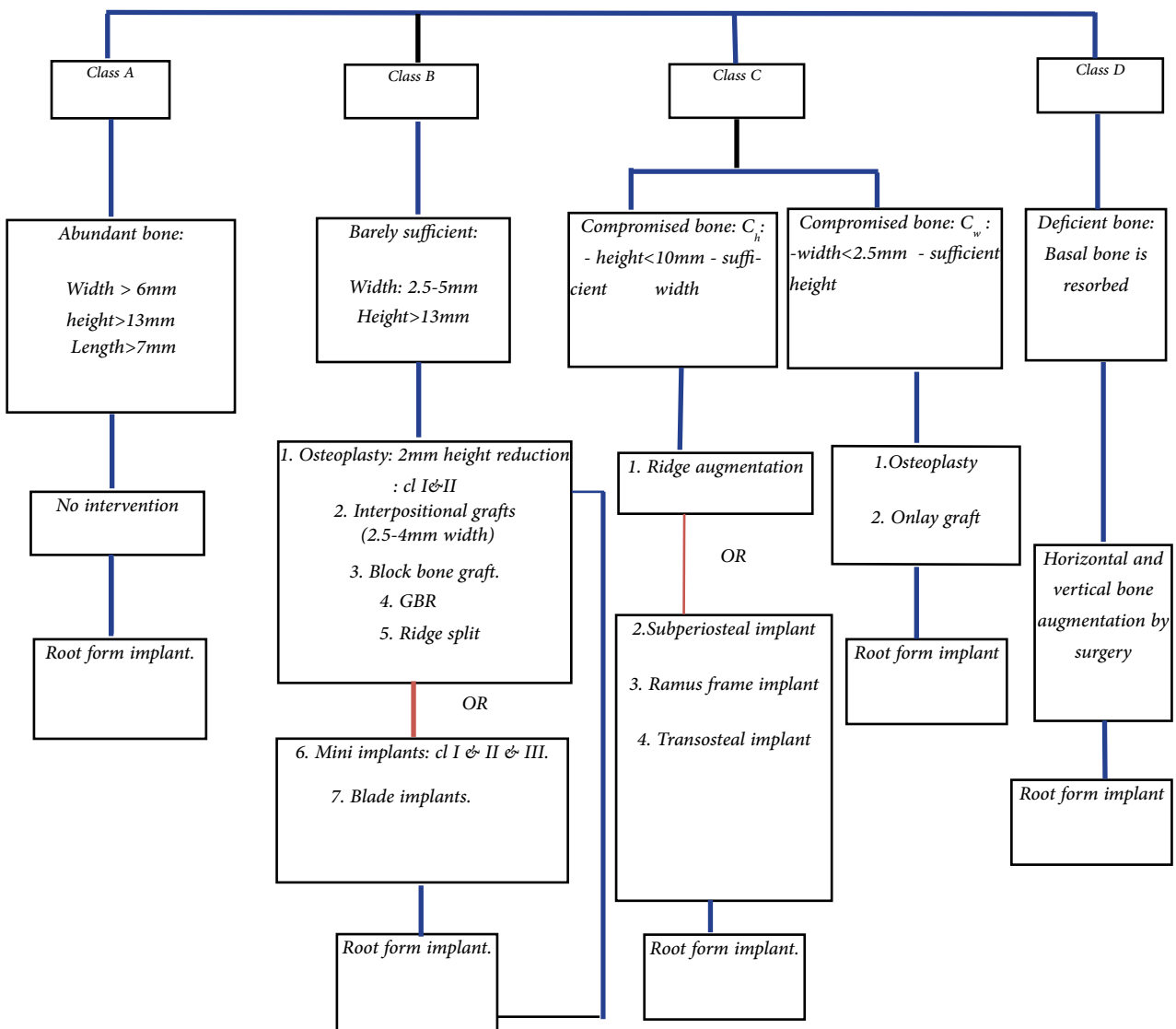
**Alveolar ridge splitting technique (ASRT):**

This technique is the most effective way to treat narrow ridges. ASRT seems to be a well-functioning one-stage alternative to extended two stage horizontal grafting procedure.

**This technique follows two goals:**

1. Increasing alveolar bone’s width and inserting implants simultaneously.
2. Improving implant’s position.

In this technique bone cuts and different bone expander instruments are employed to increase the deficient alveolar ridge’s width. Our experience shows that performing ASRT technique depends on the alveolar ridge’s form and shape; each form of alveolar ridge calls for a special corticotomy technique. To perform ASRT, bone cuts can be placed anywhere but in the authors’ opinion each form of alveolar ridge calls for a specific corticotomy technique. Here we tried to put each alveolar ridge’s form and its specific corticotomy technique in a category. This category is provided for the treatment of alveolar ridges with a mean width of 2.5 to 4 mm and more than 13 mm height by ASRT.



### New categorization for type B alveolar ridges:

In this new categorization, type B alveolar ridges (as it discussed above) can be divide into four groups (in apico-coronally portion) (Fig 1 and 2).

**Class I:** Alveolar ridge is in a pyramidal shape. The coronal segment is narrower than apical segment. This type of alveolar ridges occasionally forms after primary bone resorption.

**Class II:** In this group a coronal segment of the alveolar ridge resorbs more than the apical segment. This type of alveolar ridge is usually the result of traumatic extractions; especially when the buccal plate has been damaged during extraction. .

**Class III:** Resorption process affects both the apical and coronal segments equally. The alveolar ridge is in a U shape; it has adequate height but insufficient width ( $B_w$ ).

**Class IV:** The apical segment resorbs more than the coronal segment because of a pre-extraction periapical lesion. ASRT can't be employed for these types of alveolar ridges.

In the horizontal portion, the remaining alveolar bone is classified into four groups (Fig 3).

**Class A:** Edentulous alveolar bone is symmetrical.

**Class B:** Bone resorption in the mid-buccal region of edentulous area is greater than other sites.

**Class C:** Buccal cortical bone has resorbed more beside the adjacent tooth.

**Class D:** Resorption of buccal and lingual surfaces of the alveolar bone is distinct. This type usually occurs when alveolar bone was unable to grow because of a missing tooth (Fig 4).

## Surgical Phase

After reviewing the patient's medical and dental history; the attached gingiva's width, clinical and radiographical characteristic of the alveolar ridge, interarch space and occlusion should be assessed.

**1. Flap design:** before the performance of a mucoperiosteal flap the attached gingiva's width should be evaluated. If the attached gingiva's width is more than 3mm, a flap should be performed on the middle of the crestal bone. If the attached gingiva has less than 3 mm width, a 1.5-2 mm segment of attached gingiva should be pre-

served on the buccal surface of the alveolar bone. A papillary preservation flap is suggested. A releasing incision is not common, but if it is necessary to perform, it should be originated 1mm away from the adjacent tooth and continued 5mm beyond the adjacent tooth's apical region. The Buccal flap is reflected by a periosteal elevator (Fig 5).

**2. Ridge flattening:** after flap reflection, remnant collagen fibers should be removed from the alveolar bone surface. For alveolar ridges with a width of more than 2.5 mm, smoothing of the alveolar bone is sufficient. If the alveolar ridge is less than 2.5 mm in width, the height should be reduced till 2.5 mm width is established (Fig 6).

**3. Corticotomy:** after flattening of the alveolar bone, cortical bone cuts are performed based on the alveolar ridge type in a horizontal portion.

**Class A:** A U corticotomy technique is performed. In this technique the two vertical lines of U should be 2 mm away from the mesial and distal tooth's CEJ. The horizontal line of U should be placed on the middle of those alveolar ridges with 2.5 mm width. If the alveolar ridge has a width of more than 3 mm, this line should be placed 1.5 mm away from the buccal edge of the alveolar remaining bone.

The vertical cuts and the implant's fixture should have the same height. The horizontal cut's depth depends on the alveolar ridge's form in the apico-coronally aspect. For example the horizontal line's depth should be 2mm beyond the green stick fracture of the buccal cortex (Fig 7 and 8).

**Class B:** A T shape corticotomy technique may be employed for the class B alveolar ridges. Vertical bone cut is performed on the middle of the alveolar bone's buccal depression. Just like the U corticotomy technique, the horizontal line of T splits the alveolar bone equally, if the alveolar bone has 2.5mm width. If the alveolar bone's width is more than 3mm, it's better to perform the horizontal cut 1.5mm away from the buccal edge of the alveolar bone. This cut should be 3mm away from the CEJ of adjacent teeth. Fixture's height determines the vertical bone's cut height and the horizontal bone's cut depth (Fig 9).

**Class C:** An L shape corticotomy technique should be employed for the class C alveolar ridges. The vertical bone cut is performed on the middle of the alveolar

bone's buccal depression a distance of 2 mm away from the adjoining teeth. The horizontal line's depth should be 2 mm beyond the normal bone. The fixture's height determines the vertical bone's cut height and the horizontal bone's cut depth (Fig 10).

The vertical cut's depth is the common point in all three techniques. In all three types of osteotomy, the vertical cut's depth should be beyond the horizontal line in total depth. Burs, disks, piezosurgery and laser may be utilized to perform cortical bone cuts. Using each instrument has its own limitations. Depth of bone cuts that are performed by disks are insufficient and this makes bone expansion difficult. The swinging motions of the saw may harm an adjacent tooth's structure. Using a laser also requires special skills and knowledge. Piezosurgery is beneficial for performing corticotomy before bone expansion. Fine swinging motions and different angled heads has made this process easier and less harmful for adjacent anatomical structures (Fig 11).

**4. Bone expansion:** bone cuts may be connected together by a long shank chamfer bur. It's important to connect all the bone cuts together before performing the bone expansion. Osteotomes, motor-driven bone expanders and a crest control system (horizontal distractor) can be administered to expand bone. Maxillary bone expansion is much easier when using osteotomes because of cancellous bone. Mandibular bone has more cortical bone than the maxilla, so using osteotomes can increase the risk of buccal cortical bone fracture. Utilizing motor driven bone expanders and distractors is more reliable and accurate for both maxillary and mandibular alveolar bone.

Motor driven expanders involves using a set of non cutting edge screws in different diameters. A drilling sequence should be followed through the horizontal bone cut. The bone expanders are driven by an implant's handpiece, and are used at speeds of 30 rpm to 40 rpm. The torque settings on the surgical motor should remain around 40 Ncm. The instruments may be inserted in intervals, pausing to allow time for the bone to expand.

Horizontal distractors can be used for distraction of the alveolar ridges with more than 3.5 mm width. They consist of two vertical plates which expands the buccal and lingual segments by opening a screw. There should be approximately 1.5 mm space between the buccal and lingual segments to place the distractor device. As the distractor distracts deeper sites of the horizontal

line, the buccal cortical bone's width increases and also increases the resistance against distraction and the risk of cortical bone fracture (Fig 12).

In the maxillary bone, the fracture line is usually seen on the medial surface of the buccal cortical bone. In the mandible, because of high density of cortical bone, the fracture usually starts from the lateral surface of the buccal segment. Hence, mandibular bone distraction should be done gently and wisely (Fig 13). For expanding edentulous long span alveolar ridges, each implant's site should be assessed and treated separately.

Strip splitting technique is an alternative to treat long span edentulous alveolar ridges. In this technique, each implant's site should be assessed and treated (prepared) separately. There must be a minimum of 10 mm interval between vertical bone cuts. There is no need to expand all the edentulous areas equally (Fig14).

**5. Drilling:** after using bone expanders, the depth of the horizontal corticotomy line should be drilled because bone has been expanded in a depth less than the fixture's height. Taper fixtures should be used after drilling. Straight fixtures increase the risk of buccal cortical bone fracture. In D3 and D4 categories of bone density, implant insertion is easy. D2 category of bone density requires more drilling because D2 type of bone density expands less than the D3 type. Special considerations should be taken while drilling because of the risk of cortical bone fracture (Fig 15).

**6. Implant insertion:** fixtures are driven by an electric handpiece used at speeds of 30 rpm. The torque settings on the surgical motor should be adjusted to 40 Ncm (Fig 16).

**7. Fixation:** Many surgeons believe the buccal segment should be fixed after implant insertion. The fact is the buccal segment fixation depends on surgeon's clinical judgment. If the buccal segment has expanded too much or has split away fixation is necessary (Fig 17).

**8. Bone grafting:** the displacement of the fractured segments may be closely monitored as long as adequate implant stability is achieved, the fracture site may be grafted and implant placement may be accomplished with a single stage approach. Before grafting it's better to smoothen the bone surface with a bur. Resorb able membranes can be used to cover the buccal segment and bone grafting materials (Fig 18).

**9. Suturing:** suturing is necessary for completion of the procedure. After the resorbable membrane is placed,

the flap deflects on the membrane. Incision edges are brought together by mattress sutures completed by single sutures (Fig 19).

In this case series study, we used above protocol. We had 12 patients in group A and 18 patients in group B and 14 patients in group C. Total number of inserted implants were 131. The follow up period was 2 years from the final loading day.

### Results

We had only one implant failure in each group. Success rate was more than 97 percent.

### Discussion

A literature showed few similarities and many differences between autogenous intraoral monocortical block graft and ridge split bone graft techniques. Both procedures require a skilled surgical practitioner. Both techniques are used mainly for a 2D horizontal alveolar ridge augmentation. Autogenous block bone grafting demonstrates high osteogenic potential and effective in severe anterior alveolar atrophy in maxilla and mandible [23–25]. Two main disadvantages of monocortical block grafts are donor site morbidity and late term graft resorption [26]. The monocortical block bone resorption has been reported to have up to 5% early bone loss and up to 40% late bone loss of the entire graft volume due to remodeling and inadequate consolidation [27]. Differences between the ridge split procedure and autogenous intraoral monocortical block bone grafting are including these items: donor and recipient site morbidity, type of wound closure, buccal flap integrity and vascularity, specifics of wound healing, type of bone interface, and possibility of an immediate implant placement [28].

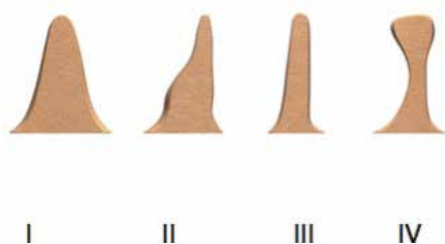


Fig 1.




Fig 2.




Fig 3.

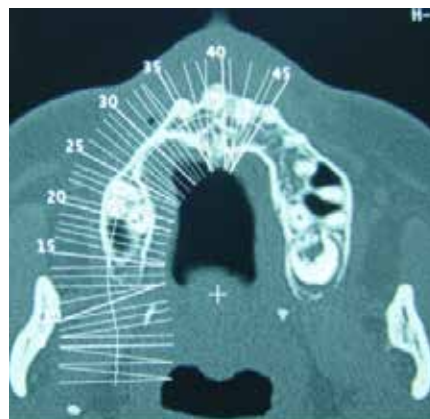


Fig 4.

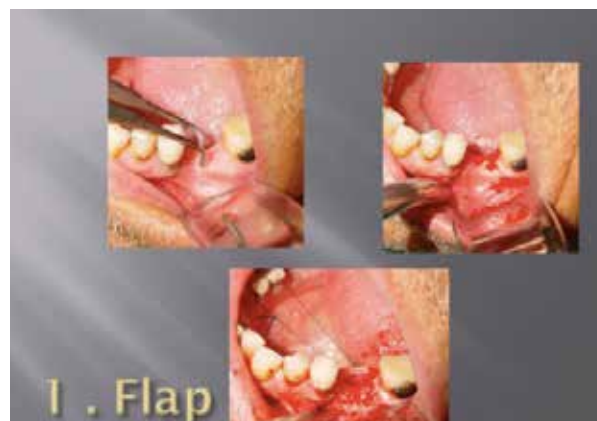

Fig 5.

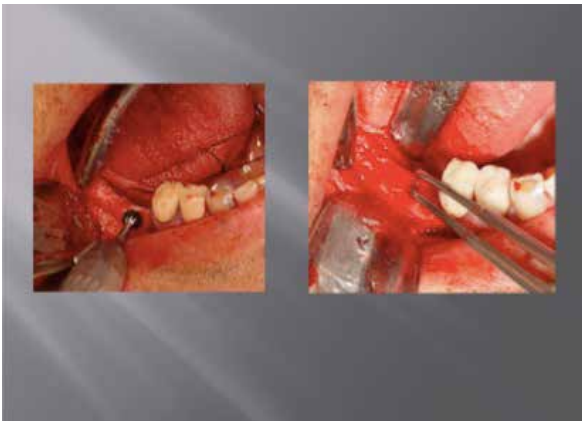

Fig 6.

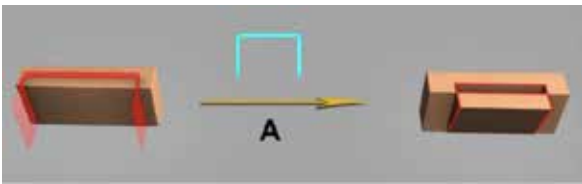


Fig 7.

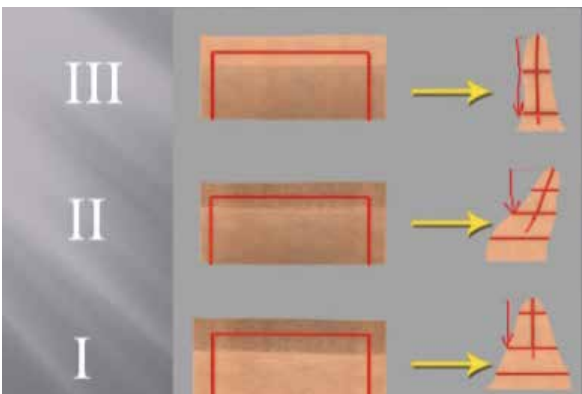


Fig 8.




Fig 9.




Fig 10.

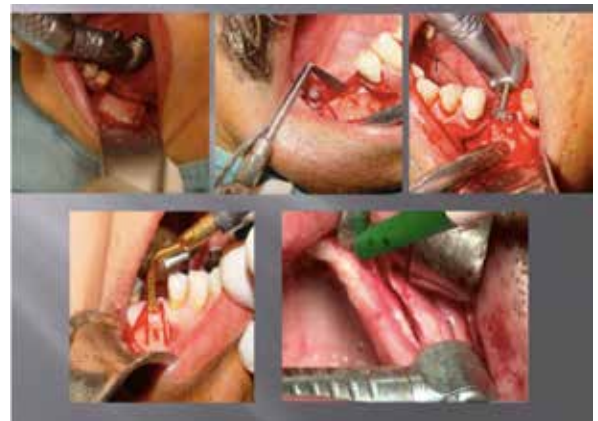

Fig 11.

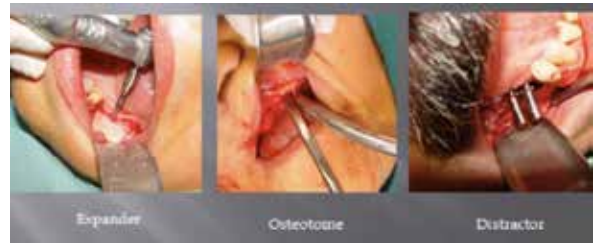

Fig 12.

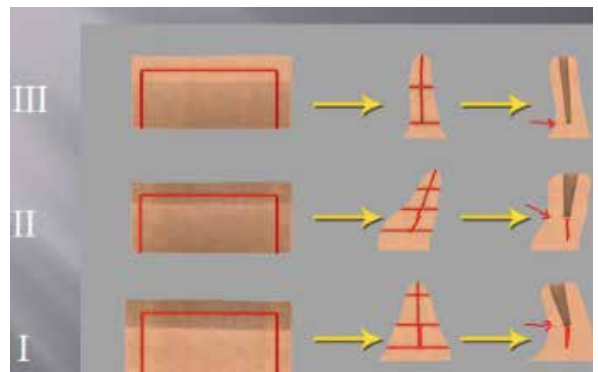


Fig 13.

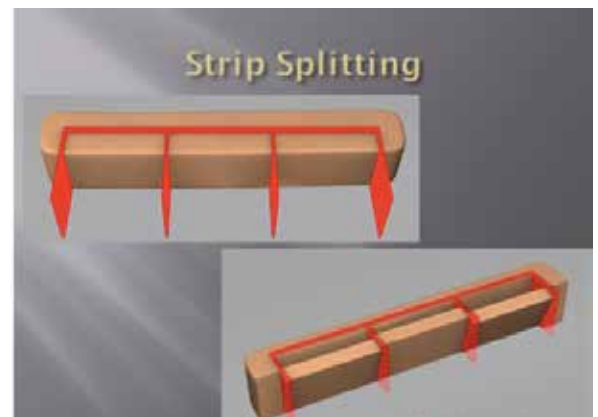


Fig 14.

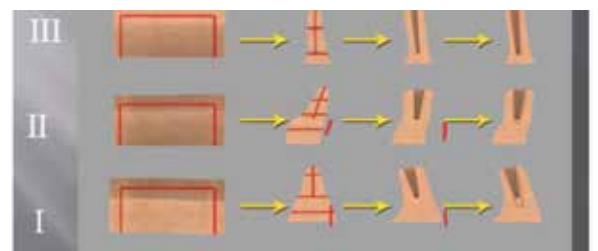


Fig 15.

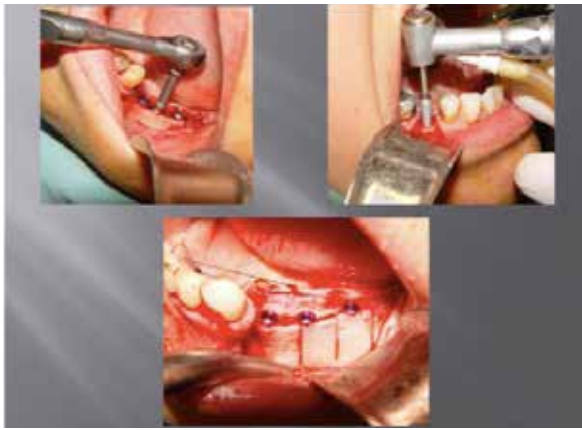

Fig 16.

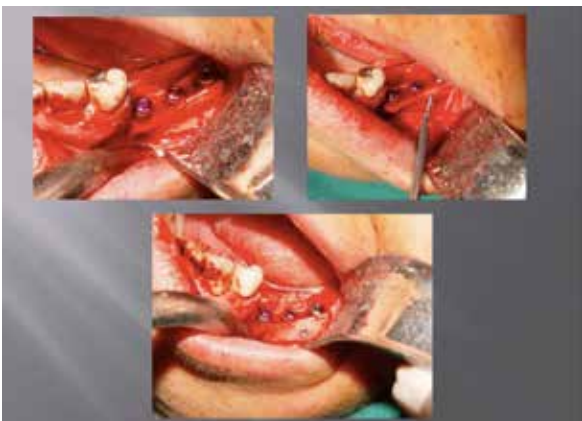

Fig 17.

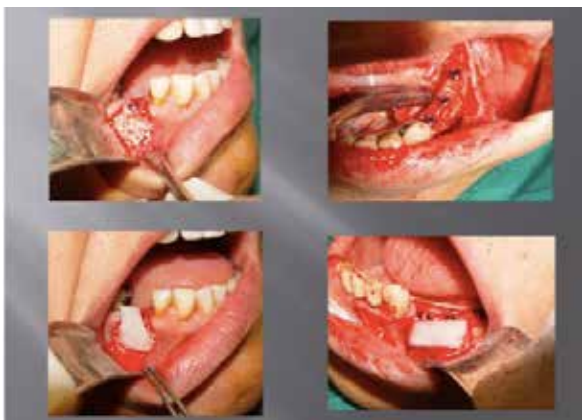

Fig 18.

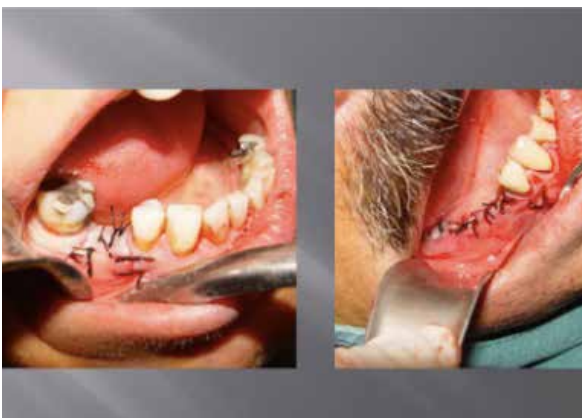

Fig 19.

## Conclusion

Understanding of the 3D bone anatomy with CBCT scan help us achieve a proper diagnosis before initiation of implant treatment. Our recommended ridge width classification for the horizontally deficient alveolar ridges has been proposed to aid in choosing an appropriate surgical modality for the specific collapsed alveolar ridge (class B). Choice of the technique is dependent ultimately on operator experience and surgical comfort. The ridge split has many advantages, including lack of donor site morbidity and graft stability over time.

## Conflict of Interest

The authors declare no conflict of interest.

## References

- [1] Botticelli D, Berglundh T, Lindhe J. Hard tissue alterations following immediate implant placement in extraction sites. *J Clin Periodontol.* 2004;31:820–828.
- [2] Schropp L, Wenzel A, Kostopoulos L, Karring T. Bone healing and soft tissue contour changes following single tooth extraction: a clinical and radiographic 12-month prosthetic study. *Int J Periodont Restor Dent.* 2003;23:313–323.
- [3] Araujo M, Lindhe J. Dimensional ridge alterations following tooth extraction. An experimental study in the dog. *J Clin Periodontol.* 2005;32:212–218.
- [4] Cardaropoli G, Araujo M, Lindhe J. Dynamics of bone tissue formation in tooth extraction sites. An experimental study in dogs. *J Clin Periodontol.* 2003;30:809–818.
- [5] Qahash M, Susin C, Polimeni G, Hall J, Wikesjo UM. Bone healing dynamics at buccalperi-implant sites. *Clin Oral Implants Res.* 2008;19:166–172.
- [6] McAllister BS, Haghghat K. Bone augmentation techniques. *J Periodontol.* 2007;78:377–396.
- [7] Chiapasco M, Zaniboni M, Boisco M. Augmentation procedures for the rehabilitation of deficient edentulous ridges with oral implants. *Clin Oral Implants Res.* 2006;1(suppl 2):136–159.



- [8] Aghaloo TL, Moy PK. Which hard tissue augmentation techniques are the most successful in furnishing bony support for implant placement? *Int J Oral Maxillofac Implants*. 2007;22(suppl): 49–70.
- [9] Annibaldi S, Bignozzi I, Sammartino G, La Monaca G, Cristalli MP. Horizontal and vertical ridge augmentation in localized alveolar deficient sites: a retrospective case series. *Implant Dent*. 2012;21: 175–185.
- [10] Buser D, Bragger U, Lang NP, Nyman S. Regeneration and enlargement of jaw bone using guided tissue regeneration. *Clin Oral Implants Res*. 1990;1:22–32.
- [11] Tolstunov L. Maxillary tuberosity block bone graft: innovative technique and case report. *J Oral Maxillofac Surg*. 2009;67:1723–1729.
- [12] Bedrossian E, Tawfilis A, Alijanian A. Veneer grafting: a technique for augmentation of the resorbed alveolus prior to implant placement. A clinical report. *Int J Oral Maxillofac Implants*. 2000;15:853–858.
- [13] Pikos MA. Mandibular block autografts for alveolar ridge augmentation. *Atlas Oral Maxillofac Clin North Am*. 2005;13:91–107.
- [14] Jensen OT, Cullum DR, Baer D. Marginal bone stability using 3 different flap approaches for alveolar split expansion for dental implants: a 1-year clinical study. *J Oral Maxillofac Surg*. 2009; 67:1921–1930.
- [15] Simion M, Baldoni M, Zaffe D. Jawbone enlargement using immediate implant placement associated with a split-crest technique and guided tissue regeneration. *Int J Periodontics Restorative Dent*. 1992;12:462–473.
- [16] Scipioni A, Bruschi GB, Calesini G. The edentulous ridge expansion technique: a five-year study. *Int J Periodontics Restor Dent*. 1994;14:451–459.
- [17] Laster Z, Reem Y, Nagler R. Horizontal alveolar ridge distraction in an edentulous patient. *J Oral Maxillofac Surg*. 2011;69: 502–506.
- [18] Mc Carthy JG. The role of distraction osteogenesis in the reconstruction of the mandible in unilateral craniofacial microsomia. *Clin Plast Surg*. 1994;21:625–631.
- [19] Chin M, Toth BA. Distraction osteogenesis in maxillofacial surgery using internal devices: review of five cases. *J Oral Maxillofac Surg*. 1996;54:45–53.
- [20] Cawood JI, Howell RA. A classification of the edentulous jaws. *Int J Oral Maxillofac Surg*. 1988;17:232–236.
- [21] Jensen O. Site classification for the osseointegrated implant. *J Prosthet Dent*. 1989;61:228–234.
- [22] Wang HL, Al-Shammari K. HVC ridge deficiency classification: a therapeutic oriented classification. *Int J Periodontics Restor Dent*. 2002;22:335–343.
- [23] Adeyemo WL, Reuther T, Bloch W, et al. Influence of host periosteum and recipient bed perforation on the healing of onlay mandibular bone graft: an experimental pilot study in the sheep. *Oral Maxillofac Surg*. 2008;12:19–28.
- [24] Barone A, Covani U. Maxillary alveolar ridge reconstruction with nonvascularized autogenous block bone: clinical results. *J Oral Maxillofac Surg*. 2007; 65:2039–2046.
- [25] Cordaro L, Amade DS, Cordaro M. Clinical results of alveolar ridge augmentation with mandibular block bone graft in partially edentulous patients prior to implant placement. *Clin Oral Implants Res*. 2002;13:103–111.
- [26] Casap N, Brand M, Mogyros R, et al. Island osteoperiosteal flaps with interpositional bone grafting in rabbit tibia: preliminary study for development of new bone augmentation technique. *J Oral Maxillofac Surg*. 2011;69:3045–3051.
- [27] Romero-Olid Mde N, Vallencillo-Capilla M. A pilot study in the development of indices for predicting the clinical outcomes of oral bone grafts. *Int J Oral Maxillofac Implants*. 2005;20:595–604.
- [28] Tolstunov L. Classification of the Alveolar Ridge Width: Implant-Driven Treatment Considerations for the Horizontally Deficient Alveolar Ridges. *J Oral Implanol*. 2014;40: 36570-.

*Please cite this paper as:*

Yamani A, Garajei A, Emami A, Adelinia Sh; Ridge split considerations for the horizontally deficient alveolar ridges according to a new classification for the alveolar ridge width. *J Craniomax Res* 2016; 3(4): 248-257