



## Early loading implant failure of congenitally missing maxillary lateral incisor after orthodontic space opening: A case report

Faezeh Atri <sup>1\*</sup>, Simindokht Zarati <sup>2</sup>

1. Department of Dental Prosthesis Technology, Dentistry Faculty, Tehran University of Medical Sciences, Tehran, Iran.

2. Department of Prosthodontics, Dentistry Faculty, Tehran University of Medical Sciences, Tehran, Iran.

### ARTICLE INFO

#### Article Type: Case Report

Received: 26 Oct 2016

Revised: 29 Nov 2016

Accepted: 5 Dec 2016

#### \*Corresponding author:

Faezeh Atri

MSc, DDS, Assistant Professor, Department of Dental Prosthesis Technology, Dentistry Faculty, Tehran University of Medical Sciences, Tehran, Iran.

Tel: +98-21-88364666

Fax: +98-21-88364666

Email: F-atr@sina.tums.ac.ir

### ABSTRACT

This report describes the case of a 25-year-old female patient who initially was undergone of canine distalization and orthodontic space opening for replacement of congenitally missing lateral incisors. Then she received dental implants each side and after the healing period, cement retained prostheses was fabricated and delivered. Despite the fact that all the factors seemed fine, the right lateral implant failed after four months of cementation.

Dental implant failure, especially in prosthetic phase, is a challenging issue in prosthodontics and it is important to find out the etiologies and associated factors. This case report discusses the probable reasons of early loading failure of cement retained implant restoration.

**Key words:** Implant failure; lateral incisors missing; orthodontic space opening; osseointegration.

## Introduction

Dental implant failure is a challenging issue and it is important to know its etiologies. Implant failures occur in two main phases: Surgical (healing failure) and Prosthetic (early loading, intermediate, late and long term failure) [1]. Early failure happens within first 18 months of loading, while the implant seems to be rigid and stable with no radiographic and clinical pathology [2].

In this report, a case of congenitally missing maxillary lateral incisor is presented which received orthodontic space opening and dental implant treatments. After 4 months of prosthesis delivery, early loading failure of implant restoration occurred. Its probable causes are dis-

cussed.

## Clinical Report

A 25 years old female with clear medical history was referred with demand of replacing maxillary lateral incisors. She was undergone orthodontic treatment for canine distalization and space opening in last 1.5 years. According to the cone beam CT scans measurements 6mm mesiodistally space and enough alveolar length was available each side, and there were about 5 and 4.6 mm buccolingually alveolar crest weight at the left and right side, respectively.

She had received endosseus implants (XiVE® S plus Screw Implant, D 3.0/L 13) each side and after five months second stage surgery was done (Fig 1).

In first prosthetic examination, the gingiva of right lateral incisor was more incisally and labial vestibular concavity was obvious (Fig2). The patient was referred to do gingival aligning surgery for the more esthetical result. After gingival healing, the cement retained restorations were fabricated. Occlusion adjustment (light contact in centric relation and no contact in excursion movement) was done. The abutments were screwed with 20 N torque and crowns were cemented with temporary cement (TempBond®, Kerr). The patient was followed up after one week, then referred to remove orthodontic brackets. The one month follow up revealed patient's satisfaction with no problem (Fig 3).

After four months, the patient returned with complaining of mobility of right lateral implant restoration. On examination, the crown was not uncemented. The gingiva was pink, with normal texture and there was no pain, exudate and swelling. The mobility was in horizontal direction, neither vertical nor rotational direction. The radiographic evaluation showed normal levels of bone with no pathology, but a little cement was remained in mesial margin of the crown (Fig 4). The most probable cause was seemed to be abutment screw loosening. Therefore, we decided to remove the crown and retighten the abutment screw. While trying to remove the crown, suddenly crown and fixture removed together with little bleeding. Unfortunately, the implant was failed and explantation was done (Fig 5).

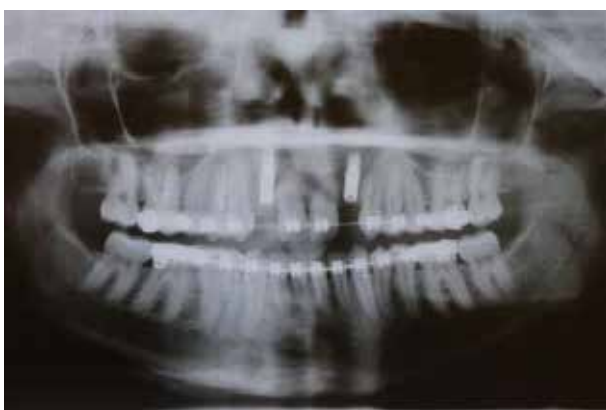

Figure 1. Post implant insertion panoramic view.

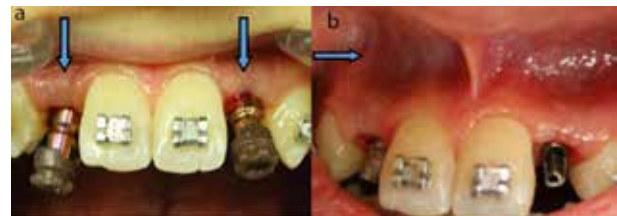


Figure 2. a) Unaligned gingiva of right lateral implant. b) Deep labial vestibular concavity.

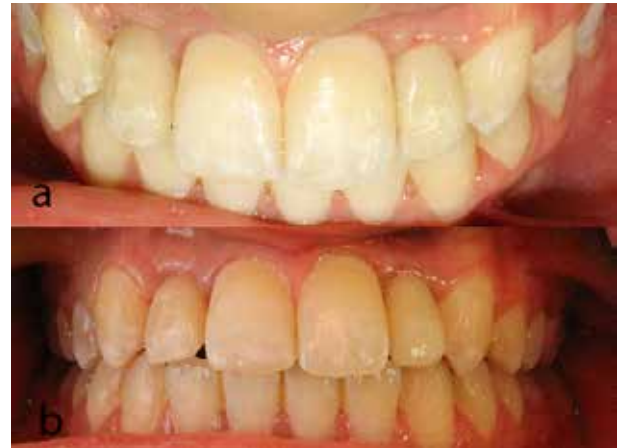

Figure 3. Delivered restorations after 1 months



Figure 4. Radiographic periapical view of right lateral implant (remained excess cement).

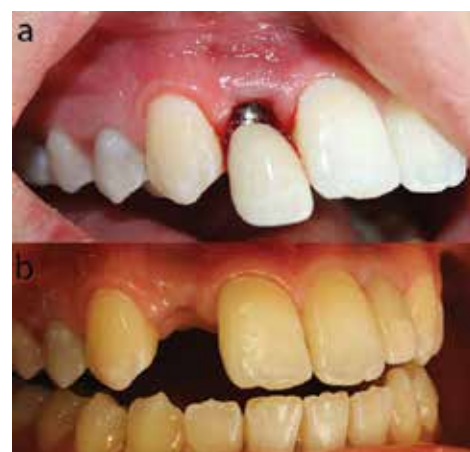

Figure 5. a) Crown and fixture removing together. b) After 4 days of explantation.

## Discussion

Implant failure is the lack of osseointegration which is defined with symptomatic mobility, infection, bleeding and peri fixture radiolucency [3].

In this report a narrow implant was inserted in the anterior region of maxilla, where the space gained by orthodontic treatment. Implant failure occurred in the first months of loading and the single sign was little mobility without radiographic evidence. Mobility is the key sign of implant failure, which could be vertical, horizontal or rotational. Rotational mobility is due to an immature bone/implant interface, but horizontal and vertical mobility may reflect bone loss and the presence of soft tissue capsule. Mobility could be without radiographic changes [3]. In this case, horizontal mobility was indicated the osseointegration failure and fibrous encapsulation.

As the failure happened in the first months of loading, its probable reason is related to biomechanical factors of the implant-bone interface; amount of force applied to the prosthesis and the density and quantity of the bone around implant [2]. In this case, the amount of force had been controlled through exact occlusal adjustment with light contact in centric relation and no contact in excursion movement. So quality and quantity of adjacent bone should be reassessed.

In this patient, orthodontic treatment of space opening was performed. Chang et al. reported in orthodontic treatments, density of bone in the location of force is decreased significantly [4]. Hsu et al. demonstrated that the new bone induced by the application of orthodontic forces has lower mineral contents and density than older bone [5]. Also, Hounsfield unit reduction of alveolar bone after orthodontic force application is approved [6].

The other limitation of the orthodontic space opening is local difficulties. Uribe et al. showed the decrease of alveolar weight and increase of labial concavity occur in orthodontic space opening for maxillary lateral incisor agenesis [7]. Furthermore, mesiodistal space less than 7mm, crest thickness less than 5mm and presence of vestibular concavity are considered as local implant risk factors [8], which existed in this patient and had been reduced the quantity of bone surrounding implant. In these similar cases, bone grafting is suggested to achieve proper implant side.

It is recommended to verify implant osseointegration

before starting of prosthetic procedure. There are some methods available to check osseointegration: percussion test, insertion torque measuring, reverse torque testing, Periotest, Ostell [9]. Stable implants which fail such these tests are fibrous encapsulated, therefore are not recommended for prosthetic loading. In this patient, this step was missed.

In some recent reports, excess cement residue is considered as a reason of implant failure, because the gingival fiber tissue around the implant does not provide enough protection [10]. However, it is not proved yet that the presence of excess cement surrounding an implant may be a triggering factor for failure, in a study of Burbano et al. Peri-implant disease was associated with five commercially available dental cements [11]. In this patient, a small cement residue was remained so it could be lead to start an inflammation and destroy the integration.

## Conclusion

It is important to recognize the implant failure causes by respecting the three steps:

- 1) Evaluation of bone quantity and quality before implant insertion is necessary and bone graft is strongly recommended in defect sides.
- 2) Verification of implant stability and osseointegration before starting the prosthetic procedure is essential.
- 3) Caution and tact should be utilized to limit dentist related complications such as loading control and removing of excess cement.

## References

- [1] Jividen G, Misch CE. Reverse torque testing and early loading failures—help or hindrance. *J Oral Implantol.* 2000;26:82-90.
- [2] Misch CE. *Dental implant prosthetics.* 2nd ed. St Louis, Elsevier Mosby; 2015:165-8.
- [3] Sakka S, Coulthard P. Implant failure: etiology and complications. *Med Oral Patol Oral Cir Bucal.* 2011;16:42-4.
- [4] Chang HW, Huang HL, Yu JH, Hsu JT, Li YF, Wu YF. Effects of orthodontic tooth movement on alveolar bone density. *Clin Oral Invest.* 2012;16:679-88.

- [5] Hsu JT, Chang HW, Huang HL, Yu JH, Li YF, Tu MG. Bone density changes around teeth during orthodontic treatment. *Clin Oral Invest*. 2011;15:511-9.
- [6] Jiang F, Liu SS, Xia Z, Li S, Chen J, Kula KS, et al. Hounsfield unit change in root and alveolar bone during canine retraction. *Am J Orthod Dentofacial Orthop*. 2015;147:445-53.
- [7] Uribe F, Padala S, Allareddy V, Nanda R. Cone-beam computed tomography evaluation of alveolar ridge width and height changes after orthodontic space opening in patients with congenitally missing maxillary lateral incisors. *Am J Orthod Dentofac Orthoped*. 2013;144:848-59.
- [8] Renouard F, Rangert B. Risk factors in implant dentistry: Simplified clinical analysis for predictable Treatment. 2nd ed. Quintessence International; 2008.
- [9] Mistry G, Shetty O, Shetty S, Singh RD. Measuring implant stability: A review of different methods. *Journal of Dental Implants*. 2014;4:165-9.
- [10] Gapski R, Neugeboren N, Pomeranz AZ, Reissner MW. Endosseous Implant Failure Influenced by Crown cementation; a clinical case report. *Int J Oral Maxillofac Implants*. 2008;23:943-6.
- [11] Burbano M, Wilson TG Jr, Valderrama P, Blansett J, Wadhvani CP, Choudhary PK, et al. Characterization of Cement Particles Found in Peri-implantitis-Affected Human Biopsy Specimens. *Int J Oral Maxillofac Implants*. 2015;30:1168-73.

*Please cite this paper as:*

Atri F, Zarati S; Early loading implant failure of congenitally missing maxillary lateral incisor after orthodontic space opening: A case report. *J Craniomax Res* 2017; 4(1):324-327