



## Osteomyelitis of mandible in a patient with polyarteritis nodosa: a case report

Reza Sharifi <sup>a</sup>, Amirsalar Sayedyahosseini<sup>b\*</sup>

<sup>a</sup> Department of Oral and Maxillofacial Surgery, Dental School, and Craniomaxillofacial Research Center, Shariati Hospital, Tehran University of Medical Sciences, Tehran, Iran; <sup>b</sup> Craniomaxillofacial Research Center, Shariati Hospital, Tehran University of Medical Sciences, Tehran, Iran.

ARTICLE INFO	ABSTRACT
<p><i>Article Type:</i> <b>Case Report</b></p> <p><i>Received:</i> 2 Mar 2014 <i>Revised:</i> 23 Mar 2014 <i>Accepted:</i> 30 Mar 2014</p> <p><i>*Corresponding author:</i> Amirsalar Sayedyahosseini Department of Oral and Maxillofacial Surgery, Craniomaxillofacial Research Center, Shariati Hospital, Tehran University of Medical Sciences, Tehran, Iran</p> <p><i>Tel:</i> +982184902473 <i>Fax:</i> +982184902473 <i>Email:</i> amirsalar.sayedyahosseini@gmail.com</p>	<p>Polyarteritis nodosa (PAN) is a necrotizing vasculitis characterized by damage to blood vessels and subsequent ischemic tissue changes in various organs. The case presented here is a 51-year-old man with PAN, who has recently developed osteomyelitis of mandible. To the best of our knowledge, this is the first report of jaw osteomyelitis in patients with PAN.</p> <p><b>Keywords:</b> Polyarteritis nodosa, Osteomyelitis, Vasculitis.</p>

### Introduction

The term "vasculitis" describes a diverse group of inflammatory disorders characterized by damage to the blood vessels [1]. The vessel lumen is usually compromised, and this is associated with ischemia of the tissues supplied by the involved vessels. Most subtypes of vasculitis are mediated by immunopathogenic mechanisms that occur in response to certain antigenic stimuli [2].

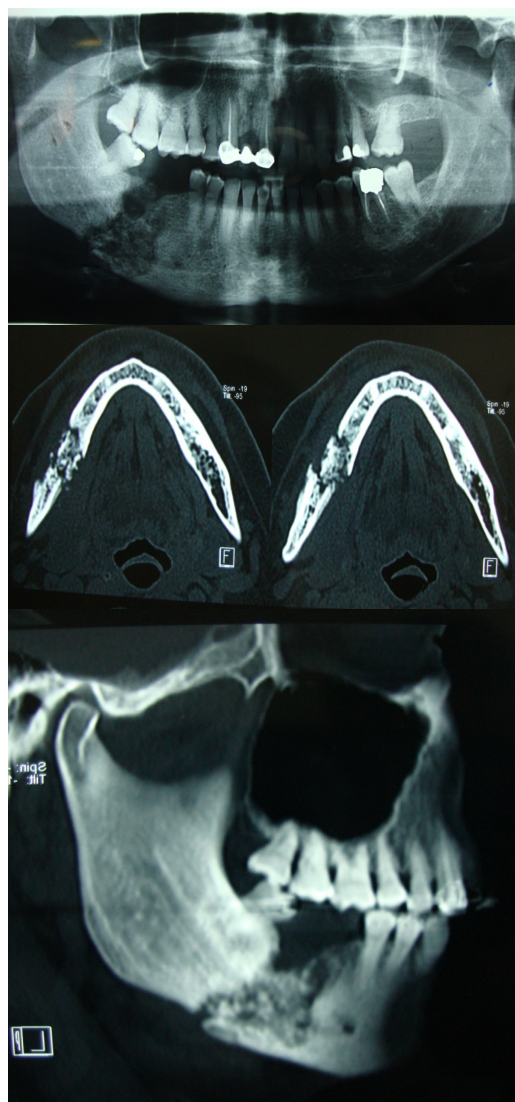
Polyarteritis nodosa (PAN) is a kind of necrotizing vasculitis that involves small and medium-sized vessels, specifically arteries. It has a predilection for involving the skin, peripheral nerves, mesenteric vessels, heart, and brain. There has been reports of PAN involving temporal bone and causing hearing loss but this finding was not due to bony changes [3].

Common signs and symptoms of PAN

include pain in the extremities, abdominal pain, mononeuritis multiplex, arthralgia, myalgia, hypertension, and anemia [4]. There is no diagnostic serologic test for PAN. The treatment of PAN includes corticosteroids in high doses as well as immunosuppressive agents, especially Cyclophosphamide.

### Case report

A 51-year-old man was referred to our department complaining of jaw pain and inability to chew because of pain and malocclusion. Clinical examination revealed an intraoral fistula with purulent discharge in the right buccal vestibule of the mandibular arch. The right mandibular first and second molars were absent, and the right mandibular third molar had such a significant premature contact with the opposing teeth that it prevented all other teeth from occluding together. There was a mild extraoral swelling



**Figure 1.** Panoramic (A), axial CT (B), and sagittal view (C) of the involved bone.

in the right buccal space with no fistula. The right side of the lower lip and chin were completely numb. There was no history of trauma to the mandible.

Four months previously, the patient had noticed a progressive loosening and mobility of the right mandibular second molar as well as progressive numbness of the lip and chin. In the ensuing weeks, the second molar had spontaneously exfoliated and malocclusion developed.

A review of past medical history revealed that the patient has been a recognized case of PAN first diagnosed 6 years ago. The disease first involved lower extremities resulting in paresthesia and necrotic ulcers of digits. The treatment began with daily oral Prednisolone and Azathioprine. One year later, the disease involved the right eye, resulting in complete

visual loss in the inferior part of the visual field. Two years after that, the patient suffered the involvement of abdominal viscera. During the subsequent years, the disease progressed and caused mononeuritis multiplex, arthralgia, myalgia, hypertension, and renal disorders. At the time of admission to our department, the patient was under combination therapy with Prednisolone and Cyclophosphamide.

Computed tomography (CT) and panoramic radiography of the mandible showed a lytic bone lesion with associated pathological fracture in the right side (Figure 1). An incisional biopsy revealed osteomyelitis. Microscopically, the lesion consisted predominantly of necrotic bone showing loss of osteocytes from their lacunae, bacterial colonization, and an acute inflammatory infiltrate consisting primarily of polymorphonuclear leukocytes. Laboratory findings showed reduced levels of red blood cells, hemoglobin and hematocrit, as well as leukocytosis and elevated ESR. C-reactive protein was within normal range.

After several days of antibiotic therapy (Clindamycin 600 mg/IV/q.i.d) the lesion was totally resected through an intraoral approach under general anesthesia. All necrotic bone was removed down to apparently healthy bleeding bone, and a reconstruction plate was used to stabilize the mandible.

## Discussion

We performed a comprehensive search in PubMed and found that there was no previous report of jaw osteomyelitis in the PAN or other subtypes of systemic vasculitis. The used keywords for the search included polyarteritis nodosa, vasculitis, and osteomyelitis.

In this patient, osteomyelitis of mandible could be attributed to either underlying vascular disorder, long-term use of immunosuppressive agents, or both [5]. When we first visited the patient, the right second mandibular molar had been already exfoliated and we had no evidence to determine whether the tooth had any periapical or periodontal infection before spontaneous exfoliation. Therefore, it could not be determined whether an active odontogenic infection triggered the development of osteomyelitis in this immunocompromised patient or a vascular compromise and inadequate blood supply led to the development of bone necrosis. Osteomyelitis of mandible has been reported rising from pericoronitis of the third molar,

supporting the issue that odontogenic infection can cause osteomyelitis even in a patient with no history of any background illness [6].

The case presented here raises two important questions: Is it plausible to consider mandible as a target of systemic vasculitis? Is it safe to extract teeth in patients with PAN?

### **Acknowledgements**

This work was supported by Craniomaxillofacial Research Center, Tehran University of Medical Sciences, Tehran, Iran.

**Conflict of Interest:** *The authors declared no conflicts of interest.*

### **References**

- [1] Kallenberg CG. The last classification of vasculitis. *Clin Rev Allergy Immunol.* 2008 Oct; 35(1-2):5-10.
- [2] Langford CA. Vasculitis. *J Allergy Clin Immunol.* 2010 Feb; 125(2 Suppl 2):S216-25.
- [3] Joglekar S. Polyarteritis nodosa: a human

temporal bone study. *Am J Otolaryngol.* 2010 Jul-Aug;31(4):221-5. Epub 2009 May 17.

- [4] Henegar C, Pagnoux C, Puéchal X, Zucker JD, Bar-Hen A, Le Guern V, et al; French Vasculitis Study Group. A paradigm of diagnostic criteria for polyarteritis nodosa: analysis of a series of 949 patients with vasculitides. *Arthritis Rheum.* 2008 May; 58(5):1528-38.
- [5] Hovi L, Saarinen UM, Donner U, Lindqvist C. Opportunistic osteomyelitis in the jaws of children on immunosuppressive chemotherapy. *J Pediatr Hematol Oncol.* 1996 Feb;18(1):90-4.
- [6] Mohammed-Ali RI, Collyer J, Garg M. Osteomyelitis of the mandible secondary to pericoronitis of an impacted third molar. *Dent Update.* 2010 Mar;37(2):106-8.

*Please cite this paper as:*

Sharifi R, Sayedyahosseini A. Osteomyelitis of Mandible in a Patient with Polyarteritis Nodosa: a case report. *J Craniomaxillofac Res* 2014;1(3-4): 63-65