



A report of ameloblastic fibro-odontoma in the 29 month old girl: A case report

Hasan Mirmohamad Sadeghi¹, Masoume Fayazi Boroujeni², Behnaz Poorian^{3*}

1. Department of Oral and Maxillofacial Surgery, Shahid Beheshti University of Medical Sciences, Tehran, Iran.

2. Department of Oral and Maxillofacial Pathology, Shahrekord University of Medical Sciences, Shahrekord, Iran.

3. Department of Oral and Maxillofacial Pathology, Lorestan University of Medical Sciences, Lorestan, Iran.

ARTICLE INFO

Article Type: Case Report

Received: 23 Mar. 2018

Revised: 28 Apr. 2018

Accepted: 10 May. 2018

*Corresponding author:

Behnaz Poorian

Department of Oral and Maxillofacial Pathology,
Lorestan University of Medical Sciences, Lorestan,
Iran.

Tel: +98-66-33207826

Fax: +98-66-33215005

Email: behnazpoorian@gmail.com

ABSTRACT

Ameloblastic fibro-odontoma (AFO) is an uncommon benign mixed odontogenic tumor. AFO presents as a painless swelling in the posterior of mandible or maxilla that radiographically shows a well-defined radiolucent area containing various amounts of radiopaque deposits. Most cases occur before 20 years of age, with the average age of diagnoses being 9 years. This case report describes AFO affecting anterior mandible in the 29 month old girl. The lesion was surgically excised, and no recurrence was observed on 2 month follow-up.

Keywords: Ameloblastic fibro-odontoma, Odontogenic tumours, Benign jaws lesions.

Introduction

Ameloblastic Fibro-Odontome (AFO) is an uncommon benign tumor of the jaw that belong to mixed odontogenic category [1]. It histologically presents as a lesion similar to the ameloblastic fibroma and fibrodentinoma, but showing further inductive changes that lead to the formation of enamel matrix in addition to the dentin (dentinoid) [2]. It can be also indistinguishable from an immature complex odontoma. Therelative arrangement of the soft tissues and the stage of development of the involved tooth are useful criteria for diagnosis [3].

This lesion clinically presented as a well circumscribed, painless, slow growing swelling that can cause failure of tooth eruption, without predilection for gender (although according to Buchner's study [1] was significantly more common in male) and occur with equal frequency in the mandible or maxilla, although it tends to favor the posterior areas. Most cases occur in the mean age ranging from 8 to 11 years-old but cases as young as 9 months-old have been reported [4-10].

Case Report

Clinical history

A 29 month-old girl was referred to department of oral and maxillofacial surgery, Shahid Beheshti university of medical science in March 2015 with chief complaint of a swelling on her chin that had begun 5 month earlier noticed by her parents. Her medical history was unremarkable. She had healthy parents and there was no history of systemic disease in his family. His mother didn't mention any history of trauma.

Clinical examination revealed hard painless swelling in the anterior mandible (Fig. 1). There was no difficulty with feeding, fever and pruritus in this period and was otherwise healthy. Intraoral examination revealed both lingual and more buccal cortical expansion of the anterior mandible with absent of primary centrals and first molars. The primary left lateral incisor was displaced distally. The oral mucosa was intact with a normal appearance. The vitality test of erupted teeth showed all of teeth are vital. The patient expressed no regional lymphadenopathy clinically.

The panoramic radiograph revealed a well-defined unilocular radiolucent lesion with scattered radiopaque foci, extended horizontally from the left first molar to the right first molar (Fig. 2a). CT images showed a well-circumscribed hypodence mass containing opacities in the anterior portion of the mandible, with anteroposterior and lateromedial expansion (Fig. 2b). According to these clinical and radiographic features, the differential diagnoses were found to be odontogenic tumor such as Complex odontoma, Ghost cell odontogenic tumor or Calcifying Odontogenic Cyst (COC), Adenomatoid Odontogenic Tumor (AOT), and Ameloblasti Fibro Odontoma (AFO).

Diagnosis & Management

Under general anesthesia the lesion was enucleated out and careful curettage of surgical cavity was performed. Owing to its fibrous nature adequate planes of dissection where found and the tumor easily separated from the bone and was delivered intact (Fig. 3). Permanent Central and lateral Tooth bud attached to the follicle around the lesion was removed but unerupted primary canines and first molar were preserved. The bone cavity underwent irrigation and primary closure of the oral mucosa without use of material in surgical cavity. The specimens fixed in formalin and submitted for histopathological assessment. The macroscopic findings included one piece of irregular, creamy -white, soft to bony tissue, totally measuring 6.5×3×2.5cm

and measuring of bony tissue is 6×2×2.1cm. The microscopic exam showed a mixed odontogenic tumor composed of narrow cord, small and large island of odontogenic epithelium in a loose primitive connective tissue resembling dental papilla. The calcifying elements consist of foci of enamel, dentin and tooth-like structures in close relationship to the epithelial structure were also seen (Fig. 4). A diagnosis of ameloblastic fibro-odontoma was rendered based on these microscopic findings. During the 24 month follow up period no sign of recurrence was detected and satisfied bone remodeling was performed (Fig. 5).

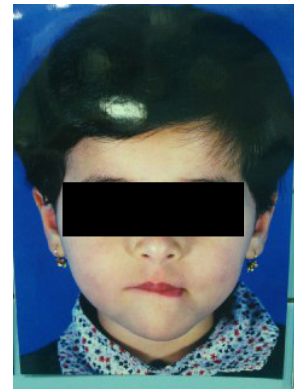

Fig. 1. A swelling in the anterior mandible.

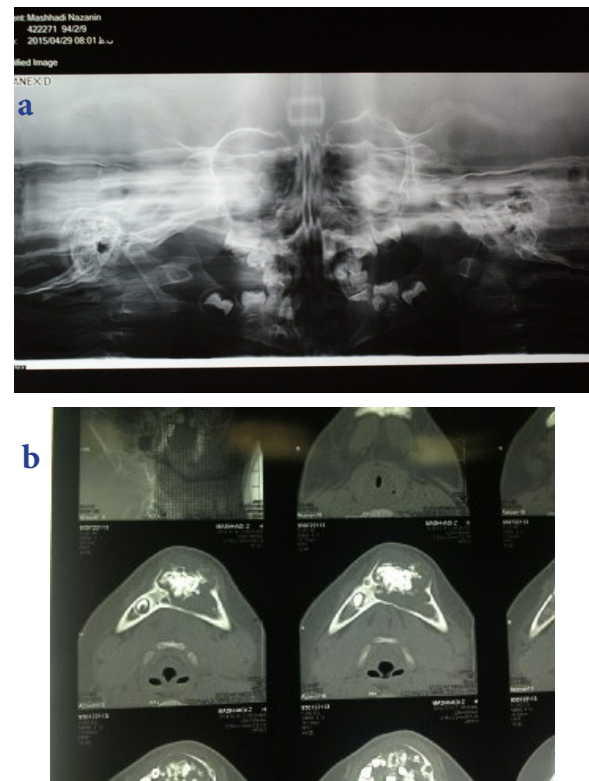


Fig. 2. The panoramic radiograph revealed a well-defined unilocular radiolucent lesion with scattered radiopaque foci, extended horizontally from the left first molar to the right first molar (a). Axial CT scan of the mandible indicated a hypodense lesion associated with calcified deposits inside the lesion (b).

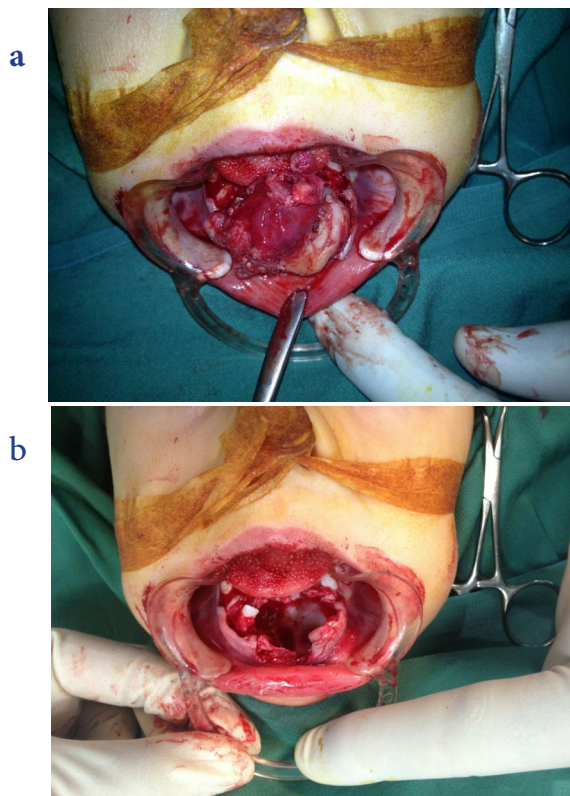


Fig. 3.

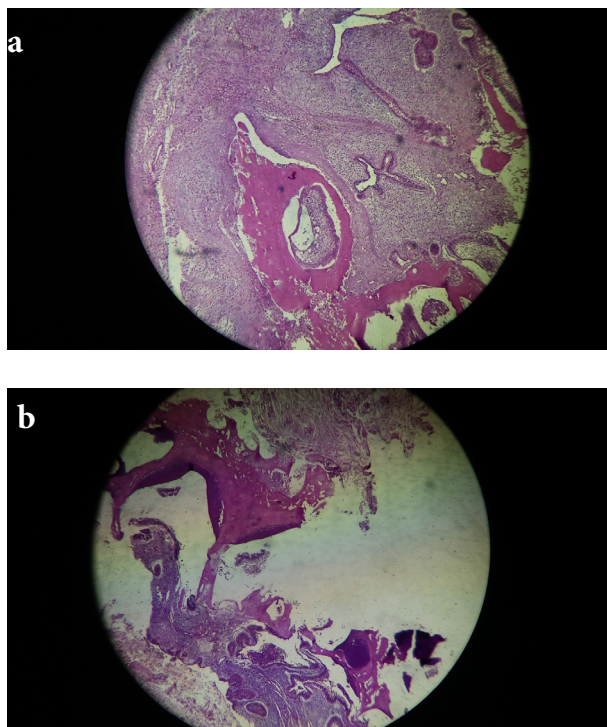


Fig. 4 a,b. Some narrow cords, small and large island of odontogenic epithelium in a loose primitive connective tissue. The calcifying element consist of foci of enamel, dentin and tooth-like structures in close relationship to the epithelial structure were also seen.

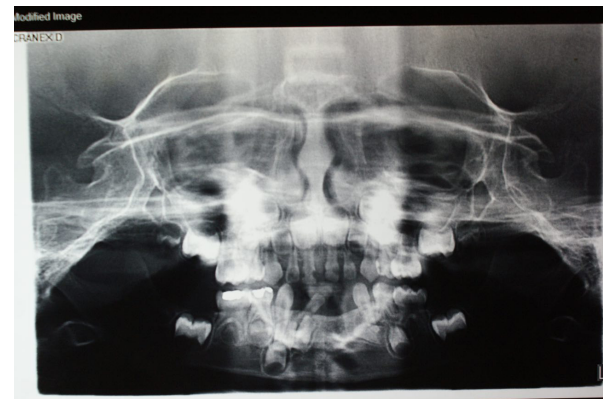

Fig. 5. The panoramic radiograph showed healing without recurrence of lesion.

Discussion

The differential diagnosis of a well-defined, mixed radiolucent-radiopaque lesion in the jaws of a child or adolescent includes odontoma, calcifying odontogenic cyst (COC), adenomatoid odontogenic tumor (AOT), and ameloblastic fibro-odontoma (AFO) [7,11,12]. Odontomas are the most common odontogenic tumor known as hamartoma, that are composed of the tissues native to teeth: enamel, dentin, cementum and pulp tissue. Odontomas, most are detected in the first two decades of life. There is no gender predilection. Clinical symptoms are uncommon, however, an affected patient may present failure eruption of a permanent tooth or multiple teeth [13].

Adenomatoid odontogenic tumor (AOT) is a benign odontogenic tumor, that are recognized as the second or fourth most common odontogenic tumor. Clinically, AOT usually presents as a slow-growing and asymptomatic tumor in the jaw bone. It is most commonly encountered in the 2nd decade of life, with higher incidence in the female and the anterior part of maxilla [14]. The calcifying odontogenic cyst (COC) is another developmental odontogenic cyst and its occurrence constitute about 0.3-0.8% of all odontogenic cysts, and 0.37% to 2.1% of all odontogenic tumor. Frequency of it's occurrence is equal in the maxilla and mandible, mainly in the anterior part of jaws, with no gender predilection. The peaking age of occurrence is the second decade of life. The most common clinical presentation of COC is as an asymptomatic slow growing swelling of jaws [15]. Ameloblastic fibro-odontoma is a uncommon (0.3 to 1.7 incidence among odontogenic tumor), benign tumor of children that it's average age at presentation is 6.3 years in males and 9.6 years in females, with female: male ratio of 1:1.62. These lesions are located in the posterior region of the jaw [17,18]. AFO is often referred as slow growing, asymp-

tomatic swelling and failure of tooth eruption [1,18], but an example of very rapid growth has been reported in a young child, following an incisional biopsy prior to definitive treatment [11]. Based on their radiological and clinical features, some of them are probably true neoplasm while others appear to be developing odontoma that exhibits a hamartous nature [1,19]. Radiological features of AFO included a cyst-like lesion with radiopaque areas resembling a developing odontoma. AFO is usually not aggressive but a few studies suggest that AFO can behave aggressively with multiple recurrences and rarely can undergo malignant transformation to ameloblastic fibrosarcoma. Therefore, it is important to continue the follow up of AFO lesion for several years [16]. The treatment of the AFO usually involves conservative enucleation and curettage. There is a controversy in the literature regarding extraction or retaining the associated tooth bud in the case of AFO. Majority of the articles state that the associated tooth bud has to be removed in order to avoid recurrence. Sporadic recurrences of AFO have been attributed to the inadequate surgical removal at the time of initial treatment [5,7,16]. In this case, we performed conservative and saved permanent canines, the 24 months follow up shows adequate surgical processes and there was not sign of recurrence [Fig. 4].

Conflict of Interest

There is no conflict of interest to declare.

References

- [1] Buchener A, Kaffe I, Vered M. Clinical and radiological profile of ameloblastic fibro-odontoma: an update on an uncommon odontogenic tumor based on a critical analysis of 114 cases, *Head and neck pathology* 2013; 7:54 -63.
- [2] Raichart P. A., Philipsen H. P., *Odontogenic tumors and allied lesions*, quintessence publication, 2004.
- [3] De Riu G., Meloni S., Contini M., Tullio A., Ameloblastic fibro-odontoma. Case report and review of the literature, *Journal of Cranio-Maxillo-Facial Surgery* (2010) 38, 141e144.
- [4] Oghli A.A., Scuto I., Ziegler C., Flechtenmacher C., Hofele C. A, large ameloblastic fibro-odontoma of the right mandible, *Med Oral Patol Oral Cir Bucal*. 2007; 12(1):E34-7.
- [5] Pontes HA, Pontes FS, Lameira AG, Salim RA, Carvalho PL, Guimaraes DM, Pinto DD Jr. Report of four cases of ameloblastic fibro-odontoma in mandible and discussion of the literature about the treatment. *J Craniomaxillofac Surg*. 2012; 40(2):e59-63.
- [6] De Riu G, Meloni SM, Contini M, Tullio A., Ameloblastic fibroodontoma. Case report and review of the literature, *J Craniomaxillofac Surg*. 2010; 38(2):141-4.
- [7] Surej Kumar LK, Manuel S, Kham SA, Venugopal K, Sivakumar TT, Issac J., Ameloblastic fibro-odontoma. *Int J Surg Case Rep*. 2014; 5:1142-4
- [8] Tsuji K, Yoshida H, Watanabe S, Yamamoto E, Yamada K, Tominaga K, et al. A case of ameloblastic fibro-odontoma accompanied with a number of impacted teeth. *Oral Maxillof Surg Med J*. 2015; 27(3):366-8.
- [9] Manor E., Kan E., Bodner L.. Case Report Ameloblastic Fibroodontoma of the Mandible with Normal Karyotype in a Pediatric Patient Case Reports in Dentistry Volume 2012, Article ID 969687, 4 pages doi:10.1155/2012/969687.
- [10] Santana Santos Th., Carvalho R.W.F., Avelar R.L., Silva E.D.O., Frota R., Anjos E.D., Ameloblastic Fibro-Odontoma in Children: Report of 2 Cases. *Journal of Dentistry for Children*-78:3, 2011,
- [11] Flaitz C.M., Hicks J., "Delayed tooth eruption associated with an ameloblastic fibro-odontoma," *Pediatric Dentistry*, vol. 23, no. 3, pp. 253-254, 2001.
- [12] Wewel J, Narayana N. Ameloblastic fibro-odontoma of the anterior mandible in a 22-month-old boy. *Indian J Dent Res*. 2010;21:618-20
- [13] Brenda L, Nelson, Lester D. R. Compound Odontoma. *Head Neck Pathol*. 2010 Dec; 4(4): 290-291.
- [14] Lang M.J. , Wang Y.P. , Lin H.P., Chen H.M., Kuo Y.Sh., Adenomatoid odontogenic tumord Report of a posterior mandibular case with the presence of ghost cells, *Journal of Dental Sciences* (2015) 10, 216e222.
- [15] Shivakumar B.N., Reddy S, Nayak B, Rathore N, Ghost cell odontogenic cyst: A rare case with literature review, *Asian Journal of Medical Sciences* | Jul-Aug 2015 | Vol 6 | Issue 4.

- [16] Kirjavainen A., Tuovinen V., Sándor G. K., Large ameloblastic fibro-odontoma in a 7-year-old girl with analysis of 108 cases. *An Maxillofac Surg.* 2016 Jan-Jun; 6(1): 15–20.
- [17] Sassi L.M., Stramandinoli R.T., Dissenha J. L., Zanferrari F. L., Schussel J. L., Large ameloblastic fibro-odontoma in a 3 year-old child: case report, *RSBO.* 2011 Jan-Mar; 8(1):114-6.
- [18] Ghalaut P., Wadhawan V., Kapoor P., Ameloblastic Fibro-Odontome: A case report with review of literature, *Indian Journal of Basic and Applied Medical Research*; September 2014: Vol.-3, Issue-4, P. 109- 112
- [19] Slootweg PJ. An analysis of the interrelationship of the mixed odontogenic tumorsameloblastic fibroma, ameloblastic fibro-odontoma, and the odontomas. *Oral Surg Oral Med Oral Pathol* 1981; 51(3):266-76.

Please cite this paper as:

Sadeghi H, Fayazi Boroujeni M, Poorian B; A report of ameloblastic fibro-odontoma in the 29 month old girl: A case report. *J Craniomaxillofac Res* 2018; 5(3): 131-135