



Prevalence and position of mandibular incisive canal, anterior loop of the mandibular canal and lingual foramen using cone beam computed tomography

Zahra Ghoncheh ^{1*}, Behrang Moghaddam Zadeh ², Sahar Shaeri ³

1. Department of Oral and Maxillofacial Radiology, School of Dentistry, International Campus, Tehran University of Medical Sciences, Tehran, Iran.

2. Department of Oral and Maxillofacial Radiologist, School of Dentistry, Tehran University of Medical Sciences, Tehran, Iran.

3. School of Dentistry, Tehran University of Medical Sciences, Tehran, Iran.

ARTICLE INFO

Article Type:
Original Article

Received: 9 May, 2019

Revised: 20 Jul, 2019

Accepted: 15 Sep, 2019

*Corresponding author:

Zahra Ghoncheh

Department of Oral and Maxillofacial Radiology,
School of Dentistry, International Campus, Tehran
University of Medical Sciences, Tehran, Iran.

Tel: +98-21-55851131

Fax: +98-21-55845529

Email: z-ghoncheh@Tums.ac.ir

ABSTRACT

Objective: Comprehensive knowledge about the anatomy of the surgical site is an important prerequisite for any surgical procedure. This study aimed to assess the prevalence, position and anatomical characteristics of mandibular incisive canal (MIC), lingual foramen (LF) and anterior loop of the mandibular canal (ALMC) in an Iranian population using cone beam computed tomography (CBCT).

Materials and Methods: This study was conducted on 103 patients who underwent CBCT prior to implant placement. The CBCT scans of patients were evaluated by two observers to determine the visibility and length of MIC, LF and ALMC. The buccolingual inclination of MIC at the initiation point of canal and canal path were also studied.

Results: The prevalence of MIC, LF and ALMC was 90%, 76% and 84% on CBCT scans, respectively. The mean length of MIC and ALMC was 7.5mm and 1.2mm, respectively and the mean width of LF was 0.9mm. The MIC had a buccal inclination at the initiation point and approximated the lingual plate as extended towards the midline. Analytical statistics including independent samples t-test, paired samples t-test, ANOVA analyses were applied.

Conclusion: Considering the high prevalence of MIC, ALMC and LF and wide range of MIC (1.2mm to 20mm) and ALMC (1mm to 9.9mm) length, CBCT is recommended for patients prior to surgical procedures in the anterior mandible to determine the exact location of these anatomical structures.

Keywords: Mandible; Lingual frenum; Cone-beam computed tomography.

Introduction

There is a general belief that the inter-mental area of the mandible is a safe zone for implant placement and surgical procedures such as chin surgeries, genioplasty and plating of the anterior mandible following trauma; however, the exact anatomy of this region is still a matter of debate [1].

Anterior loop of the mandibular canal (ALMC), mandibular incisive canal (MIC) and lingual foramen (LF) are among the important anatomical structures in the anterior mandible [2]. Mental foramina are located bilaterally in buccal cortex of the mandible close to the apex of premolar teeth. Mental nerve in conjunction with blood vessels

exist mental foramina to provide innervation and blood supply to the lower lip, buccal vestibule, alveolar mucosa and gingiva mesial to the mandibular first molars [2]. The inferior alveolar nerve forms a loop anterior to the mental foramen prior to exiting the canal; this part of the nerve is referred to as the anterior loop. Considering the anatomical location of this loop, improper implant placement anterior to the mental foramen can cause edema. If the loop is traumatized or injured, sensory disturbances of mental nerve and pain may pursue [1].

This complication is immediately noticed by patients and is a relatively common complaint after bone removal from the chin area [3]. Also, it has been reported that patients with ALMC have higher risk of mental nerve injury following placement of the most distal implant in inter-mental region [4]. Reports on the incidence of ALMC and its length are controversial [5,6,7]. The MIC is the continuation of mandibular canal anterior to the mental foramen, which contains neurovascular bundles that innervate the teeth in the anterior mandible [2]. Accurate localization of MIC with a large diameter plays an important role in prevention of postoperative sensory disturbances. Direct traumatization of the nerve or edema and hematoma developed around it can lead to sensory disturbances, pain and compression of nerve [4,8]. However, traumatization of incisive nerve may not be easily detectable by patients due to decreased dental sensation [3]. Studies on cadavers have reported that MIC is present in almost 100% of cases [8-10].

On radiographs, LF is visualized in the form of a circular radiolucent area surrounded by a radiopaque margin [11]. It is located in the mandibular midline higher than the genial tubercle close to the periapical region of incisors. Incisive artery branches pass through the LF and anastomose with lingual artery [1]. Conventional radiographic modalities such as panoramic radiography are often incapable of efficient visualization of these structures. Masking of the buccolingual dimensions of these structures on two-dimensional (2D) radiographs and non-uniform image magnification in panoramic radiography further complicate accurate measurement of dimensions [12]. Evidence shows that conventional radiography has numerous limitations in visualization of ALMC, MIC and LF. Al-Ani et al [13]. Compared the visualization of MIC on panoramic radiographs and cone beam computed tomography (CBCT) scans and showed that MIC was seen on 56% of panoramic radiographs and 100% of CBCT scans. Thus, CBCT is believed to be a reliable modality for

evaluation of the presence/absence of ALMC, MIC and LF and their measurements [1]. Considering the significance of having adequate knowledge about anatomical variations in the anterior mandible prior to surgical procedures, this study aimed to assess the prevalence, position and anatomical characteristics of MIC, LF and ALMC in an Iranian population using CBCT.

Materials and Methods

This retrospective study was conducted on 103 CBCT scans of patients presenting to a private radiology clinic to take CBCT scans as part of their routine preoperative workup for implant placement. Sample size was calculated to be a minimum of 100 CBCT scans using Minitab software according to a previous study by Apostolakis and Brown [7] considering $\alpha=0.05$, $d=0.3$ and standard deviation of 1.71.

In this study, CBCT scans with the following inclusion criteria were chosen:

- Minimum patient age of 18 years (to ensure complete growth and development of the mandible).
- No history of surgical procedure, trauma or lesion in the anterior mandible.
- The entire area between the edges of the teeth and inferior border of the mandible had to be visible on CBCT scans.
- High diagnostic quality of images and absence of artifacts.
- Visibility of the area between the two mental foramina.
- Absence of significant asymmetry of the mandible.
- Absence of severe resorption of mandibular ridge.

The CBCT scans were selected using convenience sampling and classified based on age and sex of patients and right/left quadrants. The selected CBCT scans belonged to 39 males and 64 females with a mean age of 53 years. All images had been taken with NewTom VG CBCT unit (Imageworks, Verona, Italy) in zoom mode with 6x12cm field of view and 0.24mm voxel size. The exposure settings were 110kV, 3.6 to 5.4 seconds of exposure time and 1 to 20mA (adjusted automatically). Images were viewed using NNT Viewer software version 2.21 (Imageworks, Verona, Italy). The NNT Viewer software has 0.1mm measurement accuracy. First, contrast, density and resolution adjustments were made for better visualization of anatomical

landmarks. Axial slices parallel to the inferior border of the mandible were reconstructed. Next, visibility of ALMC on the axial slice with the highest quality was determined as unidentifiable, poor, moderate or good. In a proper area, cross-sectional slices were generated to confirm the presence of ALMC (Figure 1). In panoramic tab of the software, optimal slice was defined on axial section of image with adequate thickness to obtain a suitable panoramic radiograph with the two mental foramina on the two sides. By decreasing the slice thickness of panoramic radiograph, ALMC was visualized and measured. Based on a previous study on size of MIC, the largest diameter of MIC was considered to be 3mm. Thus, the initiation point of ALMC was considered to be the point with canal diameter over 3mm [7]. For evaluation of MIC, in panoramic tab, optimal image slice was defined on axial section of image to obtain a suitable panoramic image with the two mental foramina on both sides. By decreasing the panoramic image thickness, MIC path was marked. By evaluating the cross-sectional and axial images, presence (visualization) of MIC was determined to be indefinite, poor, moderate or good.

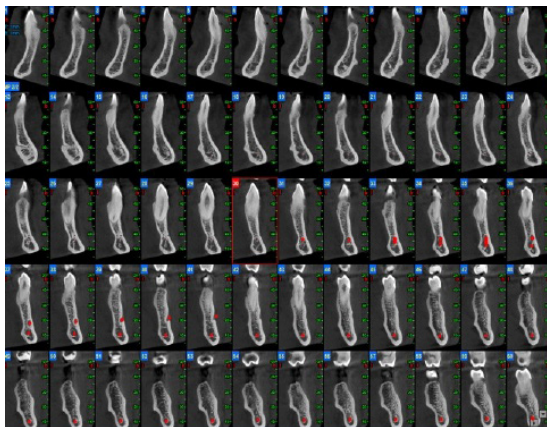


Figure 1. Cross-sectional images for evaluation of the length of MIC.

According to the anatomical definition of MIC, it includes areas with opaque border around the canal [3]. The initiation point of MIC was determined to be the area where canal diameter was less than 3mm. Next, cross-sectional slices were obtained from the initiation point of MIC to its termination point, i.e. the last cross-sectional scan with an opaque border. Measurements on MIC were made at 3mm intervals. The distance from the MIC to the inferior border of mandible was measured from the most-internal part of the inferior cortical border of MIC parallel to the axial plane and perpendicular to the most external part of the inferior border (Figure 2).

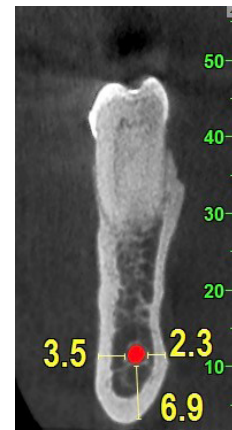


Figure 2. Measurement of distance from the MIC to the buccal, lingual and inferior border.

The distance from the MIC to buccal plate was measured from the most internal part of the buccal cortical border of MIC parallel to axial plane, and perpendicular to the most external part of the buccal plate (Figure 2). The distance from the MIC to lingual plate was also measured at the most internal part of lingual cortical border of MIC parallel to axial plane and perpendicular to the most external part of the lingual border (Figure 2). The diameter of MIC was measured at the highest distance between the internal cortical borders of MIC. Visibility of LF was classified as indefinite, poor, moderate and good. Its width was measured at the widest area between the internal parts of the cortical border.

All observations and measurements were made by two oral and maxillofacial radiologists in a semi-dark room on a Samsung monitor (Sync Master, Samsung, South Korea) with 1680x1050 resolution and 300cd/m² brightness. Measurements were repeated with one-month interval to ensure interobserver and intraobserver reliability. For calibration of observers, two patients were evaluated in a pilot study prior to the main study. In case of disagreement between the two observers, the case was discussed until an agreement was achieved.

Data were analyzed using SPSS version 22 (SPSS Inc., IL, USA). The mean and standard deviation were calculated for quantitative variables. Analytical statistics including independent samples t-test, paired samples t-test, ANOVA analyses were applied. $P < 0.05$ was considered statistically significant.

Results

A total of 103 CBCT scans of 64 females and 39 males with a mean age of 53.18 ± 14.4 years (range 20-80 years) were evaluated. The MIC was detected on 90%

of CBCT scans and was bilateral in 68% and unilateral in 22%. In cases with unilateral MIC, it was located in the left side in 8% and in the right side in 14% of the cases. The mean length of MIC was 7.5 ± 3.52 mm in the right side and 7.1 ± 3.23 mm in the left side (range 1.2 to 20 mm, Table 1).

The MIC at both right and left sides had a buccal inclination at the beginning such that in the right side, the distance from the canal (initiation point) to buccal plate was 3.69 ± 1.7 mm; this distance was 5.3 ± 1.4 to the lingual plate. In the left side, the distance from the initiation point of canal to buccal plate was 3.5 ± 1.3 mm; this distance was 5.47 ± 1.6 mm to lingual plate. The mean diameter of MIC was 1.19 ± 0.48 mm in the right and 1.29 ± 0.93 mm in the left side. Table 2 shows the length of MIC, the distance between its initiation point to buccal and lingual plates and its diameter in males and females. These variables were not significantly different between males and females ($P > 0.05$) or between

the right and left sides ($P > 0.05$) except for the MIC length, which was 0.5 mm longer in the right side compared to the left side and this difference was statistically significant ($P = 0.015$, Table 3).

Table 4 shows the distance from borders of MIC to different landmarks measured from the canal initiation point at 3 mm intervals. A correlation was noted between the presence of MIC and presence of ALMC ($P < 0.05$). The ALMC was found in 84% of cases. The mean length of ALMC was 2.9 ± 1.23 mm in the right and 2.7 ± 1.32 mm in the left side. Maximum length of ALMC was 9.9 mm and its minimum length was 1 mm (Table 5). In patients, LF was noted in 76% of cases. The mean width of LF was 0.9 ± 0.45 mm; its maximum width was 1.6 mm and its minimum width was 0.5 mm. Interobserver and intraobserver reliability were calculated to be 96% and 98%, respectively.

Group	Number	Mean	Minimum	Maximum	Standard deviation
All		7.3	1.2	20	3.20
Right	103	7.5	1.2	18.5	3.25
Left	103	7.01	1.5	20	3.32
Females	64	7.45	1.2	19	3.3
Males	39	7.35	1.2	20	3.25

Table 1. The mean length of mandibular incisive canal in the right and left sides and in males and females (in millimeters).

Gender	Mean length	Distance from buccal plate	Distance from lingual plate	Canal diameter
Males	7.57 ± 2.73 (7.03-8.11)	3.4	5.6	1.29
Females	7.39 ± 2.33 (6.93-7.85)	3.8	5.3	1.2
P value	0.4	0.19	0.4	0.3

Table 2. The mean length of mandibular incisive canal, its distance (at its initiation point) from the buccal and lingual plates and its diameter (in millimeters) in males and females.

Side	Mean length	Distance from buccal plate	Distance from lingual plate	Canal diameter
Right	7.5 ± 3.52 (6.8-8.2)	3.6	5.30	1.19
Left	7.1 ± 3.23 (6.46-7.74)	3.5	5.47	1.29
P value	0.015	0.45	0.40	0.25

Table 3. The mean length of mandibular incisive canal, its distance (at its initiation point) from the buccal and lingual plates and its diameter (in millimeters) in the right and left sides.

Variables	Slice 1	Slice 2	Slice 3
Inferior border	10.76±1.8 (10.4-11.12)	10.46±1.91 (10.24-10.48)	10.06±2.51 (9.56-10.56)
Buccal plate	3.81±1.51 (3.51-4.11)	4.04±1.67 (4.34-3.74)	3.83±1.30 (3.57-4.09)
Lingual plate	5.48±1.57 (5.17-5.79)	5.11±1.77 (4.76-5.46)	5.40±1.79 (5.05-5.75)
Canal diameter	1.4	1	0.95

Table 4. Distance from borders of mandibular incisive canal to different landmarks measured at the canal initiation point and at 3mm intervals (in millimeters).

Group	Mean	Minimum	Maximum	Standard deviation
All	2.8	1	9.9	1.43
Right	2.9	1.2	9.9	1.24
Left	2.7	1	8	1.60
Females	2.6	1	8.9	1.04
Males	3.7	1.25	9.9	1.48

Table 5. The mean length of the anterior loop of the mandibular canal in the right and left sides and in males and females (in millimeters).

Discussion

Previous studies have shown that 2D imaging modalities such as panoramic radiography have limitations in optimal visualization of these structures. Kaya et al, [14] and Ngeow et al, [15] stated that presence and length of ALMC could not be well determined on panoramic radiographs. Thus, CBCT appears to be a more reliable modality for evaluation of ALMC, MIC and LF. Langley-DeGroot [16] evaluated computed tomography (CT) scans of patients complaining of sensory disturbances and pain following implant placement in the inter-mental region and noticed that the MIC had been injured in these patients.

In the current study, MIC was detected in 90% of the cases, which was in agreement with the results of similar previous studies [3,5,17-19]. Apostolakis et al, [3] Lobo [17], Markis et al, [19] and Jacobs et al, [18] evaluated CBCT scans of patients and reported the prevalence of MIC to be 90-93%. Pires et al, [12] in 2012 reported the prevalence of MIC to be 85%; this rate was 83% in the study by Parnia et al, [1] in 2011 on CBCT scans. In our study, the distance between the initiation point of MIC and the inferior border of the mandible was influenced by gender such that this distance was shorter in females than in males; this difference is due to the smaller dimensions of the mandible in females compared to males. This finding was in line with that of Pires et al, [12] in 2012, who evaluated the position of MIC on CBCT scans.

Many cases of implant failure occur in patients with MIC diameter over 2mm [19]. In the current study, the mean MIC diameter was 1.4mm at canal initiation point, 1mm at the second 3mm interval and 0.95mm at the third 3mm interval; these values indicated that canal diameter decreased towards the midline. The greatest diameter of MIC in our study was 2.4mm. Our results in this respect were in agreement with those of Apostolakis et al [3], in 2013, Mraiwa et al, [10] in 2003, Mardinger et al, [5] in 2000 and Parnia et al, [1] in 2011 who evaluated the mean diameter of MIC to be 1.2, 1.8, 1.3 and 1.4mm, respectively. Our findings in this respect were also in accord with that of Nimigean et al, [20] reported the mean canal diameter to be 0.48 to 2.9mm. The widest MIC was reported in the study by Mraiwa et al, [10] which was 3.4mm. However, the mean diameter of MIC in our study was smaller than the values reported by Uchida et al, [21] in 2009 (6.6mm) and Pires et al, [12] in 2012 (0.4mm to 4.6mm); these controversies can be due to racial and ethnic differences. Thus, a specific range generalizable to all populations cannot be determined for the mean diameter of MIC.

The mean length of MIC was 7.3mm in our study (range 1.2 to 20mm). This finding was in accordance with the results of Apostolakis et al, [3] in 2013 and Pires et al, [12] in 2012 who reported the mean length of MIC to be 8.5mm and 7mm, respectively. However, the mean length of MIC in our study was much lower than the values reported by De Andrade et al, [9] in

2001 and Markis et al, [19] in 2010, who reported the mean length of MIC to be 21mm and 15mm, respectively. This difference in the results may be attributed to several factors. In the current study, we carefully followed the path of MIC in order not to mistaken it with other canals that enter into the lingual cortex; thus, canal length on cross-sectional images would be shorter as such. Also, in the current study, the length of ALMC was measured at the same time; thus, only part of the canal with less than 3mm diameter was considered and measured as the MIC. Moreover, MIC becomes narrower as it approaches the midline and thus, can be more significantly influenced by the effects of factors such as contrast and resolution of image (and may be unidentifiable at the end of its path). Last but not least, reduction in the amount of cortical bone surrounding the MIC may also play a role in this regard [3,7]. The length of MIC was significantly different in the right and left sides but the magnitude of difference (0.5mm) was not clinically significant.

Evaluation of the path of MIC in our study revealed that it had a buccal inclination at its initiation point at both right and left sides. As extending from the mental foramen towards the midline, the MIC approximated the inferior border of the mandible and distanced from the buccal plate while approached the lingual plate; the same finding was reported by Mardinger et al, [5] in 2000, Apostolakis et al, [3] in 2013, De Andrade et al, [9] in 2001, Markis et al, [19] in 2010 and Pires et al, [12] in 2012.

Part of the mandibular nerve exiting the mental foramen creates a loop anterior to it and is referred to as the anterior loop [2]. Accurate determination of its presence/absence and its length is important prior to inter-mental surgeries to prevent nerve injury. It is particularly important when implants must be placed in the inter-mental region due to inadequate bone height in the posterior mandible [22]. Some researchers have recommended to consider a 5mm safe margin around mental foramen for implant placement or bone resection in this region. However, a completely safe margin cannot be defined for ALMC due to individual variations [7].

In the current study, 84% of the cases had ALMC. Apostolakis et al, [3] in 2013, Parnia et al, [1] in 2013 and Filo et al, [22] in 2013 reported that ALMC was present on CBCT scans of 48%, 84% and 64% of the cases, respectively. High prevalence rate obtained in our study can be attributed to the use of zoom mode in CBCT. The mean length of ALMC was 2.9mm in our study (range 1mm to 9.9mm). A wide range has been

reported for ALMC length in previous studies. Li et al, [23] in 2013 and de Oliveira Júnio et al, [24] in 2011 evaluated CT scans of patients and reported a mean length of 2.09mm and 5mm for ALMC, respectively. Apostolakis et al, [3] in their study in 2013 on CBCT scans, Parnia et al, [1] in their study in 2010 and Filo et al, [22] in their study in 2013 reported the mean length of ALMC to be 0.89, 3.54 and 1.16mm, respectively. Considering the variability in the results of studies on the mean length of ALMC, further investigations are required in this respect. Also, since in our study an ALMC with almost 10mm of length was identified, a 5mm safe zone around the mental foramen cannot be considered "completely safe" after all as suggested by Levine et al, [25] and Dik et al [26].

In our study, no significant difference was noted in the mean length of ALMC in the right and left sides but its length was greater in males than in females, which was in agreement with the results of Li et al, [23] in 2013, Uchida et al, [21] in 2009 and Apostolakis and Brown et al, [7] in 2011. On radiographs, LF manifests as a radiolucent area surrounded by a radiopaque margin [11]. Vessels passing through LF are large enough to cause massive hematoma at the floor of the mouth if injured. In our study, LF was found in 76% of the cases, which is higher than the rate reported by Parnia et al, [1] in 2010; they reported that LF was present on 49% of CBCT scans of patients. This difference in the results of the two studies may be attributed to the use of zoom mode in CBCT in our study. However, Markis et al, [19] and Jacob et al. [18] found LF in 81% and 82% of cases, respectively, which was close to our obtained value.

The mean width of LF was 0.9mm in our study (range 0.5mm to 1.6mm), which was close to the values reported by Rosano et al, [27] in 2009, Liang et al, [28] in 2007, and Direk et al, [29] in 2018 who reported the mean width of LF to be 0.9mm, 0.8mm, 0.7mm and 0.7mm, respectively. Further studies on a larger sample size of different racial and ethnic groups are recommended to determine the length of ALMC and MIC diameter.

Conclusion

Considering the high prevalence of MIC, ALMC and LF and wide range of MIC length (1.2mm to 20mm) and ALMC length (1mm to 9.9mm), CBCT is recommended prior to surgical procedures in the anterior mandible to precisely localize the anatomical structures in this area and prevent postoperative complications caused by accidental traumatization of these

structures.

Conflict of Interest

There is no conflict of interest to declare.

References

- [1] Parnia F, Moslehifard E, Hafezeqoran A, Mahboub F, Mojaver-Kahnamoui H. Characteristics of anatomical landmarks in the mandibular interforaminal region: a cone-beam computed tomography study. *Med Oral Patol Oral Cir Bucal* 2012; 17:e420-e425.
- [2] Al-Mahalawy H, Al-Aithan H, Al-Kari B, Al-Jandan B, Shujaat S. Determination of the position of mental foramen and frequency of anterior loop in Saudi population. A retrospective CBCT study. *Saudi Dent J* 2017; 29(1):29-35.
- [3] Apostolakis D, Brown JE. The dimensions of the mandibular incisive canal and its spatial relationship to various anatomical landmarks of the mandible: a study using cone beam computed tomography. *Int J Oral Maxillofac Implants* 2013; 28:117-124.
- [4] Rosa MB, Sotto-Maior BS, Machado Vde C, Francischone CE. Retrospective study of the anterior loop of the inferior alveolar nerve and the incisive canal using cone beam computed tomography. *Int J Oral Maxillofac Implants* 2013; 28:388-392.
- [5] Wong SK, Patil PG. Measuring anterior loop length of the inferior alveolar nerve to estimate safe zone in implant planning: a CBCT study in a Malaysian population. *J Prosthet Dent* 2018; 120(2):210-3.
- [6] Prakash O, Srivastava PK, Jyoti B, Mushtaq R, Vyas T, Usha P. Radiographic evaluation of anterior loop of inferior alveolar nerve: A cone-beam computer tomography study. *Niger J Surg* 2018; 24(2):90-4.
- [7] Gala V, Tirpude V, Shah D, Doshi A, Fernandes G. A retrospective cone beam computed tomography (CBCT) study of the assessment of the length of the anterior loop of the inferior alveolar nerve. *Int J Sci Res Sci Technol* 2018; 4(5):828-32.
- [8] Goyushov S, Tözüm MD, Tözüm TF. Assessment of morphological and anatomical characteristics of mental foramen using cone beam computed tomography. *Surg Radiol Anat* 2018; 40(10):1133-9.
- [9] Kabak SL, Zhuravleva NV, Melnichenko YM, Savrasova NA. Study of the mandibular incisive canal anatomy using cone beam computed tomography. *Surg Radiol Anat* 2017; 39(6):647-55.
- [10] Sener E, Onem E, Akar GC, Govsa F, Ozer MA, Pinar Y, et al. Anatomical landmarks of mandibular interforaminal region related to dental implant placement with 3D CBCT: comparison between edentulous and dental mandibles. *Surg Radiol Anat* 2018; 40(6):615-23.
- [11] He P, Truong MK, Adeeb N, Tubbs RS, Iwanaga J. Clinical anatomy and surgical significance of the lingual foramina and their canals. *ClinAnat* 2017; 30(2):194-204.
- [12] Pires CA, Bissada NF, Becker JJ, Kanawati A, Landers MA. Mandibular incisive canal: cone beam computed tomography. *Clin Implant Dent Relat Res* 2012; 14:67-73.
- [13] Al-Ani O, Nambiar P, Ha KO, Ngeow WC. Safe zone for bone harvesting from the interforaminal region of the mandible. *Clin Oral Implants Res* 2013; 24 Suppl A100:115-121.
- [14] Kaya Y, Sencimen M, Sahin S, Okcu KM, Dogan N, Bahcecitapar M. Retrospective radiographic evaluation of the anterior loop of the mental nerve: comparison between panoramic radiography and spiral computerized tomography. *Int J Oral Maxillofac Implants* 2008; 23:919-925.
- [15] Ngeow WC, Dionysius DD, Ishak H, Nambiar P. A radiographic study on the visualization of the anterior loop in dentate subjects of different age groups. *J Oral Sci* 2009; 51:231-237.
- [16] Langley-DeGroot M, Joshi Y, Lehman D, Rao S. Atypical neuroleptic malignant syndrome associated with paliperidone long-acting injection: a case report. *J Clin Psychopharmacol* 2016; 36(3):277-9.
- [17] Lobo TM, Patil RC, Cune MS. Bone dimension assessment for placement of implants in the interforaminal region of the mandible: A cone beam computed tomography study. *Int J Appl Dent Sci* 2018; 4(1):101-5.

- [18] Kabak SL, Zhuravleva NV, Melnichenko YM, Savrasova NA. Study of the mandibular incisive canal anatomy using cone beam computed tomography. *Surg Radiol Anat* 2017; 39(6):647-55.
- [19] Makris N, Stamatakis H, Syriopoulos K, Tsiklakis K, van der Stelt PF. Evaluation of the visibility and the course of the mandibular incisive canal and the lingual foramen using cone-beam computed tomography. *Clin Oral Implants Res* 2010; 21:766-771.
- [20] Nimigean V, Sirbu VD, Nimigean VR, Bădiță DG, Poll A, Moraru SA, et al. Morphological assessment of the mandibular canal trajectory in edentate subjects. *Rom J Morphol Embryol* 2018; 59(1):235-42.
- [21] Uchida Y, Noguchi N, Goto M, Yamashita Y, Hanihara T, Takamori H, et al. Measurement of anterior loop length for the mandibular canal and diameter of the mandibular incisive canal to avoid nerve damage when installing endosseous implants in the interforaminal region: a second attempt introducing cone beam computed tomography. *J Oral Maxillofac Surg* 2009; 67:744-750.
- [22] Filo K, Schneider T, Locher MC, Kruse AL, Lübbers HT. The inferior alveolar nerve's loop at the mental foramen and its implications for surgery. *J Am Dent Assoc* 2014; 145:260-269.
- [23] Li X, Jin ZK, Zhao H, Yang K, Duan JM, Wang WJ. The prevalence, length and position of the anterior loop of the inferior alveolar nerve in Chinese, assessed by spiral computed tomography. *Surg Radiol Anat* 2013; 35:823-830.
- [24] De Oliveira Júnior MR, Saud AL, Fonseca DR, De-Ary-Pires B, Pires-Neto MA, de Ary-Pires R. Morphometrical analysis of the human mandibular canal: a CT investigation. *Surg Radiol Anat* 2011; 33:345-352.
- [25] Levine MR, Allen RC. *Manual of oculoplastic surgery*. New York: Springer; 2018.
- [26] Dik EA, De Ruitter AP, van der Bilt A, Koole R. Effect on the contour of bone and soft tissue one year after harvesting chin bone for alveolar cleft repair. *Int J Oral Maxillofac Surg* 2010; 39(10):962-7.
- [27] Liang X, Jacobs R, Lambrichts I, Vandewalle G. Lingual foramina on the mandibular midline revisited: a macroanatomical study. *Clin Anat* 2007; 20:246-251.
- [28] Vandewalle G, Liang X, Jacobs R, Lambrichts I. Macroanatomic and radiologic characteristics of the superior genial spinal foramen and its bony canal. *Int J Oral Maxillofac Implants* 2006; 21:581-586.
- [29] Direk F, Uysal II, Kivrak AS, Fazliogullari Z, Dogan NU, Karabulut AK. Mental foramen and lingual vascular canals of mandible on MDCT images: anatomical study and review of the literature. *Anatom SciInt* 2018; 93(2):244-53.

Please cite this paper as:

Ghoncheh Z, Moghaddam Zadeh B, Shaeri S; Prevalence and position of mandibular incisive canal, anterior loop of the mandibular canal and lingual foramen using cone beam computed tomography. *J Cranio-maxillofac Res* 2019; 6(4): 143-150