



Intraoral lipoma, surgical approach: A Case report

Farnoosh Razmara¹, Nima Dehghani^{1*}, Xaniar Mahmoudi², Mohammad Reza Reshadi³, Mahdi

Mohammadi³

1. Department of Oral and Maxillofacial Surgery, School of Dentistry, Tehran University of Medical Sciences, Tehran, Iran.

2. School of Dentistry, International Campus, Tehran University of Medical Sciences, Tehran, Iran.

3. School of Dentistry, Tehran University of Medical Sciences, Tehran, Iran.

ARTICLE INFO

Article Type: Case Report

Received: 3 Jun. 2019

Revised: 1 Aug. 2019

Accepted: 25 Sep. 2019

*Corresponding author:

Nima Dehghani

Department of Oral and Maxillofacial Surgery,
School of Dentistry, Tehran University of Medical
Sciences, Tehran, Iran.

Tel: +98-21-42794304

Fax: +98-21-42794304

Email: nimadt2002@Gmail.com

ABSTRACT

Background: Lipoma is a rare benign tumor that overgrows in oral cavity. Its occurrence rate is about 1-4% with predilection for males rather than females. Lipoma is associated with adipose tissue and is usually seen in major salivary glands, buccal mucosa, and vestibule. Fifty percent of lesions are seen in buccal mucosa. The progressive and aggressive growth of these lesions may interfere with speech and mastication owing to the dimensions and location of the tumor. The lesion basically affects the individuals of 4th to 5th decades. Lipoma is managed by surgical excision using scalpel, laser, or electro-cautery.

Case Presentation: This study presents two 63 and 18 years old male patients with lipoma in their buccal mucosa along with their improved situation following the treatment. The treatment included surgical excision of the lesion and suturing the surgical area.

Conclusions: The incidence of intraoral lipoma is low and buccal mucosa is the most common region for the occurrence of oral lipoma. Most clinicians suggested surgical techniques as a certain treatment.

Keywords: Lipoma; Intraoral lipoma; Soft tissue tumor; Mouth; Intraoral neoplasm; Adipose tissue.

Introduction

Lipomas are benign tumors with mesenchymal origin which can occur in all anatomic regions and are called ubiquitous tumors [1]. The first description of oral lesion was presented in 1848 by Roux, who introduced the lipoma as yellow epulis [2]. Lipoma is composed of mature adipocyte and is usually surrounded by a fibrous capsule. Lipoma is one of the most common soft tissue mesenchymal tumors but not common in oral cavity, with 15-20% in head and neck and 1-4% in oral cavity [3]. It is a yellowish and submucosal tumor with slow growth rate, its metabolism is completely independent of normal adipose

tissue, and its size is independent of the amount of fat intake. It is also seen more often in the obese people and its pathogenicity has not yet been determined. The selective treatment for lipoma is surgical excision and its recurrence is unexpected [4,5,6].

Case Presentation

Case 1

A 63-year-old man went to a dentist to make dentures. The dentist noticed a swelling in the mandible vestibule in

the teeth 4 and 5 in clinical examinations. The patient was referred to an oral and maxillofacial surgeon for further examination. The patient's panoramic view was diagnosed with normal bone structure. Since the color of the lesion was yellow, the patient had no complaints of the lesion and the lesion was moveable. The differential diagnosis was lipoma, and excisional biopsy was performed. Horizontal incision was performed on the lesion and the tissue on the lesion was undermined with Mets (Fig. 1). When removing the lesion, we observed right mental nerve in the lesion (Fig. 2). The nerve was carefully removed from the lesion and the site of the lesion was sutured (Fig. 3). In Histopathologic examination of the lesion, microscopic sections showed a well-defined encapsulated neoplastic tissue composed of mature adipocytic cells arranged in a lobular structure. Therefore, it was lipoma. The patient's conditions were good and there were no sign of recurrence after twelve months.

Case 2

An 18-year-old man referred to a maxillofacial department. His chief complaint was painless swelling in the buccal mucosa for about eight months. The lesion was about 1.5cm and mainly soft on palpation (Fig. 4). Excisional biopsy was done under local anesthesia. The incision was about 2cm (Fig. 5). The lesion was capsulated and completely dissected (Fig. 6 and 7). The laboratory examination revealed an adipose tissue and a thin capsule surrounding the lesion and pathologic diagnosis showed an intraoral fibrolipoma. There were no complications during and after the surgery and no sign of recurrence after twelve months.

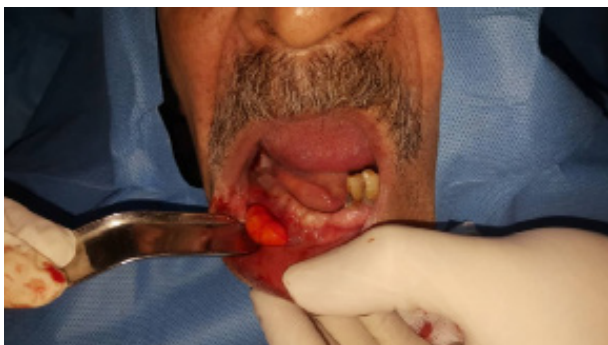

Fig. 1. Intraoral view of oral lipoma after performing horizontal incision.

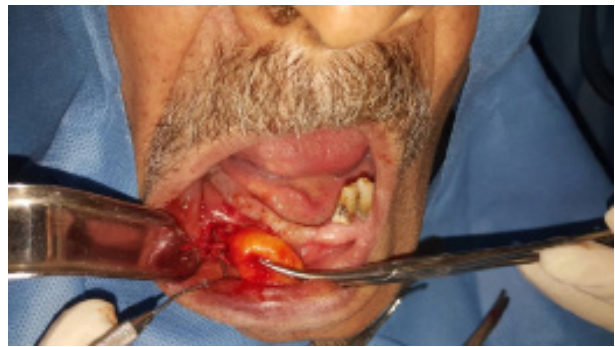

Fig. 2. Right mental nerve is seen in the lesion.

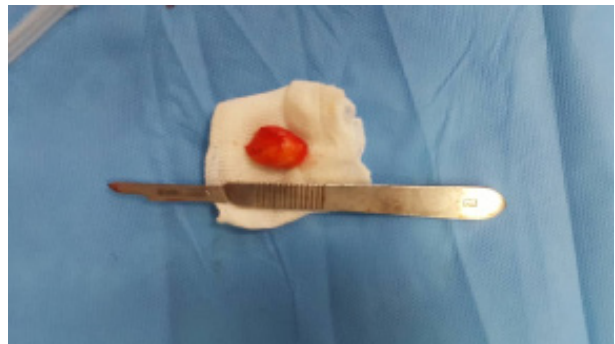


Fig. 3. Removed lesion.

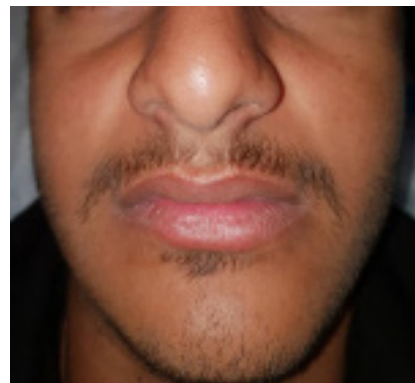

Fig. 4. Painless swelling in the right mandible.

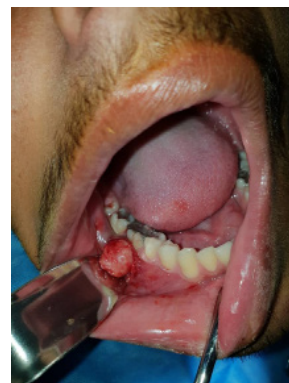

Fig. 5. Intraoral view of the exposed lesion.

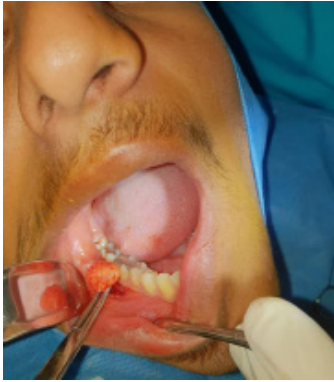

Fig. 6. Removing the lesion from its site.

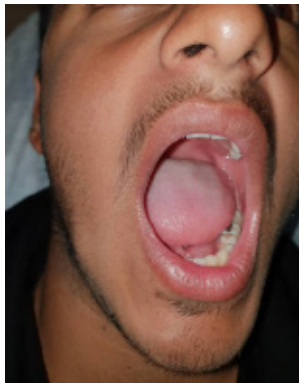


Fig. 7. Post operation view. The patient's swelling has resolved.

Discussion

Lipoma is a benign tumor that can occur in any part of the body. Lipoma can be found in both soft and bony tissues [7]. Lipomas usually occur in patients with an age range of 40-60 years, with a peak of 40 years and happening more in men [8-10]. The size of the tumor depends on its location, varying from 15-20 mm. However, tumors with a size of 50mm have been reported [11]. Buccal mucosa and vestibule are two sites where 50% of intraoral lipomas occur. The areas which are less involved include the floor of the mouth, tongue, lips, palate, and retromolar pad [8]. The tumor may require surgery if it is created on the floor of the mouth and its size is large and interferes with speech and chewing [12-14]. Lipomas are usually slow-growing and asymptomatic and their clinical features may vary according to the location of the lesion [15].

Lipomas are apparently and microscopically similar to normal fat tissue but with higher metabolism [2,16]. They are not used as energy sources [3,17]. Since there is a tissue similarity between normal fat cell and lipoma. Accurate clinical and surgical information is very important for definitive diagnosis [18]. For patients with multiple tumors, the term lipomatosis is used

[19]. Lipomas is usually subcutaneous but may involve deeper tissues. They rarely cause pain and are asymptomatic, which can delay their treatment. Intraoral lipomas are rare and may be detected during routine oral and dental examinations [20]. Moreover, if they reach great dimensions, they can interfere with speech and mastication, which can be a factor for the recognition and identification of oral lipoma [21].

Differential diagnosis of intraoral lipomas includes oral dermoid and epidermoid cysts, benign tumor of salivary glands, oral lymphoepithelial cyst, mucocele, benign neoplasm of mesenchymal tissue, ectopic thyroid tissue, lymphoma, and ranula [15]. Histological lipoma cells cannot be distinguished from herniated buccal fat pad. Buccal fat pad hernia presents as an expanding pedunculated mass emanating from the deep soft tissue in the buccal mucosa suddenly after trauma, a flattened mass that comes from the deep soft tissue of buccal mucosa [22].

There is no consensus over the pathogenesis of oral lipoma, but some theories such as fat degeneration, heredity, infection, basis of hormone, metaphase of muscle cells, chronic stimulation and trauma, and nest of the embryonic lipoblastic cells in the origin support the lipoma pattern. Buccal mucosa is often traumatized and the possible role of trauma in the growth of intraoral lipoma cannot be denied [3,23]. Diagnostic aids include ultrasonography, computed tomography, and MRI, which can determine the location, extent, and margins of the mass [20]. The treatment for all histological variants of intraoral lipomas is simple local excision [2]. Less than 5% of the lipomas are recurrent [19]. Infiltrating lipomas are difficult to extirpate and are thus liable to recurrence. Recurrence is reduced by wide surgical excision [8]. The malignant change is almost impossible and only a few have been reported in the articles [19].

Conflict of Interest

There is no conflict of interest to declare.

Acknowledgements

The authors thank the anonymous referees for their kind and valuable comments that improved the clarity and quality of the manuscript.

References

- [1] Neville BW, Damm DD, Allen CM, Bouquot JE. Soft tissue tumors. *Oral and Maxillofacial Pathol-*

- ogy. 2nd ed. Philadelphia: W.B. Saunders; 2002.
- [2] Kaur RP, Kler S, Bhullar A. Intra oral lipoma: report of 3 cases. *Dent Res J*. 2011; 8(1): 48–51.
- [3] Fregnani ER, Pires FR, Falzoni R et al. Lipomas of oral cavity: clinical findings, histological classification and proliferative activity of 46 cases. *Int J Oral Maxillofac Surg*. 2003; 32(1):49–53.
- [4] Keskin G, Ustundag E, Ercin C. Multiple infiltrating lipomas of the tongue. *J LaryngolOtol*. 2002; 116(05):395–7.
- [5] Cawson RA, Binnie WH, Speight PM, Barrett AW. Churchill Livingstone, Lucas's Pathology of Tumors of the Oral Tissues. 4th ed. New York; 1984.
- [6] Epivatianos A, Markopoulos AK, Papayanatou P. Benign tumors of adipose tissue of the oral cavity: a clinicopathologic study of 13 cases. *J Oral Maxillofac Surg*. 2000; 58:1113–1118.
- [7] Dehghani N, Razmara F, Padeganeh T, Mahmoudi X. Oral lipoma: Case report and review of literature. *Clinical case reports*. 2019; 7(4):809.
- [8] Naruse T, Yanamoto S, Yamada S, Rokutanda S, Kawakita A, Takahashi H, et al. Lipomas of the oral cavity: Clinicopathological and immunohistochemical study of 24 cases and review of the literature. *Indian J Otolaryngol Head Neck Surg*. 2015;67:67-73.
- [9] Adoga AA, Nimkur TL, Manasseh AN et al. Buccal soft tissue lipoma in an adult Nigerian: a case report and literature review. *J Med Case Rep*. 2008; 2:382–10.
- [10] Nayak S, Nayak P. Lipoma of the oral mucosa: a case report. *Arch Orofacial Sci*. 2011; 6:37–9.
- [11] Park BG, Choi DJ, Park JW, Kim JS. Oral cavity lipoma: A case report. *J Korean Assoc Oral Maxillofac Surg*. 2015; 41:213–6.
- [12] Motagi A, Aminzadeh A, Razavi SM. Large oral lipoma: Case report and literature review in Iran. *Dent Res J (Isfahan)*. 2012; 9:350–352.
- [13] Raj AA, Shetty PM, Yadav SK. Lipoma of the floor of the mouth: report of an unusually large lesion. *J Maxillofac Oral Surg*. 2014; 13:328–331.
- [14] Colella G, Biondi P, Caltabiano R, Vecchio GM, Amico P, Magro G. Giant intramuscular lipoma of the tongue: A case report and literature review. *Cases J*. 2009; 2:7906–7906.
- [15] Kumar LK, Kurien NM, Raghavan VB, Menon PV, Khalam SA. Intra-oral lipoma: A case report. *Case Rep. Med* 2014; 1–4
- [16] Filho GAN, Caputo BV, Santos CC et al. Diagnosis and treatment of intraoral lipoma: a case report. *J Health Sci Inst*. 2010; 282:129–31.
- [17] Solvonuk PF, Taylor GP, Hancock R et al. Correlation of morphologic and biochemical observations in human lipomas. *Lab Invest*. 1984; 51:469–74.
- [18] Bandeca MC, de Padua JM, Nadalin MR et al. Oral soft tissue lipomas: a case series. *J Can Dent Assoc*. 2007; 73:431–4.
- [19] Goldblum JR, Folpe AL, Weiss SW et al. In: Enzinger and Weiss's Soft tissue tumors. 6th ed Philadelphia, PA: Saunders/Elsevier, 2014:443–66.
- [20] Juneja S, Juneja M, Babu NC. Intraoral lipoma in young male patient: A case report. *Int J Sci C Stud*. 2014; 1:44–7.
- [21] Altug HA, Sahin S, Sencimen M et al. Non-infiltrating angiolipoma of the cheek: a case report and review of the literature. *J Oral Sci*. 2009; 51:137–9.
- [22] De Freitas MA, Freitas VS, de Lima AA, Pereira FB, dos Santos JN. Intraoral lipomas: A study of 26 cases in a Brazilian population. *Quintessence Int*. 2009; 40:79–85.
- [23] Fletcher CDM, Unni KK, Mertens F. World Health Organization classification of tumours. Pathology and genetics: tumours of soft tissue and bone. Lyon, France: IARC Press; 2002. Adipocytic tumors; pp. 9–46.

Please cite this paper as:
Razmara F, Dehghani N, Mahmoudi X, Reshadi M, Mohammadi M; Intraoral lipoma, surgical approach: A case report. *J Craniomaxillofac Res* 2019; 6(4): 175-178