



## New design of bone hook for lefort I osteotomy

Hamid Mahmood Hashemi, Farnoosh Razmara\*

Craniofacial Research Center, Tehran University of Medical Sciences, Tehran, Iran; Department of Oral and Maxillofacial Surgery, School of Dentistry, Tehran University of Medical Sciences, Tehran, Iran.

### ARTICLE INFO

#### Article Type: Technical Note

Received: 2 May, 2020

Revised: 2 Nov. 2020

Accepted: 5 Dec. 2020

\*Corresponding author:

Farnoosh Razmara

Craniofacial Research Center, Tehran University of Medical Sciences, Tehran, Iran; Department of Oral and Maxillofacial Surgery, School of Dentistry, Tehran University of Medical Sciences, Tehran, Iran.

Tel: +98-21-22432560

Fax: +98-21-84902473

Email: farnooshrazmara@gmail.com

### ABSTRACT

This article describes a new design by surgical Bone hook that is used for maxillary Le Fort I osteotomy. This instrument with high quality, without damage to surrounding tissues can be used in maxillofacial surgeries.

**Keywords:** Maxillary osteotomy; Le Fort I osteotomy; Surgical bone hook.

## Introduction

The Le Fort I osteotomy is the most common maxillary operation in orthognathic surgery. It is a versatile procedure that allows the maxilla to be repositioned in three planes of space. Alone or in conjunction with mandibular osteotomies, the Le Fort I osteotomy can be used to correct a wide range of dentofacial deformities.

## History

The earliest description of a maxillary osteotomy for access to nasopharyngeal polyps was by von Langenbeck

in Germany in 1859 and Cheever was the first surgeon in the United States to use maxillary mobilization with bone chisels to relieve nasal obstruction caused by recurrent epistaxis. LeFort's classic description of the natural planes of maxillary fracture was published in 1901. Wassmund was the first to apply osteotomies at the Le Fort I level for correction of mid-facial deformities [1-4]. The technique was subsequently modified by several surgeons including Axhausen, Schuchardt, and Willmar [5]. In 1965, Obwegeser improved the precision of the Le Fort I

osteotomy by suggesting complete mobilization of the maxilla so that repositioning was achieved without tension [6]. The operation was slow to gain popularity until Bell's 1973 description of the remarkably resilient maxillary blood supply [7]. Fueled by improvements in technique and the introduction of safe hypotensive anesthesia, the Le Fort I osteotomy has been increasingly utilized over the last four decades.

## Indications

The Le Fort I osteotomy can be used to treat a wide range of dentofacial deformities. This operation can also be used for treatment for obstructive sleep apnea, preparation for prosthetic rehabilitation of atrophied maxillae, and access to nasopharyngeal and spinal cord tumors [8]. Also this technique used for Maxillary advancement in cleft lip and palate patient [9].

## Technique

There are many acceptable modifications to the Le Fort I osteotomy and the sequence of steps may vary from surgeon to surgeon. The following is a description of the authors' preferred approach.

The sequence of osteotomy is as follows (10)

1. Anesthetic and positioning considerations.
2. External reference marker.
3. Incision and sub periosteal dissection.
4. Maxillary osteotomy.
5. Pterygomaxillary disjunction.
6. Septal, Vomerine, and lateral nasal osteotomies.
7. Down-fracture.
8. Mobilization of the maxilla.
9. Intermaxillary fixation, repositioning, and adjustment.
10. Maxillary fixation.
11. Occlusal evaluation.
12. Alar Cinch and wound closure.

In step 9, surgeon should be identified all interferences and reduced prior to final maxillary positioning. Usually interferences area are maxillary buttresses, posterior maxillary walls and maxillary tuberosities, pterygoid plates (unless the maxilla is being inferiorly positioned) and caudal nasal septum and the maxil-

lary crest particularly with superior positioning of the maxilla [10]. When a large superior movement of the maxilla is planned, the inferior turbinates may interfere with repositioning. Soft tissue and osseous turbinec-tomies may be necessary. To eliminate these interferences, the maxilla must be held down by a Volkmann Bone Hook (Fig 1). Bone hook is a highly versatile instrument that is ideally used in procedures that require manipulation and handling of bone. It features a sharp bone hook that allows it to effectively grip bones and move them into the desired position. This instrument usually obtains its grip from the nasopalatin foramen in anterior maxilla and directs the maxilla downward; during this operation, the pressure of the handle on the lower lip is worrying and there is a possibility of injury and swelling to the lower lip (Fig 2). All efforts in maxillofacial surgeries are aimed at minimizing damage to the surrounding tissues, so to solve this problem; we decided to design a new surgical bone hook. In this design, the neck of the device is shaped like a curve, which can follow the curvature of the lips and it does not put pressure on the lower lip and dose not cause damage to it contrast to the above-mentioned hook-like instruments, the presented retractor has an anatomical design with a recess for the lower lip and chin, a flat sheet where exceptionally soft-tissue contact may occur, and a blunt tip that will not hook the lower lip when slipping from the mobilized maxillary segment (Fig 3). The assistant surgeon holds the retractor with a vertical fist on the chest of the patient. The tip of the instrument is located at the anterior nasal floor, or in the frontal recess of the maxillary sinus. It will not tear the lower lip, when inadvertently slipping from the segment, because the tip is blunt (Fig 4). We operated on 12 patients with this device and the important point was the comfortable handling of the device without worry about damaging the patient's lower lip. It is recommended to operation with the least complication, pay attention to the design of this device and replace the common bone hook.

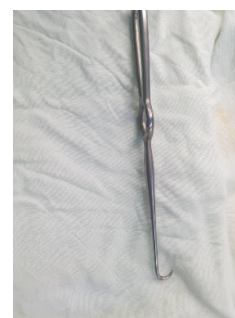


Fig 1. Volkmann bone hook.

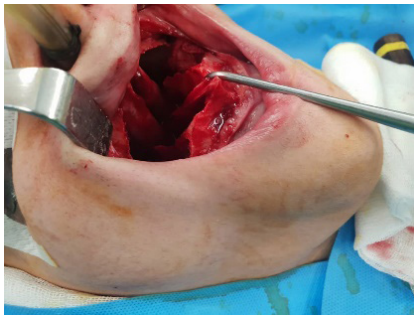


Fig 2. Bone hook placement and possible pressure on the lower lip.



Fig 3. New design of bone hook.

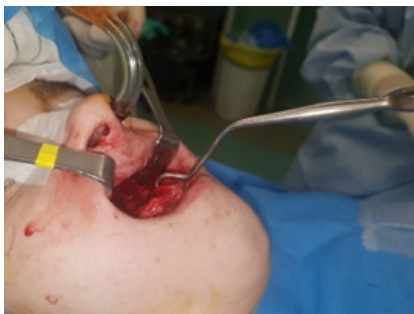

Fig 4. Apply a new bone hook.

### Conflict of Interest

There is no conflict of interest to declare.

### References

- [1] Rainer.B. The history of the “Le Fort I osteotomy”. Journal of maxillofacial surgery. 1986; 14(2):119-22.
- [2] Cheever D: Naso-pharyngeal polypus, attached to the basilar process of occipital and body of sphenoid bone successfully removed by a section, displacement, and subsequent replacement and re-union of the superior maxillary bone, Boston Med Surg J. 1867.1(8):408-13.
- [3] Peter V Deyer. Experimental study of fractures of the upper jaw: a critique of the original papers published by René Le Fort. 1999; 1(1): 81-4.

- [4] Richard E, Mark W: Maxillary Orthognathic Surgery. Oral and Maxillofacial clinics. 2014; 26(4): 523-37.
- [5] Willmar K: On Le Fort I osteotomy: a follow-up study of 106 operated patients with maxillo-facial deformity, Scand J Plast Reconstr Surg. 1974; 12 (Suppl 12):11-68,
- [6] Obwegeser HL: Surgical correction of small or retrodisplaced maxillae. The “dish-face” deformity, Plast Reconstr Surg 1969; 43 (4):351-65.
- [7] Bell WH: Biologic basis for maxillary osteotomies. Am J Phys Anthropol. 1973; 38(2):279-89.
- [8] Buchanan EP, Hyman CH: LeFort I osteotomy. Semin Plast Surg. 2013; 27(3):149-54.
- [9] Raymond J. Fonseca, Marciani R.D, Turvey T.A. Oral and maxillofacial surgery, 3rd Edition, Vol III, Chap.9, pp.154, St. Louis: Missouri Elsevier:2018
- [10] Raymond J. Fonseca, Marciani R.D, Turvey T.A. Oral and maxillofacial surgery, 3rd Edition, Vol III, Chap. 9, pp.161-7, St. Louis: Missouri Elsevier: 2018.

*Please cite this paper as:*

Mahmood Hashemi H, Razmara F; New design of bone hook for lefort I osteotomy. J Craniomaxillofac Res 2021; 8(1): 35-37