



## Denosumab, an adjunctive method in central giant cell granuloma treatment: A case report

Akbar Rezaie<sup>1</sup>, Zahra Dalili Kajan<sup>2</sup>, Donya Maleki<sup>3</sup>, Reza Shokuhi Fard<sup>1</sup>, Hadi Golshekan<sup>1\*</sup>

1. Department of Oral and Maxillofacial Surgery, Faculty of Dentistry, Guilan University of Medical Sciences, Rasht, Iran.

2. Department of Maxillofacial Radiology, Faculty of Dentistry, Guilan University of Medical Sciences, Rasht, Iran.

3. Student Research Committee, Faculty of Dentistry, Guilan University Of Medical Sciences, Rasht, Iran.

### ARTICLE INFO

#### Article Type: Case Report

Received: 8 Jun. 2021

Revised: 1 Jul. 2021

Accepted: 11 Aug. 2021

#### \*Corresponding author:

Hadi Golshekan

Department of Oral and Maxillofacial Surgery,  
Faculty of Dentistry, Guilan University of Medical  
Sciences, Rasht, Iran.

Tel: +98-21-84902473

Fax: +98-21-84902473

Email: hadigolshekan94@Gmail.com

### ABSTRACT

Central giant cell granuloma (CGCG) is a benign intraosseous pathology. A 17 years old male patient was referred and diagnosed with CGCG from mandibular right first molar to mandibular left second premolar. Enucleation and curettage of the lesion were completed as the main treatment. Involved teeth on the right, 41, 42, 43, 44, and 45 (FDI) were extracted. As adjunctive therapy, 120 mg Denosumab was injected subcutaneously. The patient received sixteen sessions of therapy through 11 months. Two, sixteen, and eighteen months follow-up after the first session of injection showed an acceptable improvement in bone contour. The patient experienced no functional or aesthetic impairment. Alongside the promising results of Denosumab as adjunctive therapy in the management and treatment of diseases such as CGCG, some questions have remained unanswered and no protocol has been determined. The authors of the current study recommend further researches to confirm Denosumab as a potential adjunctive or alternative in the treatment of CGCG.

**Keywords:** Central giant-cell granuloma; Denosumab; Follow-up; Mandible.

### Introduction

Central giant cell granuloma (CGCG) is a benign intraosseous pathology that comprises 7% of non-neoplastic lesions and 0.1% of tumors in the craniofacial [1–3]. CGCG has a greater tendency to appear in the mandible compared to the maxilla. However, the lesion causes greater expansion in the maxilla compared to the mandible as the maxillary bone is more spongy and the mandibular bone is more cortical [4–6]. CGCG

is mostly found in the first, second, and third decades of life and shows a female predilection. The male-female ratio is 1:2 [2,7–9]. CGCG is frequently reported in the anterior segments of the jaw if occurred in the maxilla. In the mandible, CGCG may appear equally in the anterior and posterior segments of the jaw. The lesion sometimes crosses the midline [9–13]. The pathology is categorized as a non-aggressive and aggressive form. The non-aggres-

aggressive form. The non-aggressive lesion mostly has the following characteristics; grows slowly, is asymptomatic, does not perforate cortical bone, does not displace involved teeth, does not resorb involved roots, is smaller than 5mm, and after proper treatment, the recurrence of the lesion is often low. Unlike the non-aggressive lesion, the aggressive form of CGCG is more likely to grow rapidly, have symptoms, cause paresthesia, and aggressively destruct the surrounding structures such as perforating the cortical bone, displacing the involved tooth, and resorbing the roots. The aggressive CGCG lesion usually has a higher recurrence rate after the treatment [14–16]. Although the pathogenesis and etiology of CGCG are not clearly explained, its clinical, radiographical, and histological characteristics are as following [17]. As CGCG has a vascular origin, the lesion appears to be a dark brown non-calcified mass clinically. The lesion tends to cause swelling, asymmetry and bleeding. Expansion is often seen in CGCG patients [8,10,18].

Radiographically, CGCG has no pathognomonic appearance and may vary from a small unilocular lesion to a large multilocular pathology. CGCG is a radiolucent defect with margins that can be well-defined, poorly defined, or diffused. The differentiation of CGCG from per-apical granuloma or cysts is difficult if the CGCG lesion is small and unilocular. Also, ameloblastoma, OKC, and CGCG can be confusing when the CGCG lesion is multilocular [1,10,16,19,20]. Histopathological findings of CGCG show fibrous tissue with multiple foci of hemorrhage, multinuclear giant cell aggregations, and occasionally trabeculae of bone. The histopathological appearance of aggressive and non-aggressive are similar [8,12]. The case presented in the current study is about the treatment of a young boy diagnosed with CGCG in the mandible and treated with Denosumab.

## Case Report

A 17 years old male patient was referred to the dental faculty with tenderness, swelling in the right mandibular region, and paresthesia of the right segment of the lower lip (Fig 1). The swelling could be found extra-orally causing facial asymmetry and intraorally in the buccal and lingual aspects of the alveolar ridge. The lesion was covered with a pink and firm mucosa, was soft and consistent in touch, nonmobile, non-compressible, non-fluctuance, was extended from the right mandibular first premolar to the right mandibular first molar surrounding right mandibular second premolar, and had displaced adjacent teeth clinically (Fig 2). A

diagnosis of CGCG was considered based on clinical findings.

## Radiographic Findings

Radiographs revealed a radiolucent pathology from mandibular right first molar to mandibular left second premolar crossing the midline (Fig 3-6). In the radiographic assessment, it was found that the lesion had destructed the anterior and posterior mandibular right cortex, while the lesion did not perforate the labial and lingual plates on the left mandible and midline. The borders of the lesion were lobular and no sclerotic margin was reported in the radiography. The lesion had displaced 43 and 44 teeth (FDI) and had resorbed the roots of 43, 44, and 45 teeth (FDI) (Fig 3-6). Diagnosis of ameloblastoma, odontogenic myxoma, and CGCG was considered according to radiographic findings.

## Paraclinical Findings

A whole-body bone scan and SPECT were requested. The bone scintigraphy was performed 3 hours after IV administration of 20mci Methylene Diphosphate radiotracer (Tc99m-MDP) in body and multiple spot views. No abnormal tracer uptake had been seen through-out the skeletal system including the mandibular condyle. The body bone scan was normal and clear of any active bony lesion. The diagnosis of giant cell tumor was excluded (Fig 7). Laboratory tests revealed that the calcium and phosphorus of the patient were normal and were respectively 9.5mg/dL (8.4-10.2mg/dL) and 3.2mg/dL (2.7-4.9mg/dL). The hormone analysis showed that the patient's parathyroid hormone was 55pg/ml which was higher than the normal range (6.5-36.8pg/ml). The laboratory test ruled out the possibility of hyperparathyroidism. Other laboratory results are presented in Fig 8.

Aspiration and incisional biopsy were carried out. Histopathology assessment showed numerous osteoclast like giant cells, cellular highly vascularized stroma, hemorrhage, and hemosiderin laid down macrophages which were covered by hyperplastic squamous epithelium, no evidence of malignancy was found in the specimen. A possible diagnosis was CGCG according to histopathological evaluation (Fig 9).

## Diagnosis

The clinical, radiographic, and laboratory features confirmed the diagnosis of CGCG.

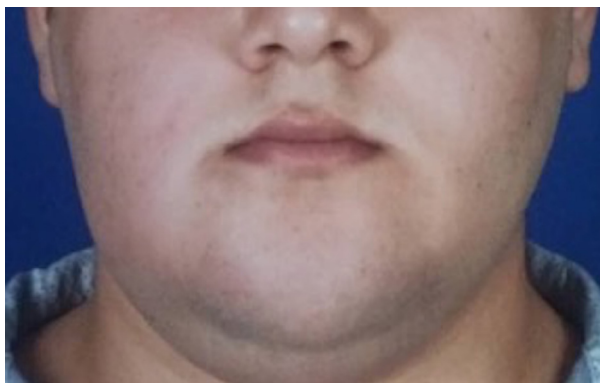## Treatment

Enucleation and curettage of the lesion were complet-

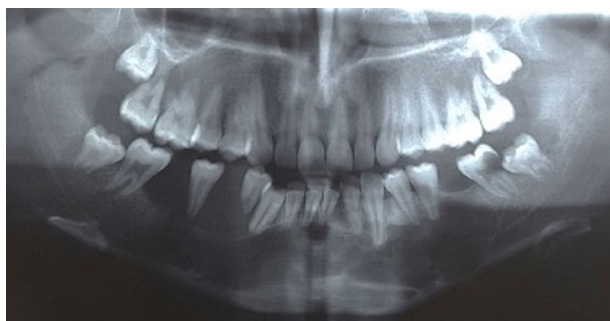ed in February 2017 as the main treatment. Involved teeth, 41, 42, 43, 44 and 45 (FDI) were extracted. As adjunctive therapy, 120mg Denosumab was injected subcutaneously. The injection was started in November 2017 and was finished in October 2018 after sixteen sessions of therapy. In the first two weeks, the patient received Denosumab twice a week and for the next two weeks, he received one injection of Denosumab per week. Over the next ten weeks, Denosumab was injected into the lesion once every month.

**Follow up**

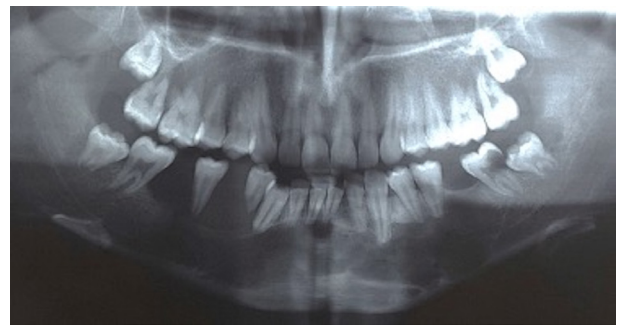The first follow-up was in January 2018, two months after the first injection of Denosumab (Fig 10). The second follow-up was sixteen months after the first injection of Denosumab in March 2019 (Fig 11-12). Radiographically and clinically, a reduction in the size of the lesions had been seen. The third follow-up was eighteen months after the first injection of Denosumab in May 2019 (Fig 13). Clinical and radiographic evaluations revealed an acceptable improvement in bone contour. The patient experienced no functional or aesthetic impairment.



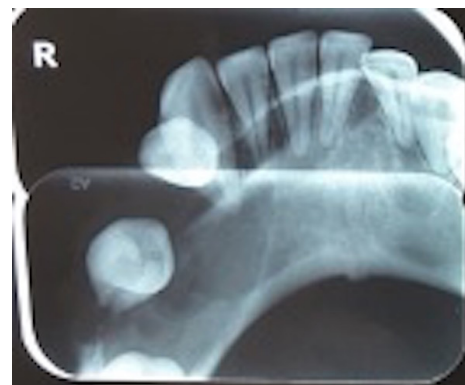*Figure 1.*



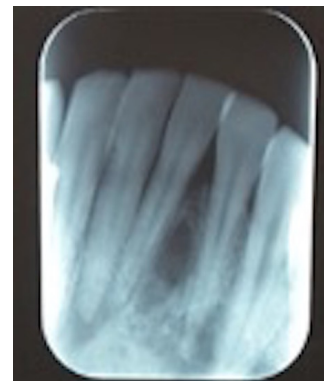*Figure 2.*



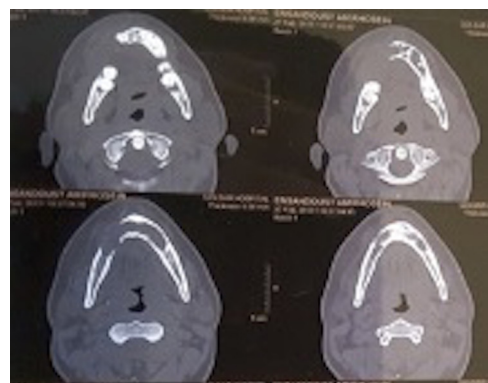
*Figure 3.*



*Figure 4.*



*Figure 5.*



*Figure 6.*




Figure 7.

TEST	Result	Unit	Normal Range
Alkaline Phosphatase	264	U/L	up to 38 years 80-1200 male 65-200 female 64-200
SGOT (AST)	20	U/L	up to 37
Calcium	9.7	mg/dL	8.5-10.3
Phosphorus	3.2	mg/dL	1-1.8 years 2.7-6 Adult 2.5-4.5
BUN	11	mg/dL	6-21
Creatinine	1	mg/dL	0.7-1.4
Fasting Blood Sugar	100	mg/dL	70-100
<b>Hematology - Blood Cell Analysis</b>			
TEST	Result	Unit	Normal Range
Complete Blood Count	-	TT	-
WBC Count	9.3	10 <sup>3</sup> /UL	4.5-11.0
RBC Count	5.51	10 <sup>6</sup> /UL	3.8-5.3
Hb	14.8	g/dL	10-15
Hematocrit	48.2	%	20-45
MCV	83.9	fL	80-100
MCH	28.8	pg	27-32
MCHC	32.8	g/dL	28-35
Platelet	301	10 <sup>3</sup> /UL	150000-400000
Neutrophil	68	%	34-64
Lymphocyte	28	%	25-45
Monocyte	4	%	1-6
Eosinophil	2	%	0-3
<b>Hematology - Coagulation</b>			
TEST	Result	Unit	Normal Range
Prothrombin Time (PT)	12	sec	11-13
Control PT	12	sec	12
INR	1		1-1.2
Partial Thromboplastin Time (PTT)	28	sec	25-35

Figure 8.

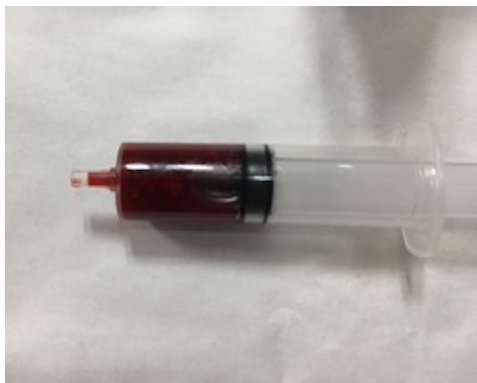

Figure 9.

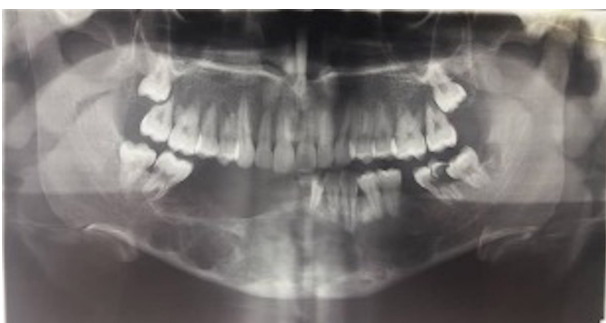

Figure 10.

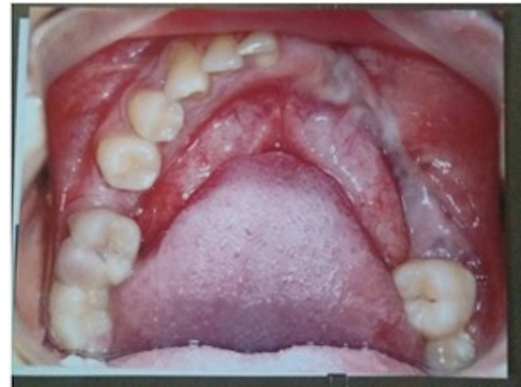

Figure 11.

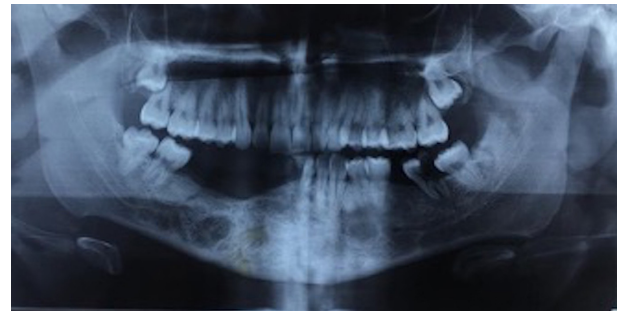


Figure 12.

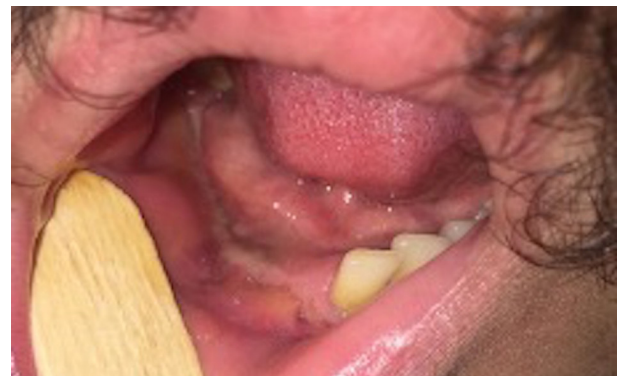

Figure 13.

## Discussion

Current treatments for CGCG are curettage, en-bloc resection, intralesional corticosteroid therapy, or antiangiogenic therapy [10,21]. Although curettage is the common treatment of CGCG lesions, its recurrence rate is high ranging from 49% to 72% especially when performed alone [10,21]. Through the en-bloc resection, the tumor is removed completely with a continuous margin of healthy and intact tissue. En-bloc resection offers the best chance for a full recovery; however, it is often unacceptable for causing functional loss, postoperative bleeding, and decreasing esthetics [10]. Also, this method is not always possible to perform especially if the lesion is close to a neural structure [22]. Intralesional corticosteroid therapy is a safe and effective treatment for CGCG, however,

some complications have been reported such as pain, hemorrhage, ulceration, atrophy, hyperpigmentation, hypopigmentation, or complete depigmentation [21]. Denosumab is a monoclonal antibody and a potential treatment for osteoclast overactivity diseases. Some of the previous studies have used Denosumab as adjunctive therapy to decrease the recurrence rate of CGCGs treated with curettage [8,11]. Naidu et al. reported 2 cases diagnosed with CGCG in their mandibles. The patients were treated with monthly subcutaneous injections of Denosumab 120mg. After a 24-month follow-up and 15-month follow-up for the first and second cases respectively, CGCG was completely treated and no recurrent lesion was reported. During the treatment, the bone contour and the facial asymmetry were improved. They concluded that Denosumab may be an alternative or adjunctive procedure for the treatment of patients with CGCGs however, clinical studies are awaited to assess the recurrence rate after discontinuation of denosumab [23].

Rytkönen et al., reported 2 cases of CGCG who were sisters. The first case was a 27 years old female diagnosed with CGCG in the left mandible site involving teeth 33 and 34 (FDI). The lesion was removed with curettage. However, after a year, two recurrent lesions were found in the mandible. Removal of the lesions and involved teeth were performed. After 6 months, new lesions were found in the maxilla. At this point, Rytkonen et al. decided to treat the patient with 3 subcutaneous injections of 120mg denosumab. (one injection per month). The 3.5 years follow-up revealed no recurrent lesion. The second case was a 29 years old female with 2 separate lesions in the maxilla (involving right maxillary canine) and mandible (involving teeth 44,45,46 and 47 (FDI)). The lesions were completely removed with curettage and considering the aggressive CGCG of the first patient, a similar treatment protocol was prescribed for the second patient. The authors decided to inject 3 doses of 120mg of Denosumab subsequently for the patient. No recurrent lesion was found during the 4-year follow-up. Although the results of the studies were promising, the authors stated that more studies were required to provide more insight and knowledge [24]. Upfill-Brown et al. treated a mandibular CGCG lesion with Denosumab in a 14 years old male. The patient received 15 doses of 120mg Denosumab monthly over a year. The patient had an excellent clinical and radiological response and experienced no complications. The result of their study concluded that Denosumab was an effective treatment in the management of CGCG, however, further stud-

ies were recommended [9]. In the current study, the patient was treated with curettage along with Denosumab to prevent recurrent lesions. The 3 years follow-up showed that the treatment was effective and no recurrent lesion was found. The patient's bone had been recovering through the follow-up sessions. And the patient did not experience any discomfort.

Alongside the promising results of Denosumab as adjunctive therapy in the management and treatment of diseases such as CGCG, some questions have remained unanswered and no protocol has been determined. For example, it has been claimed that Denosumab does not incorporate into the bone matrix. For that reason, its effects may be reversible and the stability of the results from the treatment with Denosumab needs to be followed up for a longer period [3]. Denosumab may be associated with the risk of osteonecrosis of the jaws at 0.001%–0.01% of cases [25]. This risk needs to be further studied in future researches. No clinical trials of Denosumab in the treatment of CGCG have been published up to date. The authors of the current study recommend further researches to confirm Denosumab as a potential adjunctive or alternative in the treatment of CGCG.

## Conflict of Interest

There is no conflict of interest to declare.

## References

- [1] Choe M, Smith V, Okcu MF, Wulff J, Gruner S, Huisman TAGM, et al. 2021 Treatment of central giant cell granuloma in children with denosumab. *Pediatr Blood Cancer*. 68:10?3.
- [2] De Mendonça RP, Mitre GP, Real FH, da Silva Kataoka MS, de Melo Alves Júnior S, Vianna P, et al. 2020 Central Giant Cell Granuloma Treated with Intralesional Corticosteroid Injections and Bisphosphonates: A Long-Term Follow-Up Case Study. *Head Neck Pathol [Internet]*.14:497?502. Available from: <https://doi.org/10.1007/s12105-019-01053-x>.
- [3] Everts-Graber J, Reichenbach S, Gahl B, Ziswiler HR, Studer U, Lehmann T. 2021 Risk factors for vertebral fractures and bone loss after denosumab discontinuation: A real-world observational study. *Bone*. 144:115830. Available from: <https://doi.org/10.1016/j.bone.2020.115830>.
- [4] Van der Heijden L, Dijkstra S, van de Sande M,

- Gelderblom H. 2020 Current concepts in the treatment of giant cell tumour of bone. *Curr Opin Oncol.* 32:332-338.
- [5] Jiang T, Mao Y, Ma W, Mao Q, You Y, Yang X, et al. 2016 CGCG clinical practice guidelines for the management of adult diffuse gliomas. *Cancer Lett.* 375:263-273. Available from: <http://dx.doi.org/10.1016/j.canlet.2016.01.024>
- [6] Shrestha S, Zhang J, Yan J, Zeng X, Peng X, He B. 2021 Radiological features of Central Giant Cell Granuloma: Comparative study of 7 case reports and literature review. *Dentomaxillofac radiol.* 50:1-14.
- [7] Muramatsu K, Tani Y, Seto T, Roces G, Yamamoto M, Ichihara Y, et al. 2020 Two cases with giant cell tumor arising from the sternum: Diagnosis and options for treatment. *J Orthop Sci.* 19:10-15. Available from: <https://doi.org/10.1016/j.jos.2019.10.014>
- [8] Elmezwghi AM, Alarabi NM, Elsagali AH, Zariba SS, BenGharbia NE MN. 2020 an aggressive central giant cell granuloma of the maxilla: diagnostic dilemma, precise differential diagnosis and successful traditional surgical approach: a case report. *Egyptian Dent J.* 66:2075-2083.
- [9] Upfill-Brown A, Bukata S, Bernthal NM, Felsenfeld AL, Nelson SD, Singh A, et al. 2019 Use of Denosumab in Children With Osteoclast Bone Dysplasias: Report of Three Cases. *JBMR Plus.* 3:1-7.
- [10] Lipplaa A, Dijkstra S, Gelderblom H. 2019 Challenges of denosumab in giant cell tumor of bone, and other giant cell-rich tumors of bone. *Curr Opin Oncol.* 31:329-335.
- [11] Nasir U, Maryam B, Marwat T, Nausheen N. 2019 Clinical and Radiographic Presentation of Central Giant Cell Granulomas of Jaws. *Khyber Med Univ J.* 11:231-235.
- [12] Scoccianti G, Totti F, Scorianz M, Baldi G, Roselli G, Beltrami G, et al. 2018 Preoperative denosumab with curettage and cryotherapy in giant cell tumor of bone: Is there an increased risk of local recurrence? *Clin Orthop Relat Res.* 476:1783-1790.
- [13] Dds SS, Dds RF. 2009 Archive of SID Central Giant Cell Granuloma: endodontic misdiagnosis Archive of SID. 4:158-160.
- [14] Jadu FM, Pharoah MJ, Lee L, Baker GI, Allidina A. 2011 Central giant cell granuloma of the mandibular condyle: A case report and review of the literature. *Dentomaxillofac Radiol.* 40:60-64.
- [15] Bredell M, Rordorf T, Kroiss S, Rucker M, Zweifel DF, Rostetter C. 2018 Denosumab as a Treatment Alternative for Central Giant Cell Granuloma: A Long-Term Retrospective Cohort Study. *J Oral Maxillofac Surg.* 76:775-784. Available from: <https://doi.org/10.1016/j.joms.2017.09.013>
- [16] Atarbashi Moghadam S, Ghorbanpour M. 2017 Central Giant Cell Granuloma of the Jaws: Correlation between Vascularity and Biologic Behavior. *J Dent Mater Tech.* 6:35-39.
- [17] Motamedi MHK, Eshghyar N, Jafari SM, Lassemi E, Navi F, Abbas FM, et al. 2007 Peripheral and central giant cell granulomas of the jaws: A demographic study. *Oral Surg, Oral Med Oral Pathol Oral Radiol Endodontol.* 103:39-43.
- [18] Palmerini E, Chawla NS, Ferrari S, Sudan M, Picci P, Marchesi E, et al. 2017 Denosumab in advanced/unresectable giant-cell tumour of bone (GCTB): For how long? *Eur J Cancer.* 76:118-124. Available from: <http://dx.doi.org/10.1016/j.ejca.2017.01.028>
- [19] Tenore G, Palaia G, Capocci M, Impellizzeri A, Romeo U. 2014 The central giant cells granuloma of the mandible : a report of two cases and a review of the literature. *Senses Sci.* (1):30-38.
- [20] Kim TS, Usera GL, Ruggiero SL, Weinerman SA. 2017 Improvement of Giant Cell Lesions of the Jaw Treated With High and Low Doses of Denosumab: A Case Series. *JBMR Plus.* 1:101-106.
- [21] De Lange J. UvA-DARE (Digital Academic Repository) 2006 Central giant cell granuloma of the jaw: epidemiology, therapy and related disorders. Elsevier. Available from: <http://dare.uva.nl>
- [22] Afsoun S, Saied S, Amir N, Hamed J. 2018 En-bloc resection of a giant cell tumor causing cervical vertebral collapse. *Asian J Neurosurg.* 13:150-153. Available from: <https://pubmed.ncbi.nlm.nih.gov/35820874/>
- [23] Naidu A, Malmquist M, Denham CA, Schow SR. 2014 Management of central giant cell granuloma with subcutaneous denosumab therapy. *J Oral Maxillofac Surg.* 72:2469-2484. Available from: <https://www.sciencedirect.com/science/article/pii/S027823911401115X>.

- [24] Rutkowski P, Gaston L, Borkowska A, Stacchiotti S, Gelderblom H, Baldi GG, et al. 2018 Denosumab treatment of inoperable or locally advanced giant cell tumor of bone–Multicenter analysis outside clinical trial. *Eur J Surg Oncol*. 44:1384?1390. Available from: <https://doi.org/10.1016/j.ejso.2018.03.020>.
- [25] Reid R, Ruggiero SL. 2017 Case-Based Review of Osteonecrosis of the Jaw (ONJ) and Application of the International Recommendations for Management From the International Task Force on ONJ. *J Clin Densitom Assess Manag Musculoskelet Heal*. 10:8?24. Available from: <http://dx.doi.org/10.1016/j.jocd.2016.09.0058>

*Please cite this paper as:*

Rezaie k, Dalili Kajan Z, Maleki D, Shokuhi Fard R, Golshekan H; Denosumab, an adjunctive method in central giant cell granuloma treatment: A case report. *J Craniomaxillofac Res* 2021; 8(4): 220-226