



Effects of FGF on tooth movement and root resorption

Masood Feizbakhsh ¹, Sayed Mohammad Razavi ², Valiollah Hajhashemi ³, Mahsa Mortazavi ^{4*}

1. Department of Orthodontics, School of Dentistry, Islamic Azad University, Isfahan (Khorasgan) Branch, Isfahan, Iran.

2. Dental Implant Research Center, Dental Research Institute, Isfahan University of Medical Sciences, Isfahan, Iran; Department of Oral and Maxillofacial Pathology, School of Dentistry, Isfahan University of Medical Sciences, Isfahan, Iran.

3. Department of Pharmacology and Isfahan Pharmaceutical Sciences Research Center, School of Pharmacy and Pharmaceutical Sciences, Isfahan University of Medical Sciences, Isfahan, Iran.

4. Department of Orthodontics, Arthur A. Dugoni School of Dentistry, University of the Pacific, San Francisco, USA.

ARTICLE INFO

Article Type: Original Article

Received: 2 Feb. 2021

Revised: 16 Apr. 2020

Accepted: 2 Jun. 2021

*Corresponding author:

Mahsa Mortazavi

University of the Pacific, Arthur A. Dugoni School of Dentistry, 155, Fifth Street, San Francisco, USA, CA 94103.

Tel: +1-51-04233832

Fax: -----

Email: m_mortazavi@U.pacific.edu

ABSTRACT

Introduction: Basic fibroblast growth factor (bFGF) is an effective cytokine in angiogenesis and bone remodeling. The aim of this study was to determine the effect of locally injected bFGF on movement rate and root resorption during orthodontic force application in dogs.

Materials and Methods: In this experimental animal study, four 10-12 months male dogs were selected and were randomly allocated into two groups. A week following insertion of closing coil spring between the canines and second premolars, 50µg of bFGF was injected to the case group and phosphate saline to the control group once per month. One month after second injection, the distance between the mentioned teeth were measured. Also, root resorption percentage were analyzed on the second premolars.

Results: Average maxillary tooth movement rate in case and control groups were found 2.53 and 1.35mm/month respectively. The correspondent mandibular measures were 2.23mm and 1.15mm. These differences were statistically significant ($P < 0.0001$). In respect to root resorption, the differences were found statistically significant ($P < 0.01$) for coronal region in maxilla, which was higher in control group. Regarding the apical and middle regions of both jaws as well as coronal region of mandible the differences were insignificant.

Conclusion: The results of the study showed that the local injection of bFGF can increase tooth movement rate and has the potential to decrease root resorption during orthodontic tooth movement in dogs.

Keywords: Tooth movement; Root resorption; Fibroblast growth factor.

Introduction

Orthodontic treatment is associated with undesirable side effects such as root resorption, pain, pulp changes, temporomandibular joint disorder and periodontal diseases aside from its main expected results [1,2]. Root resorption depends on factors such as the

amount and type of applied orthodontic forces, the duration of orthodontic treatment, root morphology, biological and genetic factors, ethnicity and health status of the patient [3-5]. The rate of tooth movement is another main concern of orthodontists. High rate of tooth movement

reduces the duration of treatment as well as the side effects of treatment, most importantly root resorption [1]. Bone remodeling is a major cause of tooth movement through a sterile inflammatory process (hyalinized tissue) which is initiated, stimulated and developed by orthodontic forces [6-8]. Cellular activity following removal of this layer of hyalinized necrosis tissue can also affect the root cellular layer and make an easily absorbable root surface [9,10]. On the other hand, in the repair process, the extracellular membrane adjacent to PDL cells plays an important role in tissue regeneration. In fact, signals released from the extracellular matrix along with growth factors can lead to the stimulation, proliferation, and differentiation of stem cells and ultimately tissue rearrangement [11].

A number of researches have been conducted on the effects of stimulatory signals such as Bone Morphogenic Protein (BMP), Fibroblast Growth Factor (FGF) and Osteogenic Protein on periodontium regeneration [12-14]. Murakami et al. showed new bone formation beside PDL and cementum achievement in comparison to control group following application of recombinant basic fibroblast growth factor (rbFGF) on artificial bone defects in dogs and primates [12]. Also, according to some previous studies, BMP and enamel derived proteins have positive effects on periodontal tissues and cementum remodeling processes [13,14]. Basic fibroblast growth factor (bFGF) is a polypeptide of fibroblast growth factor category. This molecule acts in immigration and proliferation of endothelial cells as well as vasculogenesis and bone remodeling [15,16]. Additionally, improving blood perfusion and healing, controlling and forming bone mass, increasing osteoclasts, decreasing collagen type I and activating alkaline phosphatase are listed as functions of this growth factor [17].

One of the important goals of orthodontic treatment is to improve oral health. Prolonged treatment time will result in increasing treatment side effects such as root resorption, enamel decalcification and periodontal diseases. As a result, it is important to identify a factor that can help to reduce treatment time as well as root resorption. The aim of this current study was to determine the effect of locally injected fibroblast growth factor on tooth movement rate and root resorption caused by orthodontic force application in dogs.

Material and Methods

Experimental animals: This experimental study was performed on four 10-12 months old male dogs in

equal situation. The dogs were randomly divided into two groups: group A as control and group B as the case group receiving bFGF (2 dogs in each group). As the orthodontic appliances were placed in all four quadrants, 8 study sites were allocated to each group.

Experimental Description: Since first premolars in dogs have short and thin roots, second premolars were considered as movement unit and long rooted canine teeth as anchorage unit. After confirming the health of periodontal tissues via periapical radiographs, first premolars were extracted due to proximity to the second premolars and risk of intervention with tooth movements. For relative healing in the local region, dogs were kept in standard situation for a month. The designed orthodontic appliance including two loops made by ligature ties 0.014 inch (Ortho Technology, Wesley Chapel, Florida, USA) was inserted under general anesthesia around second premolar and canine teeth and were fixed by resin composite (GC America Inc, Illinois, USA) to avoid extra movements. Closing coil springs with eyelets (size 12 F, G & H Orthodontics, Indiana, USA) were used to apply 200g force between the teeth (Fig 1). Then, the distance between points on the distal of canine to the mesial of second premolar (pre-marked by bur) were measured via digital caliper (1108-150 Electronic Caliper, InSize, Suzhou New District, China).

During the study period, in order to avoid deformation or movement of orthodontic appliances, dogs' diet was limited to soft food. After a week of daily assessment of dogs, injections were initiated. Group A which was considered as the control group, received one milliliter of buffered phosphate saline monthly (twice in two months). For the case group of B, 50µg of bFGF (Pasteur Institute, Tehran, Iran) in one milliliter of solution was injected. All the injections were done in both maxilla and mandible by insulin syringe through a small hole made in alveolar bone, located between second premolar roots (Fig 1). According to the previous similar study, the selected dose of growth factor was 30µg in every region [12]. As contrary to Murakami's study, the carrier in the present study was not used and the growth factor could be easily dissipated, 50µg was injected to the control group. The dogs were sacrificed one month after the second injection and the distance between the second premolars and the canines were measured following appliance removal. Also, the second premolars with surrounding bone were removed for histological analysis. Root resorption zones (in coronal, middle and apical regions) were divided into total root area and recorded as percentage

of root resorption. This calculation was done by using Nilu software (Nilu pathology image analyzer, Iran). This procedure was done by a pathologist and the measures were repeated twice with the interval of 4 weeks. All the processes in present study including radiography were done under general anesthesia and intubation. Anesthesia was initiated by intramuscular injection of ketamine hydrochloride (20mg/kg Rumpun, Bayer, Seul, Korea) and acepromazine (0.02mg/kg At-ravet, Ayerst, Monteval, Quebec) and it was then continued by using 2-3% Halothane gas (Halothane BP, Cambridge, Ontario, Canada) until anesthesia symptoms appeared.

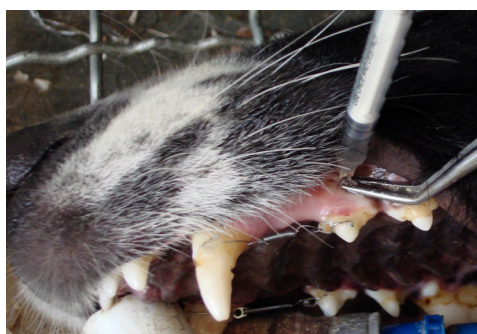

Fig 1. Injection in maxillary arch with orthodontic appliance.

Statistical Analysis

Obtained data were analyzed using the SPSS (SPSS Inc., Chicago, IL, USA) version 22.0, Chi-square and independent t-test. A P value less than 0.05 was considered statistically significant.

Results

Effect of bFGF on the amount of tooth movement: The obtained results showed the average rate of tooth movements in upper jaw of the dogs in control and case groups were 1.35 ± 0.07 and 2.53 ± 0.09 mm per month. The difference was statistically significant ($p < 0.0001$). Likewise, the average rate of mandibular tooth movements were measured 1.15 ± 0.04 and 2.23 ± 0.06 mm per month in the control and case groups, respectively. Which was also statistically significant ($p < 0.0001$) (Table 1).

Effect of bFGF on root resorption: The average and distribution index of root resorption percentage of apical, middle and coronal sections of root in maxilla and mandible are shown in Table 2. Statistical analysis results indicated insignificant difference of root resorption percentage in apical and middle sections of maxilla and mandible as well as coronal section of mandible. The only section with a significant difference in root resorption percentage was the coronal third of maxil-

lary second premolars ($P < 0.01$). Control group showed significantly higher root resorption in comparison to the case group in Maxillary coronal sections (Figs. 2A and B).

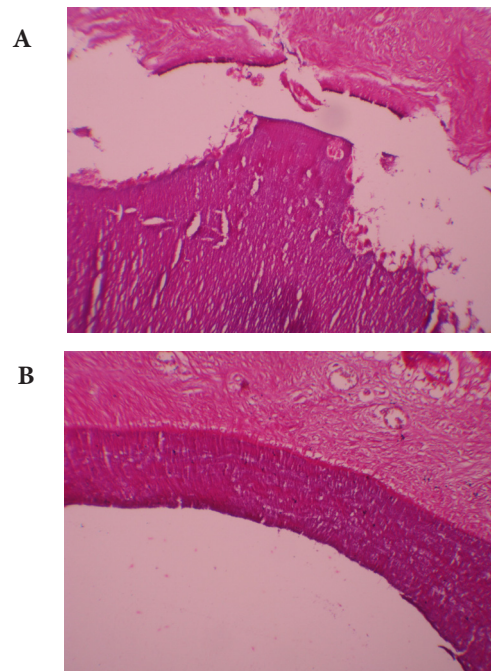


Fig 2. A) Coronal region of root without resorption. B) Apical region of root with resorption (H&E stain, x40, B:bone, PDL:periodontal ligament, D:dentin, C:pulp canal, R:root resorption).

Table 1. The mean, standard deviation, 95% confidence interval and P value of maxillary and mandibular tooth movement rate in study groups.

| Group | Mean (mm) | | SD | | 95% CI | | P Value |
|---------|-----------|----------|---------|----------|-----------|-----------|------------|
| | Maxilla | Mandible | Maxilla | Mandible | Maxilla | Mandible | |
| Control | 1.35 | 1.15 | 0.07 | 0.004 | 1.24-1.46 | 1.08-1.22 | $p<0.0001$ |
| bFGF | 2.53 | 2.23 | 0.09 | 0.006 | 2.38-2.68 | 2.13-2.33 | |

Table 2. The mean, standard deviation, 95% confidence interval and P value of maxillary and mandibular root resorption percentage in study groups.

| Region | Group | Mean | SD | CI 95% | P Value |
|---------------------------|---------|------|------|-------------|----------|
| Maxillary apical region | Control | 7.53 | 2.24 | 3.95-11.09 | $P=0.37$ |
| | bFGF | 4.88 | 3.47 | 0.65-10.4 | |
| Mandibular apical region | Control | 6.58 | 3.59 | 0.85-12.29 | $P=0.85$ |
| | bFGF | 5.4 | 0.57 | 0.32-10.48 | |
| Maxillary middle region | Control | 7.05 | 2.4 | 3.23-10.87 | $P=0.26$ |
| | bFGF | 3.0 | 3.83 | -3.09-9.09 | |
| Mandibular middle region | Control | 5.88 | 4.17 | -0.76-12.51 | $P=0.92$ |
| | bFGF | 6.0 | 3.5 | -2.69-14.69 | |
| Maxillary coronal region | Control | 7.75 | 1.94 | 4.67-10.83 | $P<0.01$ |
| | bFGF | 1.33 | 2.31 | -4.4-7.07 | |
| Mandibular coronal region | Control | 7.1 | 1.79 | 4.24-9.96 | $P=0.53$ |
| | bFGF | 6.58 | 3.34 | 1.27-11.88 | |

Discussion

bFGF or FGF-2 is a cytokine belongs to the growth factor superfamily and founds in many tissues of the body. Previously, bFGF was considered as mitotic factor of fibroblast cells but further researches revealed other characteristics such as stimulating angiogenesis, endothelial cells proliferation, tissue remodeling and wound healing, osteoblasts and osteoclasts proliferation and differentiation, calling macrophages, embryonic development and nervous cells apoptosis [18-21]. In our study, the results showed that the tooth movement in the study group was more than the control group. Similarly, Seifi et al. showed that in all rats injected with bFGF, the tooth movement rate was clearly higher [22]. In other study results showed that combined injection of bFGF and Insulin growth factor (IGF) caused significantly higher tooth movement than control group in 7th, 21th and 28th days of study [23]. Above-mentioned results are consistent with the results of our study. The reason of decreasing tooth movement after first phase of movement can be interpreted by the fact that blood vessels become occluded and sterile necrosis in the region under pressure ensures. Blood supply of periodontal ligament provides oxygen and

nutrition required for cellular activity in both physiological and pathological states. Obliteration of blood flow, necrosis and decreased tooth movement under light or heavy forces is inevitable [9,10]. Therefore, if an angiogenesis stimulating factor inhibits necrosis or at least limits its duration in periodontal ligament, then we expect limited or no delay phase of tooth movement and increased tooth movement rate. The other reason can be the ability of bFGF to induce macrophages and secondary messengers and as a result, the orthodontic tooth movement can be initiated without any delay. Additionally, having potential of differentiating osteoblasts and osteoclasts and the important role of them in bone remodeling can increase tooth movement rate [18,20].

Liao et al. conducted a research on expression of bFGF in rabbits' periodontium under different orthodontic forces concluded that special amount of force is essential to express bFGF [24]. In addition, Tang et al. carried out a study to evaluate expression of bFGF in rat periodontium under orthodontic treatment and found higher amount of this factor on 10th and 14th days in case group compared to the control group [25]. Shiratani et al. studied the effects of local bFGF in root

resorption of delayed autotransplanted teeth in dogs and concluded that root resorption in groups treated by FGF-2 is significantly less than control group [26]. Similar findings were concluded in our study. There were not significant differences between the two groups in most regions. This can be due to the amount of applied force (light continuous force), relatively short duration of force application and finally the type of tooth movement (tipping, which does not predispose the tooth to root resorption) [27].

We found significantly less root resorption in bFGF group in coronal region of maxillary teeth. As the tooth movement type was tipping-which is resulted by a single force on tooth crown-the pressure on marginal area of the root would be greater and this could lead to root resorption. Therefore, bFGF can be regarded as a factor that can decrease root resorption caused by orthodontic treatment. Less root resorption with presence of bFGF can be due to its anti-necrotic activity. According to the study of Seifi et al. higher dosage of bFGF can decrease resorption lacunas in teeth which are not under any orthodontic treatment [22]. Besides, chemotactic factors, extracellular matrix, adhesion molecules and growth factors such as insuline-like growth factor 1 (IGF1), FGFs, epidermal growth factor (EGF), BMPs and transforming growth factor-beta (TGF-beta) which exist in cementum matrix can absorb and induce cementoblast cells and aid root repair. This can be considered as another reason for lesser root resorption in the groups received bFGF in comparison to the control group [28-32]. All cells of the body act intelligently to their surroundings. Molecular biology in response to this intelligence raises an important question that cells work their way through environmental stresses such as stress, lack of oxygen, lack of food, and so on. For example, in the absence of oxygen, cells alert and release the hypoxia-inducible factor (HIF). This alert increases the expression and activation of various types of growth factors, including bFGF. bFGF expresses angiogenesis by binding to its cellular receptor and through a cascade pathway, everything is provided for cell adaptation and survival [33-40]. It seems that by increasing the concentration of mentioned factors in periodontal tissues, tissue remodeling rate and their regenerative potential are affected and likewise root resorption caused by orthodontic treatment can be decreased or eliminated.

Conclusion

Within limitation of this study, the results showed that bFGF can increase tooth movement and decrease root resorption during orthodontic tooth movement.

However, further studies are required on this subject for more clarification.

Conflict of Interest

There is no conflict of interest to declare.

References

- [1] Talic NF. Adverse effects of orthodontic treatment: A clinical perspective. *Saudi Dent J* 2011; 23(2):55-59.
- [2] Ramanathan C, Hofman Z. Root resorption in relation to orthodontic tooth movement. *ActaMedica (Hradec Kralove)* 2006; 49(2): 91-95.
- [3] Weltman B, Vig KW, Fields HW, Shanker S, Kaizar EE. Root resorption associated with orthodontic tooth movement: a systematic review. *Am J Orthod Dentofacial Orthop* 2010; 137(4): 462-476.
- [4] Kurol J, Owman-Moll P. Hyalinization and root resorption during early orthodontic tooth movement in adolescents. *Angle Orthod* 1998; 68(2): 161-165.
- [5] Owman Moll P, Kurol J. Root resorption after orthodontic treatment in high and low-risk patients: analysis of allergy as a possible predisposing factor. *Eur J Orthod* 2000; 22(6): 657-663.
- [6] Andrade Jr I, Taddei S, Souza P. Inflammation and Tooth Movement: The Role of Cytokines, Chemokines, and Growth Factors. *Seminars in Orthodontics* 2012; 18:257-269.
- [7] Krishnan V, Davidovitch Z. On a path to unfolding the biological mechanisms of orthodontic tooth movement. *Journal of Dental Research* 2009; 88:597-608.
- [8] Weiland F. External root resorption and orthodontic forces: correlations and clinical consequences. *Prog Orthod* 2006; 7(2):156-163.
- [9] Graber LW, Vanarsdall RL, Vig KW, Huang GJ. *Orthodontics Current Principle and Techniques*. 6th ed. Philadelphia: Elsevier; 2017. p. 60-64.
- [10] Proffit WR, Fields HW, Larson BE, Sarver DM. *Contemporary Orthodontics*. 6th ed. St. Louis: Elsevier; 2019. p. 269-271.

- [11] Ripamanti U, Reddi H. Tissue engineering, morphogenesis, and regeneration of the periodontal tissues by bone morphogenic proteins. *Crit Rev Oral Biol Med* 1997; 8(2):154-163.
- [12] Murakami S, Takayama S, Ikezawa K, et al. Regeneration of periodontal tissues by basic fibroblast growth factor. *J Periodontal Res* 1999; 34(7):425-430.
- [13] King GN, Hughes FJ. Bone morphogenic protein-2 stimulates cell recruitment and cementogenesis during early wound healing. *J Clin Periodontol* 2001; 28(5):465-475.
- [14] Mellonig JT, Valderrama P, Gregory HJ, Chocrane DL. Clinical and histologic evaluation of non-surgical periodontal therapy with enamel matrix derivative: a report of four cases. *J Periodontol* 2009; 80(9):1534-1540.
- [15] Qu D, Li J, Li Y, Gao Y, Zuo Y, Hsu J. Angiogenesis and osteogenesis enhanced by bFGF ex vivo gene therapy for bone tissue engineering in reconstruction of calvarial defects. *J Biomed Mater Res* 2011; 96(3):543-551.
- [16] Derringer KA, Linden RWA. Vascular endothelial growth factor, fibroblast growth factor 2, platelet derived growth factor and transforming growth factor beta released in human dental pulp following orthodontic forces. *Archives of Oral Biology* 2004; 49(8):631-641.
- [17] Sako E, Hosomichi J. Alteration of bFGF expression with growth and age in rat molar periodontal ligament. *Angle Orthod* 2010; 80(5):904-911.
- [18] Depprich AR. Biomolecule use in tissue engineering. 1st Ed. Berlin: Springer. 2009.p.121-135.
- [19] Williams WF, Larsen M, Friedrich PF, Shogren KL, Bishop AT. Induction of angiogenesis and osteogenesis in surgically revascularized frozen bone allografts by sustained delivery of FGF-2 and VEGF. *J Orthop Res* 2012; 30(10):1556-62.
- [20] Feito MJ, Lozano RM, Alcaide M, Ramirez-Santillan C, Arcos D, Vallet-Regi M. Immobilization and bioactivity evaluation of FGF-1 and FGF-2 on powdered silicon-doped hydroxyapatite and their scaffolds for bone tissue engineering. *J Mater Sci Mater Med* 2011; 22(2):405-416.
- [21] Okada-Ban M, Thiery JP, Jouanneau J. Fibroblast growth factor-2. *Int J Biochem Cell Biol* 2000; 32(3):263-267.
- [22] Seifi M, Badiei MR, Abdolazimi Z, Amdjadi P. Effects of basic fibroblast growth factor on orthodontic tooth movement in rats. *Cell Journal* 2013; 15(3):230-237.
- [23] Wu Lp, Liu Tt. Influence of combinative application of bFGF and IGF-1 upon periodontium remodeling in orthodontic tooth movement in rats. *Heilongjiang Medicine And Pharmacy* 2009; 29(32): 16-17.
- [24] Liao Z, Chung-Geng Z, Yin-Sheng M, Jun Z. Expressions of bFGF in rabbits' periodontium under different orthodontic forces. *Journal of Shandong University Health Sciences* 2010; 48(1):34-37.
- [25] Tang X, Liu J. Changes of basic fibroblast growth factor in periodontal tissue during orthodontic tooth movement in young rat. *Journal of Jinan University of Natural Science and Medicine* 2005; 26(6):760-765.
- [26] Shiratani S, Ota M, Fujita T, Seshima F, Yamada S, Saito A. Effect of basic fibroblast growth factor on root resorption after delayed autotransplantation of tooth in dogs. *Oral Surg Oral Med Oral Pathol Oral Radiol* 2012 Aug; 114(2):e14-21.
- [27] Acar A, Canyurek U. Discontinuous force application and root resorption. *Angle orthod* 1999; 69:159-63.
- [28] Brudvik P, Rygh P. Root resorption beneath the main hyaline. *Eur J Orthod* 1994 Aug; 16(4):249-263.
- [29] Grzesik WJ, Narayanan AS. Cementum and periodontal wound healing and regeneration. *Crit Rev Oral Biol Med* 2002; 13(6):474-484.
- [30] Bosshardt DD, Schroeder HE. Cementogenesis reviewed: a comparison between human premolars and rodent molars. *Anat Rec* 1996 June; 245(2): 267-292.
- [31] Gotz W, Lossdorfer S, Kruger U, Braumann B, Jager A. Immunohistochemical localization of

insulin-like growth factor-II and its binding protein-6 in human epithelial cells of Malassez. Eur J Oral Sci 2003 Feb; 111(1):26-33.

- [32] Feizbakhsh M, Mortazavi MS, Razavi SM, Hajhashemi V. The effects of local injection of simvastatin on tooth movement and root resorption rates under orthodontic forces in dogs. Biosciences, Biotechnology Research Asia. 2014; 11(2), 869–873.
- [33] Thom SR. Oxidative stress is fundamental to hyperbaric oxygen therapy. J Appl Physiol. 2009; 106(3):988-995.
- [34] Frantz S, Vincent KA, Feron O, Kelly RA. Innate immunity and angiogenesis. Circ Res. 2005; 96(1):15-26.
- [35] Fozen KM, Thom SR. Hyperbaric Oxygen, Vascularogenic Stem Cells, and Wound Healing. Antioxid. Redox Signal 2014; 21(11):1634–1647.
- [36] Giamarellos-Bourboulis EJ, Kanellakopoulou K, Pelekanou A, Tsaganos T, Kotzampassi K. Kinetics of angiopoietin-2 in serum of multi-trauma patients: correlation with patient severity. Cytokine. 2008; 44(2):310-313.
- [37] Du W, Hu JK, Du W, Klein OD. Lineage tracing of epithelial cells in developing teeth reveals two strategies for building signaling centers. J Biol Chem. 2017; 292(36):15062-15069.
- [38] Simon MP, Tournaire R, Pouyssegur J. The angiopoietin-2 gene of endothelial cells is up-regulated in hypoxia by a HIF binding site located in its first intron and by the central factors GATA-2 and Ets-1. J Cell Physiol. 2008; 217(3):809-818.
- [39] Maddaluno L, Urwyler C, Werner S. Fibroblast growth factors: Key players in regeneration and tissue repair. Development 2017; 144:4047-4060.
- [40] Kim R, Green JBA, Klein OD. From snapshots to movies: Understanding early tooth development in four dimensions. Dev Dyn. 2017; 246(6):442-450.

Please cite this paper as:

Feizbakhsh M, Razavi M, Hajhashemi V, Mortazavi M; Effects of FGF on tooth movement and root resorption. J Craniomaxillofac Res 2021; 8(3): 122-128