



Clinicopathological presentation of oral squamous cell carcinoma in Iraqi population

Bayad Jaza Mahmood ^{1*}, Ibrahim Saeed Gataa ², Umed Muhammad Mustafa ¹

1. Department of Oral and Maxillofacial Surgery, College of Dentistry, University of Sulaimani, Iraq.

2. Department of Oral and Maxillofacial Surgery, University of Warith Al-Anbiyaa, Iraq.

ARTICLE INFO

Article Type:
Original Article

Received: 2 Jan. 2021

Revised: 2 Mar. 2020

Accepted: 25 Jun. 2021

*Corresponding author:

Bayad Jaza Mahmood

Department of Oral and Maxillofacial Surgery, College of Dentistry, University of Sulaimani, Iraq.

Tel: 009647701955665

Fax: -----

Email: bayad.mahmood@Univsul.edu.iq

ABSTRACT

Background and Aim: Oral cancer is a major public health issue worldwide; it remains a highly lethal and disfiguring disease, it is primarily a disease of epithelial origin, it has various clinicopathological pictures. is to demonstrate various clinical and pathological presentations of oral squamous cell carcinoma in Iraqi population.

Materials and Methods: A total of 80 cases of histologically diagnosed squamous cell carcinoma collected from the main centers of Sulaymaniyah teaching hospital/Hiwa cancer center Hospital/Sulaymaniyah/Iraq were analyzed according to age, sex, site, clinical, and pathological presentation of oral squamous cell carcinoma at the time of presentation, and histological grading.

Results: Patients in their sixth decade of life were the most commonly affected with a male-to-female ratio of 1.4:1. The tongue was the most frequently affected site, followed by the floor of the mouth. The most common clinical presentation is ulceration and swelling. More than 40% of the cases were well-differentiated squamous cell carcinoma.

Conclusion: Oral cancer is increasingly seen as a major health problem, in line with the general trend in the region, the need for inter-professional health care delivery approaches for reducing oral cancer mortality and improving patients' quality of life.

Keywords: Squamous cell carcinoma; Oral cancer; Clinical presentation; Histopathology; Tumor grading.

Introduction

Oral cancer is a major public health concern worldwide, and it is still a lethal and disfiguring disease. It imposes significant responsibilities, problems, and a real opportunity to save lives on the entire dental team [1]. Oral cancer can be defined as a tumor involving the oral cavity, which begins at the lip and ends at the anterior pillar of the fauces [2]. Squamous cell carcinoma is the most frequent intraoral cancer. Complications often occur in the mouth either as a direct result of the malignancy or an unwanted treatment effect [3]. Oral cancer is the sixth most common cancer worldwide [4]. More

than 90% of all oral cancers are squamous cell carcinoma (SCC) [5,6]. The most important risk factors for oral SCC are the use of tobacco or betel quid and the regular drinking of alcoholic beverages. However, infection with high-risk human papillomavirus (HPV) genotypes and a diet low in fresh fruits and vegetables have also recently been implicated in the aetiopathogenesis of oral SCC [4-7]. The Indian subcontinent has the highest incidence and prevalence of oral SCC, owing to the widespread use of chewing tobacco, betel quid, and areca nut, all of which enhance the risk of developing oral SCC [5].

Tobacco, alcohol, betel quid, and areca nut have different mutagenic effects depending on the amount, frequency, and duration of usage. They are accelerated and exaggerated by the concurrent use of two or more of these agents [7]. Squamous cell carcinoma, the most frequently diagnosed histological type of oral cancer, is traditionally believed to be a disease of older men, smokers, and those exposed to the chronic use of alcohol, and especially individuals of low socioeconomic status [8,9]. Observational studies show that tobacco is the main risk factor for oral squamous cell carcinoma. Together with alcohol, it has been implicated in more than 90% of all squamous cell carcinomas of the oral cavity [9,10,11].

Tobacco plays its role in the initiation of cancer through the aid of more than 300 chemicals with carcinogenic properties found in it [9]. The more important of these are the polycyclic aromatic hydrocarbons and tobacco-specific nitrosamines. Alcohol is believed to contribute to carcinogenesis by modifying the basal cells of the oral epithelium, thus making them more susceptible to carcinogenic compounds; in addition, aldehyde metabolites of alcohol are believed to have some mutagenic properties [9,12]. Alcohol also acts as a solvent, which allows the carcinogens to penetrate better to the target site. Tobacco and alcohol act synergistically when combined to effect genetic changes that eventually lead to squamous cell carcinoma [9,13]. Decades of epidemiological studies have shown a striking and profound effect of socioeconomic disparity on health. This effect remains evident in all health measures, either the rate of diseases, the severity of conditions or the outcome of diseases [14,15]. People from lower socioeconomic classes have worse health than those from higher socioeconomic classes. A possible explanation for this observation includes its effect on access to adequate nutrition, environmental exposures to toxins, quality of medical care, access to supportive social network resources, and psychological-behavioral factors [14,15]. In addition, individuals of low socioeconomic status tend to indulge in habits that are less healthy, such as the use of tobacco and alcohol and eating fewer fruits and vegetables, than those of higher socioeconomic status. However, studies on the role of socioeconomic factors on oral squamous cell carcinoma incidence are conflicting [16]. However, not all persons who practice these high-risk habits will develop oral SCC. Because oral SCC can be idiopathic, there must be individual genetic and environmental factors that can either protect against the formation of oral SCC or predispose to or even accelerate the development

of oral SCC [16]. Due to the prevalent nature of the presentation, there is often a delay in diagnosis, which could be due to patient delay (in seeking professional help), professional delay (in reading the diagnosis), or both. As a result, understanding the various presentations and having an experienced eye can help prevent the high morbidity and mortality rates associated with oral malignancies [17].

The rich lymphatic supply of the oral cavity is an important factor to consider, as many cases are discovered early on in the advanced stage. Patient's ignorance of symptoms and lack of care for the disease may be to blame for the late presentation [17]. The TNM-system of the Union for International Cancer Controls is the most widely used classification system for describing the anatomical extent of the disease [18]. It assigns a score to the size and invasive characteristics of the primary tumor (T), regional lymph node spread (N), and the presence of distant metastasis (M). The TNM stage is still the most essential indicator for therapy stratification in clinical practice, and oral squamous cell carcinoma patient's survival time is highly linked to the TNM stage [19,20]. Tumors are characterized morphologically into well, moderately, and poorly differentiated carcinomas based on cancer cell differentiation. According to some sources, patients with well differentiated tumours lives longer than patients with low differentiated tumours [21,22], whereas other report poor correlation between outcome and tumour grade [23,24].

Oral SCC affects men more frequently than women (Male: Female=1.5:1), owing to the fact that men are more likely to engage in high-risk factors. The chance of developing oral SCC rises with time and exposure to the risk factors, and as one gets older, age-related mutagenesis and epigenetic changes increases such a risk. Oral SCC is diagnosed at a median age of 62 years in the United States. However, the incidence of oral SCC in persons under the age of 45 is increasing 25. The reason for this is obscure [21-26]. A number of conditions have been associated with an elevated risk of developing oral SCC, including Li Fraumeni syndrome, Plummer-Vinson syndrome, Fanconi anemia, chemotherapy-induced immunosuppression of organ transplantation, dyskeratosis congenital, xeroderma pigmentosum, and discoid lupus erythematosus [26]. squamous cell carcinoma presents different clinical aspects, which are related to the location of the tumor, evolution time, precancerous lesions, and risk factors. The most frequent clinical aspects are tumor, ulcer, verrucous and mixed forms such as ulcerative swelling

or verrucous ulcers [27]). The diagnosis of early lesions such as in-situ or microinvasive carcinoma represents a real challenge for health professionals. Leukoplakia, Erythroplakia or Erythroleukoplakia are the most frequent clinical aspects, which may present superficially eroded areas [26,27]. The abovementioned lesions are asymptomatic, tend to keep their size, may show surface changes, and do not respond to local therapies. The lesion can progress to an exophytic, irregular lobulated lesion or adopt an endophytic growth pattern characterized by a depressed ulcer with grayish-white edges, elevated, everted, and indurate borders, and an infiltrated base. In most cases, lesions are usually asymptomatic, with pain appearing only when muscles or nerves are affected later in the disease [28,29]. Multiple factors influence the prognosis of oral cancer, including histopathological variety, tumor differentiation, primary tumor extension and localization, degree of invasion of neighboring structures, presence of metastatic regional lymph nodes, presence of distant metastases, the choice of therapeutic modality, and the general health status of the patient [30]. Oral malignancies are frequently discovered lately [31] Between 34% and 66% of people die within five years after being diagnosed [32,33].

In Western countries, oral SCC affects the tongue in 20%-40% of cases and the floor of the mouth in 15%-20% of the cases, and together these sites account for about 50% of all cases of oral SCC [34,35]. The gingivae, palate, retromolar area, and the buccal and labial mucosa are oral sites less frequently affected [36]. The ventral surface of the tongue and the floor of the mouth are the sites most commonly affected by SCC because they are lined by thin non-keratinized epithelium. Carcinogens, particularly tobacco products and alcohol in solution not only easily passes through this thin epithelium to reach the progenitor cell compartment, but they also accumulate on the floor of the mouth and bathe the tissues of the floor of the mouth and the ventrum of the tongue [37]. The existence of regional lymph node metastases, the size (surface dimension) and depth (extent of local infiltration) of the carcinoma, the oral anatomical site affected, and the histological grade of the carcinoma are all crucial criteria in determining survival when an oral SCC is diagnosed. After treatment, whether or not the margins of the resected carcinoma were free of invading carcinomatous cells will determine whether or not there will be local recurrence; and whether or not a second tumor will develop in the same or a contiguous epithelialized precancerized field will determine whether or not there

will be local recurrence [26,35,38-40].

Materials and Methods

In a prospective study, using descriptive analysis, the total 80 cases are collected and histologically diagnosed as squamous cell carcinoma from July-1st-2019 to May-1st-2020, from different regions including Baghdad, Hawler, Sulaymaniyah, Duhok, Rania, Kalar, and Khanaqin, collected and examined at the maxillofacial surgery department, Sulaymaniyah/Iraq. All cases were analyzed according to age, sex, site, patient complaints at the time of presentation, and histological grading. The total sample was grouped into four age groups from below 40 years to 80 years and above, from which (46 cases) were men and others (34 cases) were women. The clinical sites were categorized into seven sites, and undefined sites were included as separate entities; the clinical presentation of the lesions was grouped into six main features.

Patients having oral squamous cell carcinoma at all age groups and with no gender differences are included in this study. In contrast, patients with extra oral carcinoma, Sarcomas, Recurrence cases (previously operated cases) are excluded. Data were obtained through the specially designed case sheet, the sociodemographic profile of the patient, including patient initial, age, sex, presenting features, histological reports, and type of the surgical procedures. Patients were presented with previously diagnosed oral squamous cell carcinoma were thoroughly examined clinically, radiologically, and histologically. The clinical examination included inspection, palpation of the head and neck, and full-body; all cases were examined under good visual light, reflection, pictured using Nikon D700 camera. The clinical presentations are categorized into six clinical presentations at the time of observation. The histological grading was applied on each case using ordinary hematoxylin and eosin stain into the four grades of differentiation (well, moderately-well, poorly differentiated, and undifferentiated carcinomas). After diagnosis, all cases were prepared for treatment, treatment modalities were decided according to the staging of the tumors, as shown in Table 1. Statistical analysis was carried out using the SPSS statistical package, and descriptive statistics analyzed the variables of all patients. The ethical committee approved the study, faculty of medical science school of dentistry, and Informed consent was obtained from the patient and/or from the relative after explaining the purpose of the study for them and before sample collection.

Result

Age and sex distribution is shown in Table 2. The highest affected age groups were those between 60 and 80 years, with mean age was (59.6), patients at their sixth decade of life were most commonly affected (52.5%). Regarding sex prevalence, through total of 80 cases, 46 (57%) cases were males and 34 (43%) cases were females; the male to female ratio was 1.4:1. Figure 1. Regarding site distribution, six different sites of the oral cavity were involved by the lesion as described in (Table 3), the tongue was the most commonly affected subsite, which comprises eleven cases (27.5%) out of 80 cases, followed by the floor of mouth (20%), other sites were buccal mucosa (17.5%), lower alveolar ridge (17.5%), upper alveolar ridge (15%), and soft palate (2.5%) as shown in Figure (2,3,4 and 5) respectively. The majority of patients had at least one symptom associated with their tumor at the time of diagnosis. Ulceration and swelling were the most common complaint of the patients at the time of the first presentation, which comprises (62) cases (77.5%) collectively out of 80 patients, followed by pain (7.5%), tongue fixation (7.5%), leukoplakia (5%) and Erythroplakia (2.5%). Table 4. However; most of the patients have combinations of two or more symptoms, for example, pain in addition to the swelling; also, most of the cases have a combination of more than one clinical presentation at the time of arrival, for example, ulcerative swelling and Erythroleukoplakia as shown in Figure (3 and 4) respectively, with a predominance of one symptom.

Health education of the patients and elevation of the diagnostic standards of the general practitioners play an important role in the early detection of oral cancer, particularly in developing countries. This means less radical treatment modalities and a higher survival rate of the patients. The following figures (7,8,9,10, and 11) show different presentations of squamous cell carcinomas affecting the oral cavity. Histological diagnosis and assessment of the degree of the differentiation (Grading) of the lesion is the duty of the pathologist. Unfortunately, a number of lesions are reported in the present study and in others as squamous cell carcinoma without the reference to the degree of differentiation because of defect and neglect in data collection from some surgical centers, which were collected by inexperienced personals [41]. However, the majority of lesions in this study were of the well-differentiated type Table 5. Regarding the risk factors, through the number of 80 cases, the total non-smoker patients were (68) cases which accounts (85%), occasional smokers were (4) cases which accounts (5%), frequent smokers

(8) which accounts (10%). Total non-alcoholic patients were (78) cases which accounts (97.5%) and frequent alcoholic was (1) case which accounts (1.25%) Table 6.

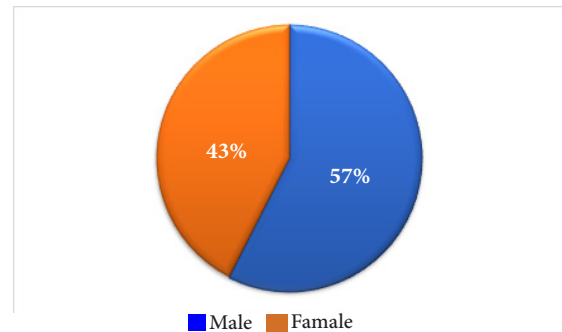


Figure 1. Sex distribution in percentage of oral squamous cell carcinoma.

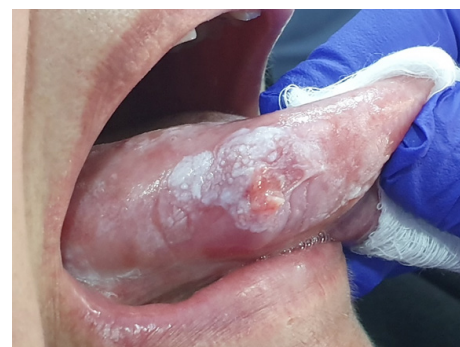

Figure 2. Squamous cell carcinoma of lateral border of the tongue.

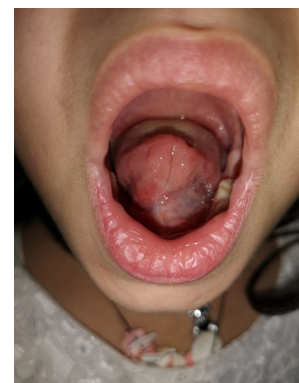

Figure 3. Squamous cell carcinoma of the floor of the mouth.

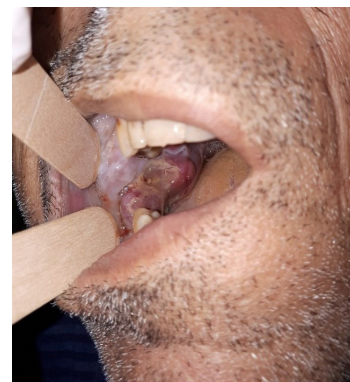

Figure 4. Squamous cell carcinoma of the lower alveolar ridge and buccal mucosa.

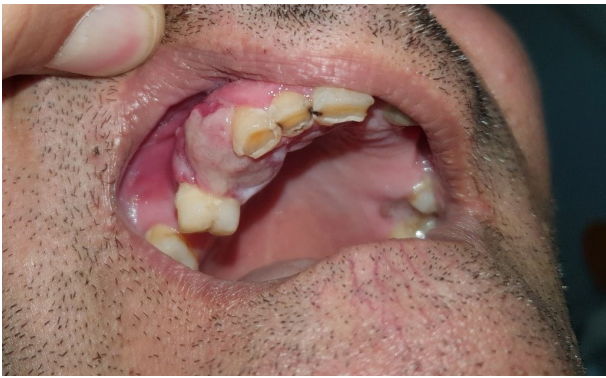

Figure 5. Squamous cell carcinoma of the upper alveolar ridge.

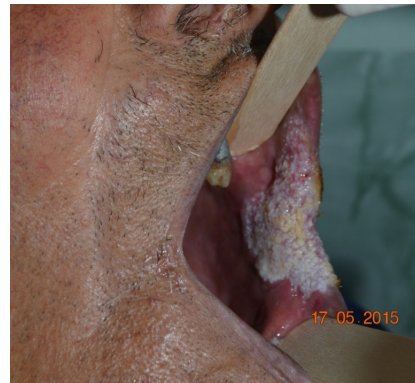

Figure 9. Leukoplakia verruciform type (Squamous cell carcinoma was proven by incisional biopsy).

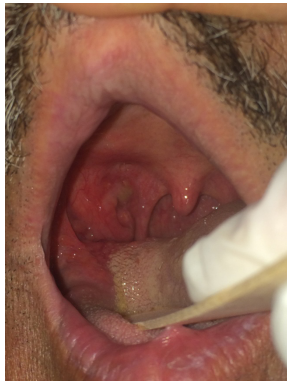

Figure 6. Squamous cell carcinoma of the soft palate.

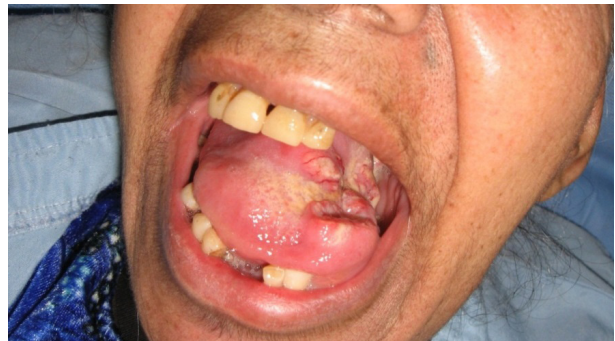

Figure 10. Ulcerated swelling and tongue fixation.

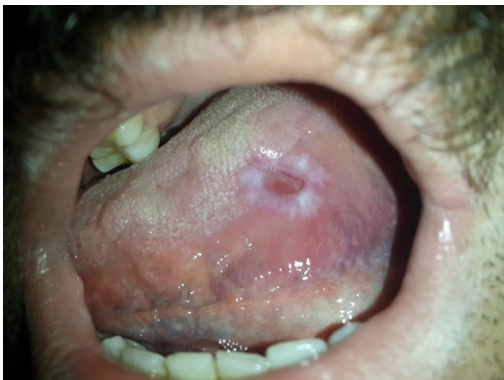

Figure 7. Ulceration of the lateral border of tongue.

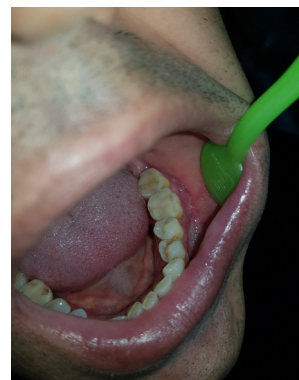

Figure 11. Erythroplakia of lower vestibule.

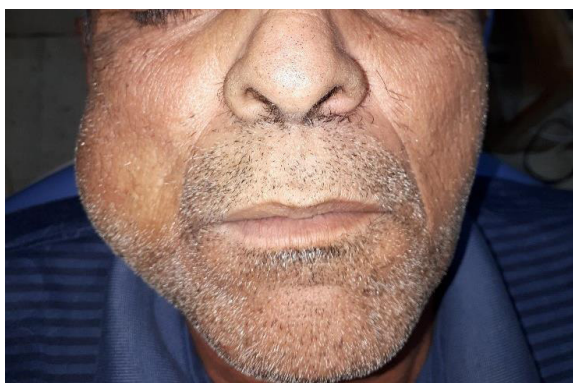


Figure 8. Left side facial swelling from carcinoma of lower alveolar ridge.

Table 1. Treatment modalities for oral squamous cell carcinoma.

<i>Treatment modalities</i>	<i>Number of patients</i>	<i>Percentage</i>
<i>Surgery alone</i>	2	2.5%
<i>Radiotherapy alone</i>	0	0%
<i>Chemotherapy alone</i>	0	0%
<i>Combination of above</i>	78	97.5%

Table 2. Age and sex distribution of 80 cases of oral squamous cell carcinoma.

<i>Age group</i>	<i>Male</i>	<i>Percentage from total</i>	<i>Female</i>	<i>Percentage from total</i>	<i>Total</i>	<i>Percentage from total</i>
<i>Below 40</i>	0	0.00%	0	0.00%	0	0.00%
<i>40-59</i>	18	22.5%	18	22.5%	36	45%
<i>60-79</i>	28	35%	14	17.5%	42	52.5%
<i>Above 80</i>	0	0.00%	2	2.5%	2	2.5%

Table 3. Six oral cavity subsites involved by SCC distribution.

<i>Number</i>	<i>Site</i>	<i>Total</i>	<i>Percentage</i>
1	<i>Tongue</i>	22	27.5%
2	<i>Floor of mouth</i>	16	20%
3	<i>Buccal mucosa</i>	14	17.5%
4	<i>Lower alveolar ridge</i>	14	17.5%
5	<i>Upper alveolar ridge</i>	12	15%
6	<i>Soft palate</i>	2	2.5%

Table 4. Clinical presentation of oral squamous cell carcinoma.

<i>Grade of differentiation</i>	<i>Number of cases</i>	<i>% Percentage</i>
<i>Well differentiated</i>	32	40%
<i>Moderately differentiated</i>	16	20%
<i>Poorly differentiated</i>	18	22.5%
<i>Undifferentiated</i>	14	17.5%

Table 5. Grade of differentiation.

<i>Clinical presentation</i>	<i>Number of cases</i>	<i>% Percentage</i>
<i>Ulceration</i>	40	50%
<i>Swelling</i>	22	27.5%
<i>Pain</i>	6	7.5%
<i>Tongue fixation</i>	6	7.5%
<i>Leukoplakia</i>	4	5%
<i>Erythroplakia</i>	2	2.5%

Table 6. Risk factors associated of development of oral squamous cell carcinoma.

Risk factors	Male	Percentage	Female	Percentage	Total	Percentage
<i>Tobacco use:</i>						
Non-smoker	38	47.5%	30	37.5%	68	85%
Occasional use	2	2.5%	2	2.5%	4	5%
Frequent use	6	7.5%	2	2.5%	8	10%
Unknown	0	0.00%	0	0.00%	0	0.00
<i>Alcohol consumption:</i>						
Non-drinker	44	56.4%	34	43.5%	78	97.5%
Occasional use	1	0.00%	0	0.00%	1	1.25%
Frequent use	1	1.25%	0	0.00%	1	1.25%
Unknown	0	0.00%	0	0.00%	0	0.00

Discussion

Although many studies have emphasized that oral squamous cell carcinoma represents 80 to 90% of all oral malignant tumors, it is supposed that the additional referral of more complex and challenging malignant cases can be responsible for this bias in oral squamous cell carcinoma frequency [41]. In this study, oral squamous cell carcinoma was predominantly affected males with a male to female ratio of 1.4:1; this variable was apparently to be due to the vulnerability and exposure of the male patients to the different risk factors such as sunlight, smoking, and tobacco use, this study agrees with many of other studies in which male: female ratios ranging from 6:1 to 2:1 [42-45], while several other recent studies have shown an increase in the number of affected females, with a male: female ratio lower than 2:1. Because of changes in social and daily activities connected with modern women's social profiles and ways of life, they are more likely to be exposed to carcinogenic agents like tobacco and alcohol, as well as biological agents like high-risk HPV subtypes [46-53]. Most studies have reinforced that oral squamous cell carcinoma is mostly diagnosed in adults with mean ages in their fifties to seventies [42-46,50,52], a finding also corroborated by the present results. It seems that there are geographical and populational differences in the mean age of the affected patients, as demonstrated by an author [47] in Nigeria, which revealed a mean age of 45.3 years old and 40% of the patients with ages below 40 years old. Other authors have found that the average age of males with oral squamous cell carcinoma is lower than the average age of females, contrary to the findings of this study [47,51]. Present and past tobacco and alcohol consumption are considered the most important risk factors for oral squamous cell carcinoma [50]. The present results showed that both deleterious

habits were frequently reported by oral squamous cell carcinoma-affected patients and that both were more common in males than in females, similarly to other studies [51,54,55] this pattern can be responsible for the differences in the male: female ratio of oral squamous cell carcinoma-affected patients. Younger patients affected by oral squamous cell carcinoma sometimes do not report tobacco and alcohol use as possible risk factors, or the interval of use is not long enough to support a definite carcinogenic effect. Other potential risk factors in this group have been suggested, such as dietary/nutritional variables and genetic susceptibility, and high-risk HPV types (particularly HPV type 16) have been found in oral squamous cell carcinoma in youngsters and adolescents more frequently than in adult/elderly controls [50,56,57].

Oral potentially malignant disorders (OPMD) are quite prevalent, with a global prevalence of 1 to 5%, gender, age, and location predilection that are similar to oral squamous cell carcinoma. Although the exact rate of malignant transformation for OPMD is unknown, Leukoerythroplakic regions are likely to occur in conjunction with oral squamous cell carcinoma [50]. This pattern was found in 7.5% of the patients included in the present study; these results reinforce the importance of considering the possibility of oral squamous cell carcinoma when dealing with leukoplakias and Erythroplakia and the need of obtaining biopsy specimens from all lesions from this group. Oral squamous cell carcinoma can affect any site of the oral mucosa, and large lesions can invade several continuous areas. The present results showed that the border of the tongue, floor of the mouth, gingiva/alveolar ridges, cheek, buccal mucosa, and soft palate were the most commonly affected locations. Although the bor-

der of the tongue is considered the most common site for oral squamous cell carcinoma in America and Europe [52,58], the buccal mucosa is the most common site for oral squamous cell carcinoma in southeastern Asia, due to habits of areca nut- and tobacco-chewing [49,50] they have additionally reported that 50% of their oral squamous cell carcinoma affected the gingiva and alveolar ridge, which could be justified by the different etiological factors associated with the development of oral squamous cell carcinoma in their specific population. Similarly, author [47] has shown, in Nigeria, that the lower and upper gingiva were the most common affected sites in their sample, followed by the tongue. Most studies focusing on Brazilian and other occidental populations have shown that the border of tongue and floor of the mouth are the most common oral squamous cell carcinoma-affected regions [43-45]. It is important to call attention to the fact that, when considered together with intraoral locations, the lower lip is the most common site for oral squamous cell carcinoma [42,46] have demonstrated that the tongue and the buccal mucosa were the two most common locations for oral squamous cell carcinoma in Iran. An author has shown that, in Hungary, the floor of the mouth, lips, and tongue were the most commonly affected areas [55]. Although delay in diagnosis is a major problem in the early detection of oral squamous cell carcinoma, the exact reasons for these difficulties, including social and health-related behavior and tumor characteristics, are not well-understood [59]. Most tumors included in the present series were diagnosed as cT3 or cT4 tumors, but the mean interval of complaints prior to professional assistance was six months. Similarly, an analysis of 740 oral squamous cell carcinoma patients in the state of Minas Gerais, also in southeastern Brazil, indicated that nearly half of the patients had T4 tumors. 43 Despite the fact that this previous study was published a decade ago and it appears that tumors are being discovered at an earlier stage in recent years, various biases could explain the disparities.

In this study, after the time presentation, some additional delay was expected, both due to the patient and institutional difficulties and limitations, before starting treatment. Most of the oral squamous cell carcinoma in this study are histologically diagnosed as well-differentiated WD and moderately differentiated tumors (MD), the same result was described by other authors [42,46,49,55,58,60,61], as into [47] have shown that 47.6% of their cases were histologically classified as Poorly differentiated tumors (PD) tumors, while well differentiated tumors represented 32.6% of their

sample. Several oral squamous cell carcinoma variants have been reported in the literature, and the establishment of the specific appropriate histological diagnosis is essential, as some histological subtypes and distinct clinicopathological entities are managed with different treatment protocols and present variable prognosis [60,61]. In study [62] have recently reported a series of 133 verrucous carcinomas, representing 16% of all SCC diagnosed in their files from India. Their cases have affected mostly males in their fifties with a predilection for the buccal mucosa. The age and gender profile of oral squamous cell carcinoma, as well as site predilection, shows a heterogeneous pattern of distribution in different countries, different regions within the same country, and different ethnic groups within the same region, which can be linked to both genetic factors and cultural habits/behavior. Studies that focus on specific regions are beneficial because they highlight the demographic and clinical profile of oral squamous cell carcinoma in certain geographic areas, allowing for a better understanding of these tumors and the development of appropriate prevention, diagnosis, and treatment strategies [60-63]. The course of oral SCC is unpredictable, but the TNM stage (T-tumour size, N-nodal metastasis, M-distant metastasis) of the primary tumor correlates well with the survival rate [63]. The prognosis is best when the primary tumor is small and there is no evidence of regional lymph node involvement or distant metastasis. In fact, the 5- year survival rate of persons with early-stage oral SCC according to the TNM staging system may reach 80% - 90% [64]), whereas the five-year survival rate for advanced-stage oral SCC is about 40% [65].

Oral SCC may take various clinical forms. It may look like a leukoplakia, a verrucous leukoplakia, an Erythroleukoplakia, or an Erythroplakia, all of which can progress to a necrotic-looking ulcer with uneven, elevated indurated margins or a broad-based exophytic mass with a verrucous, pebbled, or comparatively smooth surface texture. When oral squamous cell carcinoma is traumatized, it bleeds readily and frequently becomes superficially secondary infected. Unless it is secondary infected, oral squamous cell carcinoma is usually painless. Large lesions can make proper speaking, mastication, and swallowing difficult [66-68]. Oral squamous cell carcinoma can arise from pre-existing potentially malignant disorders, including oral leukoplakia, Erythroplakia, submucous fibrosis, and lichenoid dysplastic lesions, or can arise de novo [68,69]. The malignant potential of oral lichen planus, particularly the erosive type, is a topic of dispute in the

literature. While some researchers found an association between oral lichen planus and the development of oral squamous cell carcinoma, others did not [67,69]. Our view in this article is that oral lichen planus does pose an increased risk of oral squamous cell carcinoma. It has been suggested that oral SCC evolving from leukoplakic lesions have a better prognosis than those emerging de novo, but a recent study has shown that the prognosis is not significantly different in these two groups of oral SCC [70]. Early lesions, such as in-situ or microinvasive carcinoma, pose a significant barrier for medical experts to diagnose. Leukoplakia, Erythroplakia, or Erythroleukoplakia are the most frequent clinical aspects, which may present superficially eroded areas [70]. The lesion can proceed and develop as an exophytic, irregular lobulated lesion or as an endophytic growth pattern with a depressed ulcer with grayish-white borders, elevated, everted, and indurated borders, and an infiltrated base. In this study, lesions were asymptomatic in most cases; pain appears only when muscles or nerves are invaded at advanced stages of the disease. This result is similar to other studies [70-73].

Tongue carcinoma is the most commonly observed oral cancer (OC); traumatic lesions, leukoplakia, and lichen planus are predominant precancerous conditions. Tongue carcinoma in our study represented 27.5% which is the most common intraoral site of SCC. A similar finding was reported by another author, who found that tongue cancer affected 30-40% of OCs, with the lateral tongue being the most common site, followed by the ventral and dorsum tongues [71]. Traumatic lesions on the lateral border of the tongue and the ventral surface of the tongue are generally preceded by traumatic lesions caused by sharp cusps or sharp-edged teeth, improperly positioned teeth, or maladjusted dentures that continuously rub the stated areas. Ulcerated forms are the most frequently observed, followed by exophytic tumors, which generally produce pain irradiating to the ear. In the ventral area, ulcer-vegetate or mixed forms predominate. Tumors on the dorsum are generally associated with lichen planus or leukoplakia lesions. They are clinically observable as ulcerated forms tend to expand on the surface rather than go deeper into it [71,72]. The lateral border of the tongue and the floor of the mouth (with extensions to the back lateral soft palate and tonsillar areas) combine to form a horseshoe-shaped region in the oral mucosa, as highly risky for cancer development and also as a bad prognostic area [72]. These tumors tend to evolve towards the ventral side and to the floor of the mouth.

In the first consultation in this study, approximately 40% of the patients have lymph nodes, and other study mentioned a higher incidence of cervical lymph node metastasis as they noticed that when the lesion has more than 4 cm size, lymph nodes are present in 90% of the cases [73]. Tumors located in the anterior half of the tongue usually lead to lymphadenopathy in the suprahyoid region, while those located in the posterior half led to submaxillary, carotid, and retropharyngeal nodes. Contralateral nodes are more frequent from tumors in the ventral surface and floor of the mouth [73,74]. Oral squamous cell carcinomas in gingiva and alveolar ridge are the second most frequent locations, which is not the case in this study and other countries [71]. When the carcinoma is positioned in the gingival or alveolar ridge, it is difficult to detect earlier lesions. However, it is typical to correlate such places with periodontal disease [75,76]. Chronic inflammatory activity would produce genotoxic mediators, which would encourage the accumulation of genetic abnormalities, eventually leading to malignant cell development. Gingival carcinoma appears as a red or white patch that is mildly vegetant at first and spreads on the surface due to the periosteum's resistance [76].

As oral squamous cell carcinoma advances, it adopts a tumoral shape. It has the potential to infiltrate bones, loosen teeth, and cause pain or trismus. The submental, submandibular, and carotid regions are the most common sites for nodal metastasis. The anteroinferior lesions progress towards the floor of the mouth and to the ventral side of the tongue. If the tumor is located in the posterior zone, it invades the floor of the mouth as well as the masticatory muscles [76,77]. The floor of the mouth oral squamous cell carcinoma starts mainly in the anterior area as red and/or white spots, plaque or nodular, ulcerated lesions, later indurated at palpation. It is not painful at an early stage, although the tongue's mobility can eventually be impaired. It advances from the surface to the depths of the tissues, invading the floor of the mouth muscles, the submental, submaxillary, and cervical nodes [77]. Most buccal mucosa SCC is characterized by developing on previous lesions. The Leukoplastic form and Erythroplastic forms are commonly observed in the anterior part of the buccal mucosa. At the same time, in the posterior one, it is more often secondary to traumatic lesions or lichen planus. The induration of Erythroplastic lesions, which tend to develop an exophytic look as they grow, is one of the early symptoms of the transformation. This type of SCC rarely presents ulcers, whereas differentiated histopathologic forms are predominant [72,73]. Squa-

mous cell carcinoma in the posterior third of the buccal mucosa usually manifests as endophytic or ulcers; undifferentiated histological types are the most common and have a worse prognosis than in the anterior third. The afflicted nodes are usually seen in the submaxillary region; however, they can also be found in the cervical or facial regions [72,73]. An interdisciplinary team of specialists in head and neck tumors should make the choice regarding the best treatment for each patient. Treatment options are mostly determined by the size and stage of the disease, as well as the patient's overall condition. Surgery or radiation therapy are likely to be used in early-stage intraoral tumors. The type of therapy chosen is based on the expected functional and cosmetic outcomes, as well as the availability of the surgeon's or radiation therapist's specific skills for each patient. Surgery and radiation therapy are usually used to treat advanced cancers (stages III and IV) [76-78]. In the last 10–20 years, the therapy for head and neck malignancies, particularly those involving the oral cavity, has evolved. Surgery combined with radiation therapy is now universally acknowledged as having a better prognosis for advanced OC tumors than either modality alone [78].

It is worth mentioning that the current advent of state-of-the-art technology applied to cancer treatments has significantly improved the quality of life of OC patients. However, there are only a few data as to the length of survival in relation to new devices such as gamma rays, electrons, protons, and atomic nuclei, tridimensional (3DR), stereotactic, Modulated Intensity Radiotherapy (MIR), and Image-Guided Radiation Therapy (IGRT). The new technology allows the professional to better adjust radiation to the tumor, thus diminishing the damage inflicted to the surrounding healthy tissues, especially major salivary glands, and maxillaries. Brachytherapy is a still used resource; it requires the isolation of the radiated patient, and it should be carried out by highly experienced professionals [78,79]. Despite all of the above-mentioned innovations, the occurrence of complications is high, which would undoubtedly cause regular therapeutic protocols to be delayed. As a result, patients would be more vulnerable to recurrence or metastasis [79-80].

Conclusion

Despite technical breakthroughs in treatment, oral squamous cell carcinoma has a poor prognosis and a limited survival period. Oral cavity cancers are easily discovered with a simple oral examination, although the rate of early identification has not improved over

time when compared to cancers that require more complicated screening procedures (e.g., breast, prostate, and colon). Dental professionals have an important role both in primary prevention of oral cancer by inducing healthy lifestyles and in secondary prevention by detecting oral cancer or its precursor lesions at early stages. The early detection and diagnosis of asymptomatic oral squamous cell carcinoma requires a high index of clinical suspicion and provides better outcome and survival rates after treatment.

Acknowledgement

The author would like to acknowledge the Oral and maxillofacial department, Sulaimani teaching hospital, University of Sulaimani for supporting the study.

Conflict of Interest

There is no conflict of interest to declare.

References

- [1] Federation Dentaire Internationale (1999) FDA statement: Oral cancer. *FDA World* 8(1):24.
- [2] Neville, B., Damm, D. & Allen, C. et al. *Oral & Maxillofacial Pathology*. 2nd ed. Phila. (2002), PA: Saunders, p.337-369.
- [3] Gorsky M, Littner MM, Sukman Y, Begleiter A, The prevalence of Oral cancer in relation to the ethnic origin of Israeli Jews. *Oral Surg Oral Med Oral Pathol* (1994) 78(3): p.408–411.
- [4] J. P. Shah and Z. Gil, "Current Concepts in Management of Oral Cancer-Surgery," *Oral Oncology*, 2009, Vol. 45, No. 4, p.394-401.
- [5] E. Attar, S. Dey, A. Hablas, I. A. Seifeldin, M. Ramadan, L. S. Rozek and A. S. Soliman, "Head and Neck Cancer in a Developing Country: A Population-Based Perspective Across 8 Years," *Oral Oncology* 2010, Vol. 46, No. 8, p.591-596.
- [6] J. Bagan, G. Sarrion and Y. Jimenez, "Oral Cancer: Clinical Features," *Oral Oncology*, 2010, Vol. 46, No.6, p.414-417.
- [7] S. Petti, Lifestyle Risk Factors for Oral Cancer, *Oral Oncology*, 2009, Vol. 45, No. 4, p.340-350.
- [8] Ribeiro ACP, Silva ARS, Simonato LE, et al. Clinical and histopathological analysis of oral squa-

- mous cell carcinoma in young people: A descriptive study in Brazilians. *Br J Oral Maxillofac Surg*. 2009; 47: p.95-98.
- [9] Losi-Guembarovski R, Menezes RP, Polisel F, et al. Oral carcinoma epidemiology in Paraná State, Southern Brazil. *Cad Saude Publica*. 2009; 25: p.393-400.
- [10] Sadri Gh.H, Mahjub H. Tobacco smoking and oral cancer: A meta-analysis. *J Res Health Sci*. 2007; 7: p.18-23.
- [11] Kingsley K, O'Malley S, Ditmyer M, et al. Analysis of oral cancer epidemiology in the US reveals state-specific trends: implications for oral cancer prevention. *BMC Public Health*. 2008; 8:87.
- [12] Brennan P, Lewis S, Hashibe M, et al. Pooled analysis of alcohol dehydrogenase genotypes and head and neck cancer. *Am J Epidemiol*. 2001; 159: p.1-16.
- [13] Mehrotra R, Yadav S. Oral squamous cell carcinoma: Etiology, pathogenesis and prognostic value of genomic alterations. *Indian J Cancer*. 2006; 43: p.60-66.
- [14] Chen E. Why Socioeconomic Status Affects the Health of Children: A Psychosocial Perspective. *Curr Directions Psych Sci*. 2004; 13: p.112-115.
- [15] Gele AA, Harsløf I. Types of social capital resources and self-rated health among the Norwegian adult population. *Int J Equity Health*. 2010; 9:8.
- [16] Hashibe M, Jacob BJ, Thomas G, et al. Socio-economic status, lifestyle factors and oral premalignant lesions. *Oral Oncol*. 2003; 39: p.664-671.
- [17] Morelato RA, Herrera MC, Fernández EN, Corball AG, López de Blanc SA. Diagnostic delay of oral squamous cell carcinoma in two diagnosis centers in Córdoba Argentina. *J Oral Pathol Med* 2007; 36: p.405-8.
- [18] Sobin L, Gospodarowicz M, Wittekind C: *TNM Classification of Malignant Tumours*. 7th edition. Chichester: Wiley-Blackwell; 2009.
- [19] Leemans CR, Braakhuis BJ, Brakenhoff RH: The molecular biology of head and neck cancer. *Nat Rev Cancer* 2011, 11(1): p.9-22.
- [20] Massano J, Regateiro FS, Januário G, Ferreira A: Oral squamous cell carcinoma: review of prognostic and predictive factors. *Oral surg oral med oral pathol oral radiol endod* 2006, 102(1): p.67-76.
- [21] Chen YK, Huang HC, Lin LM, Lin CC: Primary oral squamous cell carcinoma: an analysis of 703 cases in southern Taiwan. *Oral Oncol* 1999, 35(2): p.173-179.
- [22] Kademani D, Bell RB, Bagheri S, Holmgren E, Direrks E, Potter B, Homer L: Prognostic factors in intraoral squamous cell carcinoma: the influence of histologic grade. *J Oral Maxillofac Surg* 2005, 63(11): p.1599-1605.
- [23] Po Wing Yuen A, Lam KY, Lam LK, Ho CM, Wong A, Chow TL, Yuen WF, Wei WI: Prognostic factors of clinically stage I and II oral tongue carcinoma-A comparative study of stage, thickness, shape, growth pattern, invasive front malignancy grading, Martinez-Gimeno score, and pathologic features. *Head Neck* 2002, 24(6): p.513-520.
- [24] OC P, Pillai G, Patel S, Fisher C, Archer D, Eccles S, Rhys-Evans P: Tumour thickness predicts cervical nodal metastases and survival in early oral tongue cancer. *Oral Oncol* 2003, 39(4): p.386-390.
- [25] S. Warnakulasuriya, "Global Epidemiology of Oral and Oropharyngeal Cancer," *Oral Oncology*, 2009, Vol. 45, No. 4, p.309-316.
- [26] C. Scully and J. Bagan, "Oral Squamous Cell Carcinoma Overview," *Oral Oncology*, 2009, Vol. 45, No. 4, p. 301-308.
- [27] Boring, C., Squires, T. & Tong, T. *Cancer Statistics*. *Cancer J Clin*, (1994), Vol 44, p.7-26.
- [28] Silverman, S. Jr, Dillon, W. & Fischbein, N. *Diagnosis In: Silverman S. Jr ed. Oral Cancer*. 4th ed. Hamilton, Ontario, Canada: BC Decker Inc (1998), p.41-66.
- [29] Silverman S Jr, Shillitoe EF. *Etiology and Predisposing Factors*. In: Silverman S Jr. *Oral Cancer*, 4th ed. Hamilton, Ontario, Canada: BC Decker Inc; 1998, p.7-24.

- [30] Ghoshal S, Mallick I, Panda N, Sharma SC. Carcinoma of the buccal mucosa: analysis of clinical presentation, outcome and prognostic factors. *Oral Oncol.* 2006 May; 42(5): P.533-539.
- [31] Morelato RA, Herrera MC, Fernandez EN, Corball AG, Lopez de Blanc SA. Diagnostic delay of oral squamous cell carcinoma in two diagnosis centers in Cordoba Argentina. *J Oral Pathol Med.* 2007 Aug; 36(7): p.405-8.
- [32] Jones AS, Beasley N, Houghton D, Husband DJ. The effects of age on survival and other parameters in squamous cell carcinoma of the oral cavity, pharynx and larynx. *Clin Otolaryngol Allied Sci.* 1998 Feb; 23(1): p.51-6.
- [33] Carinci F, Pelucchi S, Farina A, Bonsetti G, Mastrandrea M, Calearo C. Site-dependent survival in cancer of the oral cavity. *J Craniofac Surg.* 1997; 8(5): p.399-403.
- [34] J. Bagan, G. Sarrion and Y. Jimenez, "Oral Cancer: Clinical Features," *Oral Oncology*, 2010, Vol. 46, No. 6, p. 414-417.
- [35] I. O. Bello, Y. Soini and T. Salo, "Prognostic Evaluation of Oral Tongue Cancer: Means, Markers and Perspectives (I)," *Oral Oncology*, 2010, Vol. 46, No. 9, p.630-635.
- [36] S. Warnakulasuriya, "Global Epidemiology of Oral and Oropharyngeal Cancer," *Oral Oncology*, 2009, Vol. 45, No. 4, p.309-316.
- [37] B. W. Neville and T. A. Day, "Oral Cancer and Precancerous Lesions," *CA: A Cancer Journal for Clinician*, 2002s, Vol. 52, No. 4, p.195-215.
- [38] S. R. Larsen, J. Johansen, J. A. Sorensen and A. Krogdahl, "The Prognostic Significance of Histological Features in Oral Squamous Cell Carcinoma," *Journal of Oral Pathology and Medicine*, 2009, Vol. 38, No. 8, p. 657-662.
- [39] V. M. van Houten, C. R. Leemans, J. A. Kummer, J. Dijkstra, D. J. Kuik, M. W. van den Brekel, G. B. Snow and R. H. Brakenhoff, "Molecular Diagnosis of Surgical Margins and Local Recurrence in Head and Neck Cancer Patients: A Prospective Study," *Clinical Cancer Research*, 2004, Vol. 10, No.11, p. 3614-3620.
- [40] Johnson NW, Jayasekara P, Amarasinghe AA. Squamous cell carcinoma and precursor lesions of the oral cavity: epidemiology and etiology. *Periodontol* 2000. 2011; 57: p.19-37.
- [41] Al-Rawi NH, Talabani NG. Squamous cell carcinoma of the oral cavity: a case series analysis of clinical presentation and histological grading of 1425 cases from Iraq. *Clin Oral Invest.* 2008; 12: p.15-18
- [42] Gervásio OL, Dutra RA, Tartaglia SM, Vasconcellos WA, Barbosa AA, Aguiar MC. Oral squamous cell carcinoma: a retrospective study of 740 cases in a Brazilian population. *Braz Dent J.* 2001; 12: p.57-61.
- [43] Grimm M. Prognostic value of clinicopathological parameters and outcome in 484 patients with oral squamous cell carcinoma: microvascular invasion (V+) is an independent prognostic factor for oral squamous cell carcinoma. *Clin Transl Oncol.* 2012; 14: p.870-880.
- [44] Losi-Guembarovski R, Menezes RP, Poliseli F, Chaves VN, Kuasne H, Leichsenring A, et al. Oral carcinoma epidemiology in Paraná State, Southern Brazil. *Cad Saude Publica.* 2009; 25: p.393-400.
- [45] Andisheh-Tadbir A, Mehrabani D, Heydari ST. Epidemiology of squamous cell carcinoma of the oral cavity in Iran. *J Craniofac Surg.* 2008; 19: p.1699-1702
- [46] Effiom OA, Adeyemo WL, Omitola OG, Ajayi OF, Emmanuel MM, Gbotolorun OM. Oral squamous cell carcinoma: a clinical and pathologic review of 233 cases in Lagos, Nigeria. *J Oral Maxillofac Surg.* 2008; 66: p.1595-1599
- [47] Gaitán-Cepeda LA, Peniche-Becerra AG, Quezada-Rivera DQ. Trends in frequency and prevalence of oral cancer and oral squamous cell carcinoma in Mexicans. A 20 years retrospective study. *Med Oral Patol Oral Cir Bucal.* 2011; 16: p. 460-467.
- [48] Jainkittivong A, Swasdison S, Thangpitsytotin M, Langlais RP. Oral squamous cell carcinoma: a clinicopathological study of 342 Thai cases. *J Contemp Dent Pract.* 2009; 10: E033-E040.
- [49] Kruse AL, Bredell M, Grätz KW. Oral cancer in

- men and women: are there differences? *Oral Maxillofac Surg.* 2011; 15: p.51–55.
- [50] Marocchio LS, Lima J, Sperandio FF, Corrêa L, Sousa SO. Oral squamous cell carcinoma: an analysis of 1564 cases showing advances in early detection. *J Oral Sci.* 2010; 52: p.267–273.
- [51] Rivero ER, Nunes FD. HPV in oral squamous cell carcinomas of a Brazilian population: amplification by PCR. *Braz Oral Res.* 2006; 20: p.21–24.
- [52] Albuquerque R, López-López J, Mari-Roig A, Jané-Salas E, Roselló-Llabrés X, Santos JR. Oral tongue squamous cell carcinoma (OTSCC): alcohol and tobacco consumption versus non-consumption. A study in a Portuguese population. *Braz Dent J.* 2011; 22: p.517–521.
- [53] Nemes JA, Redl P, Boda R, Kiss C, Márton IJ. Oral cancer report from Northeastern Hungary. *Pathol Oncol Res.* 2008; 14: p.85–92.
- [54] Kaminagakura E, Villa LL, Andreoli MA, Sobrinho JS, Vartanian JG, Soares FA, et al. High-risk human papillomavirus in oral squamous cell carcinoma on young patients. *Int J Cancer.* 2012; 130: p.1726–1732.
- [55] Marur S, D'Souza G, Westra WH, Forastiere AA. HPV-associated head and neck cancer: a virus-related cancer epidemic. *Lancet Oncol.* 2010; 11: p.781–789.
- [56] Larsen SR, Johansen J, Sørensen JA, Krogdahl A. The prognostic significance of histological features in oral squamous cell carcinoma. *J Oral Pathol Med.* 2009; 38:657–662.
- [57] Scott SE, Grunfeld EA, McGurk M. Patients delay in oral cancer: a systematic review. *Community Dent Oral Epidemiol.* 2006; 34: p.337–343.
- [58] Pereira MC, Oliveira DT, Landman G, Kowalski LP. Histologic subtypes of oral squamous cell carcinoma: prognostic relevance. *J Can Dent Assoc.* 2007; 73: p.339–344.
- [59] Woolgar JA, Triantafyllou A. Squamous cell carcinoma and precursor lesions: clinical pathology. *Periodontol* 2000. 2011; 57: p.51–72.
- [60] Rekha KP, Angadi PV. Verrucous carcinoma of the oral cavity: a clinical and pathologic appraisal of 133 cases in Indians. *Oral Maxillofac Surg.* 2010; 14: p.211–218.
- [61] C. Scully and J. Bagan, “Oral Squamous Cell Carcinoma Overview,” *Oral Oncology*, 2009, Vol. 45, No. 4, p.301- 308.
- [62] J. Bagan, G. Sarrion and Y. Jimenez, “Oral Cancer: Clinical Features,” *Oral Oncology*, 2010, Vol. 46, No. 6, p.414-417.
- [63] R. Mazon, Y. Tao, A. Lusinchi and J. Bourhis, “Current Concepts of Management in Radiotherapy for Head and Neck Squamous-Cell Cancer,” *Oral Oncology*, 2009, Vol. 45, No. 4, p. 402-408.
- [64] Barker, G., Barker, B. & Gier, R. *Oral management of the cancer patient: A guide for the health professional.* Kansas City, MO: University of Missouri-Kansas City (1996).
- [65] Zhang H, Dziegielewska PT, Biron VL, Szudek J, Al-Qahatani KH, O'Connell DA, et al. Survival outcomes of patients with advanced oral cavity squamous cell carcinoma treated with multimodal therapy: a multi-institutional analysis. *Journal of Otolaryngology-Head & Neck Surgery.* 2013; 42(1):30.
- [66] Mortazavi H, Safi Y, Baharvand M, Rahmani S. Diagnostic Features of Common Oral Ulcerative Lesions: An Updated Decision Tree. *Int J Dent.* 2016; 2016:7278925.
- [67] John S, Hassuji RM, Rajashekhar B. Speech and swallowing outcomes in buccal mucosa carcinoma. *Indian J Palliat Care.* 2011; 17(3):238-40.
- [68] Boudewijn, J., Braakhuis, A., Otto Visser, C. & René Leemans, A. Oral and oropharyngeal cancer in The Netherlands between 1989 and 2006: Increasing incidence, but not in young adults. *Oral Oncol*, 2009, Vol. 45, No e85, p.89-87.
- [69] Jansma, J., Vissink, A. & Jongebloed, W., Retief, D., Johannes's-Gravenmade, E. Natural and induced radiation caries: a SEM study. *Am J Dent*, 1993, No. 6, p.130–136.
- [70] Jongebloed, W., Gravenmade, E. & Retief, D. Radi-

ation caries. A review and SEM study. Am J Dent, 1988, Vol. 1, p.139-146.

- [71] Brandizzi, D., Gandolfo, M., Velazco, M., Cabrini, R. & Lanfranchi, H. Clinical features and evolution of oral cancer: A study of 274 cases in Buenos Aires, Argentina. Med Oral Patol Oral Cir Bucal, 2008, Vol Sep1, No13 (9), p.E544-548
- [72] Jovanovic, A., Schulten, E. & Kostense, P. et al. Tobacco and alcohol related to the anatomical site of oral squamous cell carcinoma. J Oral Pathol Med, 1993, Vol 22, p.459-462.
- [73] Shah, J., Candela, F. & Poddar, A. The patterns of cervical lymph node metastasis from squamous carcinoma of the oral cavity. Cancer, 1990, Vol 66, p.109-113.
- [74] Tshering Vogel DW, Zbaeren P, Thoeny HC. Cancer of the oral cavity and oropharynx. Cancer Imaging. 2010; 10(1):62-72.
- [75] Boudewijn, J., Braakhuis, A., Otto Visser, C. & René Leemans, A. Oral and oropharyngeal cancer in The Netherlands between 1989 and 2006: Increasing incidence, but not in young adults. Oral Oncol, 2009, Vol 45, No e85, p.89-87.
- [76] Chandu A., G. Adams, A. C. H. Smith. Factors affecting survival in patients with oral cancer: an Australian perspective. Int. J. Oral Maxillofac. Surg. 2005, Vol. 34, p.514-520.
- [77] Kerdpon, D. & Sriplung, H. Factors related to delay in delay in diagnosis of oral squamous cell carcinoma in southern Thailand. Oral Oncol, 2001, Vol. 37, No. 2, (Feb), p.127-131.
- [78] Kowalski, L. & Carvalho, A. Influence of time delay and clinical upstaging in the prognosis of head and neck cancer. Oral Oncol, 2001, Vol. 37, No. 1, p.94-98.
- [79] Shah, J. & Lydiatt, W. Treatment of cancer of the head and neck. CA Cancer J Clin, 1995, No. 45, p.352-368.
- [80] Allison, P., Franco, E. & Feine, J. Predictors of professional diagnostic delay for upper aerodigestive tract carcinoma. Oral Oncol, 1998, Vol 34, p. 127-32.

Please cite this paper as:

Jaza Mahmood B, Muhammad Mustafa U; Clinicopathological presentation of oral squamous cell carcinoma in iraqi population. J Craniomaxillofac Res 2021; 8(3): 129-142