



Influence of interdental embrasures on interdental papilla

Sameer Kedia ^{1*}, Kanteshwari Kumathalli ², Raja Sridhar ³, Simran Parwani ⁴, Satyajit Tekade ⁵

Ashish Warekar ⁶

1. Department of Periodontology, VYWS Dental College & Hospital, Amravati.

2. Dean, Sri Aurobindo College of Dentistry, Indore.

3. Department of Periodontology, Triveni Institute of Dental Sciences, Hospital & Research Center, Bilaspur.

4. Department of Periodontology, VYWS Dental College & Hospital, Amravati.

5. Department of Oral Pathology, Modern Dental College & Research Centre, Indore.

6. Dentistry Section, Department of Plastic, Reconstructive & Maxillofacial Surgery, Government Medical College, Nagpur.

ARTICLE INFO

Article Type:
Original Article

Received: 2 Jun. 2021

Revised: 8 Jul. 2021

Accepted: 25 Aug. 2021

*Corresponding author:

Sameer Kedia

Shivleela, Beside ICICI Bank, Bus stand Road, Amravati – 444602, Maharashtra, India.

Tel: +98-937-0152435

Fax: +98-21-84902473

Email: sameerkedianiar@gmail.com

ABSTRACT

Background: There is growing attention on anterior esthetics by both dentists and patients, which emphasizes the need for conduct of study encompassing the anatomical features of an embrasure and correlating with papilla fill. Hence the present study has been designed to meet these parameters, including food lodgement.

Aim: To assess the influence of anatomical and morphological characteristics of interdental embrasures on interdental papilla and food lodgement.

Objectives: Were set as the following:

1. Correlation of modified papilla index score (PIS) with interdental anatomical measurements as follows:

- a. Distance between Contact Point and Bone Crest (CP-BC).
- b. Interdental Distance (IDD).
- c. Embrasure Space Area (EA).
- d. Crown Form (CF).
- e. Papilla Length (PL).

2. To determine the optimal dimensions of interdental embrasure between maxillary incisors so as to be completely filled by normal healthy interdental papilla.

3. To correlate occurrence of food lodgement with Modified Papilla Index Score (PIS) and Embrasure Space Area (EA).

Materials and Methods: 532 patients aged 18-58 years who had fully erupted permanent dentition and healthy gingiva with probing depth ≤ 3 mm were included into the study. Quantitative analysis of interdental papillae were done using clinical parameters along with radiographic examination.

Results: The clinical and radiographic assessment of 1312 interdental papillae revealed that the interdental anatomical factors viz (which are) CP-BC distance, IDD, EA, CF and PL significantly influenced the degree of papilla fill. The study also highlighted the possible occurrence of food lodgement in patients with open embrasures.

Conclusion: Embrasure anatomical parameters and papillary height vary widely among individuals. Interdental papillary deficiency is a relative phenomenon since it is an outcome of net influence of all the other parameters.

Keywords: Embrasures; Interdental papilla; Food lodgement; Papillary height; Crown form; Esthetics.

Introduction

The current trend in dentistry is changing from merely relieving pain and restoring the loss of function to further pursuing the esthetic satisfac-

tion of the patients [1]. Dentists need to meet the esthetic standards that require a symmetric gingival outline harmonizing with the natural dentition, especially in the in-

interdental area [1-5]. The presence or absence of the interproximal papilla is of great concern to periodontists and restorative dentists since it's challenging to achieve optimal esthetics [6]. One of the crucial elements involved in restoring the periodontal apparatus and teeth is restoration of physiologic interdental zone comprised of the contact point, an interproximal embrasure, and interproximal dentogingival complex [4,6,7].

It is the primary site of dental diseases including periodontitis and caries, as it is prone to an accumulation and growth of microbial plaque. This zone is composed of four pyramidal embrasures: cervical, occlusal, buccal and lingual. The cervical embrasure is occupied by an interdental papilla, the physiology of which is more complex than other gingival regions [3,8,10,11,12]. Interdental papilla of the incisor region usually assumes a pyramidal shape or it may pose a slight gingival col depending on the location of the contact area and the height of the gingiva [6]. In cases of loss of the papilla, a clinical condition termed as "black triangle" may lead to lateral food impaction, functional, phonetic and cosmetic problems [3,6,8,13,14]. Endless efforts have been made in the course of periodontal treatment to regenerate the lost interdental papillae. Surgical techniques have been devised to conserve or reconstruct the soft tissue between natural teeth and implants in order to achieve gingival harmony. If the loss of interdental papilla is due to periodontal disease, reconstructive surgical techniques should be performed to restore it. But if the papilla deficiency occurs as a relative phenomenon due to abnormal anatomical factors then, nonsurgical approaches, such as orthodontics, prosthetic, and restorative procedures, should be performed to modify the anatomy and morphological factors of interdental space [3,4,8,11,15].

There is a need to find the risk factors for deficiency of incisor papillae and also to probe into the relationship between embrasure morphology and age-related papilla recession [4]. Many studies have shown that the distance from the contact point to bone crest is significantly related to the presence of interdental or inter-implant papillae [2,5,10-18]. Many clinicians often predict the presence of papillae using the CP-BC distance. In addition to the CP-BC distance, other factors such as age, angulations of the roots of adjacent teeth, the shape of the crown, the space between adjacent teeth, the volume of the embrasure space, and so on also help determine degree of papilla fill [2,3,5,10-18]. This information has been limited to the literature and its clinical application remains questionable; the reason

being, wide variations in the results. Inconsistency in the results may be attributed to inadequate study sample, inclusion of numerous sites that lacked homogeneity or non- inclusion of control group for confounding variables [10]. Due to the growing attention on anterior esthetics by both dentists and patients, there is a need for a study which encompasses the anatomical features of an embrasure and correlates with papilla fill assessed by non-invasive means, in a large study sample. Such a study can have conclusive results that are applicable in a clinical situation. This study has been designed to meet the above parameters. Patients with papilla deficiency often self report with the complaints of food lodgement. It also has been included as one of the parameters.

Materials and Methods

Study Population comprised of 532 patients reporting to the outpatient department of Oral Medicine, Diagnosis and Radiology and the individuals accompanying patients reporting to department of Periodontics, Modern Dental College and Research Centre, Indore, who were randomly selected under following criteria:

Inclusion criteria

1. Fully erupted permanent dentition.
2. Healthy gingiva with probing depth ≤ 3 mm.

Exclusion criteria

1. Gingival inflammation and/or probing depth > 3 mm.
2. History of orthodontic or surgical periodontal treatment.
3. History of medications known to increase risk of gingival hyperplasia.
4. Pregnant/Lactating mothers.
5. Smoking/Tobacco chewing or other tissue abusive habits.
6. Wasting disease (abrasion, attrition, and erosion), artificial crown or restorations with maxillary anterior teeth.
7. Evidence of open contact or tooth overlap at the contact point (as visually observed without aids).
8. Malaligned maxillary anterior teeth.

The patients were explained about the study design and included in the study after obtaining an informed consent. The study protocol was approved by the ethical

committee of Modern Dental College and Research Centre, Indore.

Clinical examination

A total of 1596 interdental embrasures were recorded from 532 patients. The quantitative analysis of interdental papilla was carried out using modified papilla index score (PIS) 32 as follows:

- PIS 0: No papilla present & there is no curvature of the soft tissue contour.
- PIS 1: Convex curvature of the papilla is observed & fills less than half the height of the interdental embrasure.
- PIS 2: Papilla fills half or more than half the height of the interdental embrasure, yet does not fill completely & not in harmony with interdental embrasure space.
- PIS 3: Papilla fills the interdental embrasure completely and is in harmony with interdental embrasure space.

Food Lodgement

Patients' complaints of food lodgement were recorded as 'present' or 'absent' in the areas of concern.

Radiographic Examination

A radiopaque material consisting of Zinc Oxide, Calcium Sulfate, Zinc Sulfate (CaviTemp, Dentsply) was placed on the tip of the papilla with a periodontal probe. Periapical radiographs were taken with standardized paralleling cone technique using film holder (Dentsply Rinn XCP). Exposures were made at 70kV and 15mA at an exposure time of 0.4 to 0.6 seconds. All films were processed in the well-equipped light proof dark room using freshly prepared developer and fixer solutions maintained at $25^{\circ}\text{C}\pm 0.50$. Out of the potential 1596 interdental sites, 284 sites were excluded due to poor radiographic quality owing to handling and processing errors or open contact depicted on radiograph. Hence the effective sample size got concise to 1312 interdental sites.

Radiographic Analysis

Radiographs were digitalized using X-digi IOPA Digitalizer and stored in the JPEG format in the computer by X-digi USB interface software. Measurements pertaining to interdental embrasure were assessed by a single examiner on the same monitor at a resolution of 1,280×600 pixels applying calibrated software, Image J Pro-Express. All the measurements were repeated

thrice and their average was calculated to minimize intra-examiner error. Measurements to determine morphology and anatomy of interdental space: (All the measurements were recorded in millimeters).

1. Distance between Contact Point and Bone Crest (CP-BC): was measured from the most apical part of contact point/area to the most coronal portion of the bone crest.
2. Interdental Distance (IDD): was measured at the most coronal portion of the bone crest.
3. Embrasure Space Area (EA): was obtained as digital output using the software after outlining the relevant space.
4. Crown Form (CF): was obtained as mean mesial divergence ratio of two adjacent teeth calculated by the formula $18: \frac{1}{2}[(d1/d2)+(d3/d4)]$ where, d1=Distance measured perpendicularly from the long axis of the tooth (preceding the embrasure area) to the CEJ at the proximal surface.

d2=Distance measured perpendicularly from the long axis of the tooth (preceding the embrasure area) to the contact point.

d3=Distance measured perpendicularly from the long axis of the tooth (succeeding the embrasure area) to the CEJ at the proximal surface.

d4=Distance measured perpendicularly from the long axis of the tooth (succeeding the embrasure area) to the contact point.

A low CF represents a triangular crown form, whereas a CF near 1 represents a rectangular crown form.

5. Papilla Length (PL): was measured from the tip of the papilla to the most coronal portion of the bone crest.

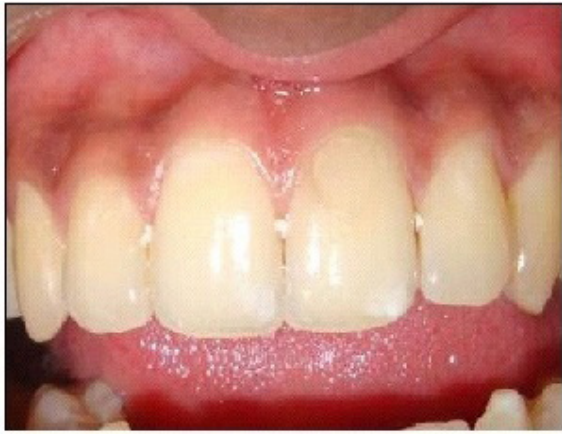

Figure 1. Radiopaque material placed on the tip of of the papillae.

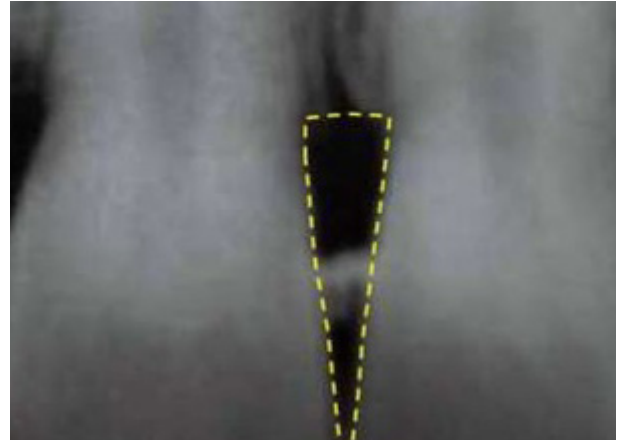


Figure 4. Interdental embrasure area.

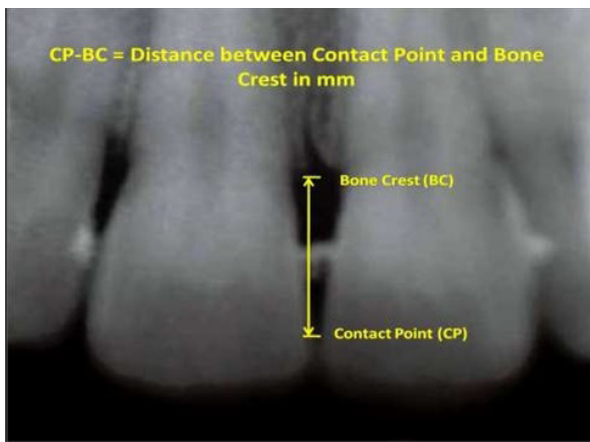


Figure 2. Distance between contact point and Bone crest.

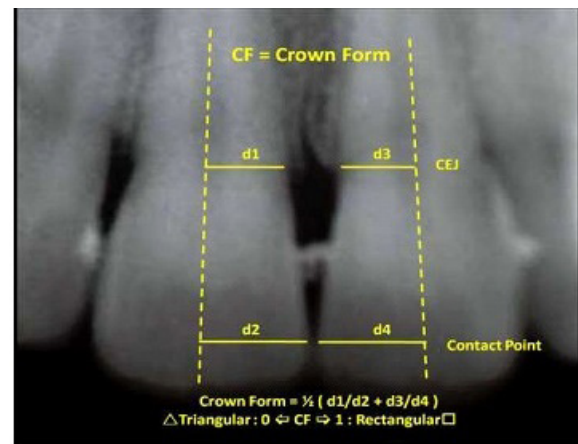


Figure 5. Crown Form.

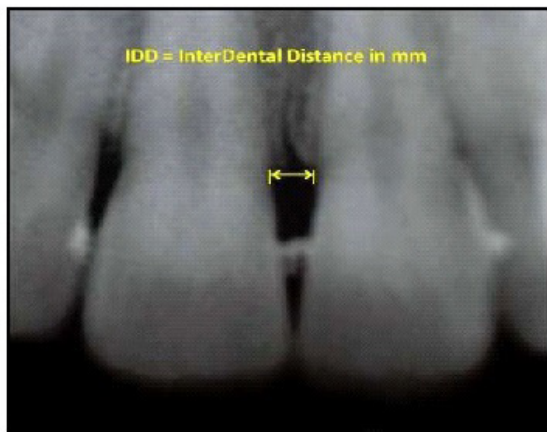


Figure 3. Interdental distance.

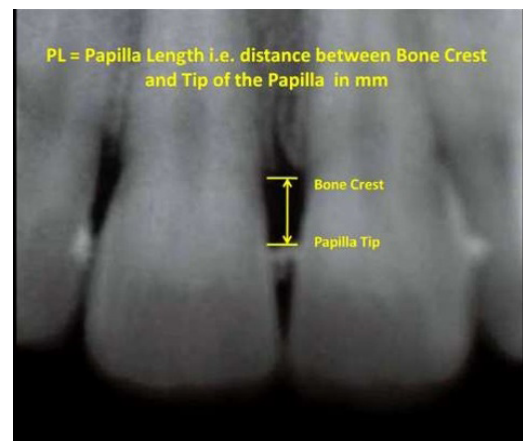


Figure 6. Papilla length.

Statistical Methods

The individual interdental sites were regarded as a statistical unit. The data obtained was subjected to Karl Pearson's coefficient correlation test for correlating modified papilla index score with interdental anatomical factors. Occurrence of food lodgement according to the distribution of modified papilla index score and embrasure space area was assessed by Karl Pearson's chi-square test. All analysis was done using SPSS Statistical Software Package Version 10.0 and probability value (p-value) of less than 0.05 was considered as statistically significant and less than 0.001 as highly significant.

Karl Pearson's coefficient correlation test:

$$r = \frac{\sum_{i=1}^n (X_i - \bar{X})(Y_i - \bar{Y})}{\sqrt{\sum_{i=1}^n (X_i - \bar{X})^2} \sqrt{\sum_{i=1}^n (Y_i - \bar{Y})^2}}$$

Karl Pearson's chi-square test:

$$\chi^2 = \sum_{i=1}^n \frac{(O_i - E_i)^2}{E_i}$$

Results

A total of 1312 interdental sites were recorded from 532 patients and were subjected to clinical assessment and radiographic measurements. 779 (59%) sites belonged to male patients and 533 (41%) sites belonged to female patients (Graph 1). The age range for the entire study population was from 18 to 58 years. The modified papilla index score in the present study population is as follows. Out of 1312 sites, 158 (12%) sites were scored PIS 1; 582 (44.4%) sites were scored PIS 2 and 572 (43.6%) sites were scored PIS 3. None of the sites had complete loss of interdental papilla i.e. PIS 0.

Table I represents the mean values of interdental anatomic factors of the study population distributed along with PIS 1, 2 & 3. It was observed that when the following anatomic measurements i.e. Distance between Contact Point and Bone Crest (CP-BC), Interdental Distance (IDD) and Embrasure Space Area (EA) increased, the incidence of papilla fill decreased. Thus the mean anatomic factors measurements decreased with an increase in the PIS. For the Papilla Length (PL), there was a direct correlation between the PL & PIS wherein it was seen that as the mean PL increased, the PIS increased. For the Crown Form ratio (CF), the mean CF remained the same (0.75) for PIS 1 & 2 while there was an increase in the CF for PIS 3 (0.79).

Table II represents correlation of PIS with interden-

tal anatomical factors. When PIS was correlated with CP-BC, IDD & EA, a negative correlation was obtained which was highly significant (p=0.000). Thus as the CP-BC distance, IDD & EA decreased, a significant papilla fill in the interdental embrasure space was seen. There was no statistical significance achieved between PIS & PL (p=0.039), though PIS increased with increasing PL as seen in table II. When PIS was correlated with CF, a highly significant relation (p=0.000) was obtained implying that as the CF ratio increased towards 1 (rectangular crown form), papilla fill in the interdental embrasure space would increase significantly. Table III represents the inter-correlation of interdental anatomic factors which revealed the following: When the CP-BC distance was correlated with other interdental anatomic factors, it showed a highly significant correlation with IDD, EA & CF (p=0.000). Thus as the CP-BC distance increased, IDD & EA increased and the CF ratio decreased towards 0 (triangular crown form). No statistical significance was achieved with PL (p=0.81). IDD & EA showed statistically significant correlation with all the interdental anatomic factors. As IDD increased, the EA also significantly increased (p=0.000). Further when both these factors increased, a significant decrease in PL (p=0.024 & 0.019 respectively) and CF ratio (p=0.000) towards 0 (triangular crown form) was noted. CF ratio too revealed a highly significant correlation with PL (p=0.009) implying, as the CF ratio increased towards 1, PL too increased.

Table IV represents incidence of papilla fill according to EA. EA was divided into 4 categories as 2 to 3.9sqmm, 4 to 5.9sqmm, 6 to 7.9sqmm & ≥8sqmm and was correlated with the PIS. While 95.6% sites with EA between 2 to 3.9sqmm had complete papilla fill (PIS 3), the percentage of sites with PIS 3 decreased as the EA increased. Accordingly only 5.8% sites with EA between 6 to 7.9sqmm had complete papilla fill & none of the sites showed papilla fill when EA was ≥8sqmm. Further, this decrease in the incidence of sites with complete papilla fill (PIS 3) as the EA increased was highly significant (p=0.000)

Table V: When incidence of FL was observed according to PIS & EA, the relation though was not statistically significant (p=0.268 & p=0.427 respectively), it was observed that as the papilla fill in the interdental embrasure space increased i.e. with an increasing PIS, there was a relative decrease in the incidence of food lodgement. Similarly it was also seen that as the area of the interdental embrasure space increased, the incidence of food lodgement also increased.

Table I. Measurements of Interdental anatomic factors of the study population.

Variables	PIS	Mean±SD
CP-BC (mm)	1	7.80±1.16
	2	6.56±0.68
	3	5.10±0.31
IDD (mm)	1	2.12±0.68
	2	1.91±0.57
	3	1.16±0.30
EA (mm ²)	1	10.81±3.10
	2	7.48±2.30
	3	4.45±0.82
CF (ratio)	1	0.75±0.08
	2	0.75±0.06
	3	0.79±0.11
PL (mm)	1	3.77±0.72
	2	4.46±0.49
	3	4.58±0.37

Table II. Correlation of modified papilla index score with interdental anatomical factors (Karl Pearson's Correlation Test).

		CP-BC (mm)	IDD (mm)	EA (mm ²)	CF (ratio)	PL (mm)
PIS	Pearson's Correlation (Sig)	-0.824** (0.000) (HS)	-0.604** (0.000) (HS)	-0.736** (0.000) (HS)	0.221** (0.000) (HS)	0.039 (0.161)

** Correlation is significant at the 0.01 level (2-tailed).

Table III. Inter-correlation of interdental anatomical factors (Karl Pearson's Correlation Test).

		PL (mm)	CF (ratio)	EA (mm ²)	IDD (mm)
CP-BC (mm)	Pearson's Correlation (Sig)	-0.007 (0.810) (S)	-0.266** (0.000) (HS)	0.780** (0.000) (HS)	0.650** (0.000) (HS)
IDD (mm)	Pearson's Correlation (Sig)	-0.062* (0.024) (S)	-0.299** (0.000) (HS)	0.822** (0.000) (HS)	
EA (mm ²)	Pearson's Correlation (Sig)	-0.065* (0.019) (S)	-0.249** (0.000) (HS)		
CF (ratio)	Pearson's Correlation (Sig)	0.072** (0.009) (HS)			

** Correlation is significant at the 0.01 level (2-tailed).

* Correlation is significant at the 0.05 level (2-tailed).

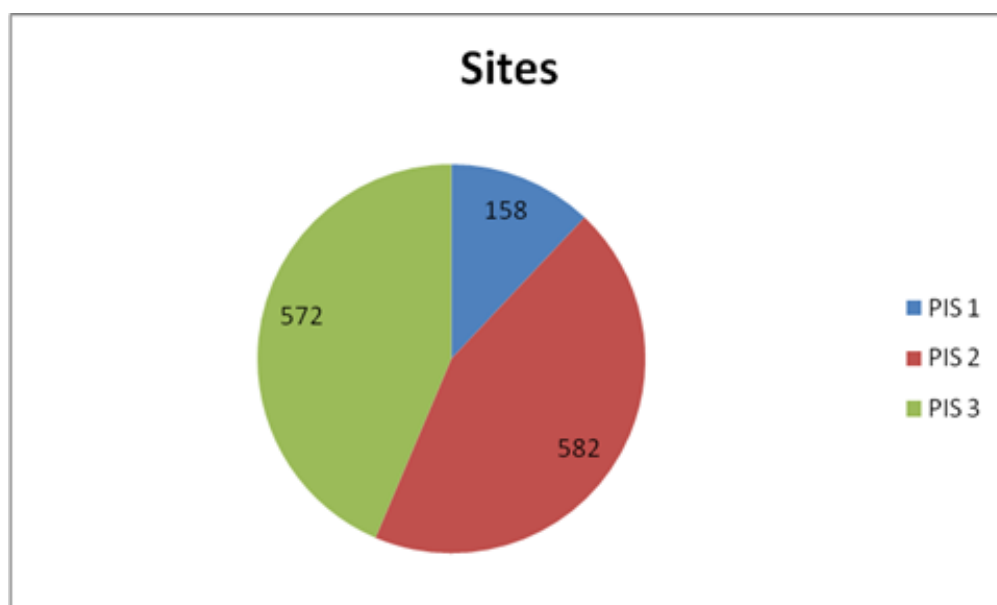
Table IV. Incidence of papilla fill according to embrasure area.

EA (mm ²) (N=No of Sites)	PIS			Chi-Square Value	p value
	1	2	3		
2-3.9 (N=135)	0 (0%)	6 (4.4%)	129 (95.6%)	914.217**	0.000 (HS)
4-5.9 (N=614)	14 (2.3%)	172 (28%)	428 (69.7%)		
6 - 7.9 (N=259)	15 (5.8%)	229 (88.4%)	15 (5.8%)		
≥ 8 (N=304)	129 (42.4%)	175 (57.6%)	0 (0%)		

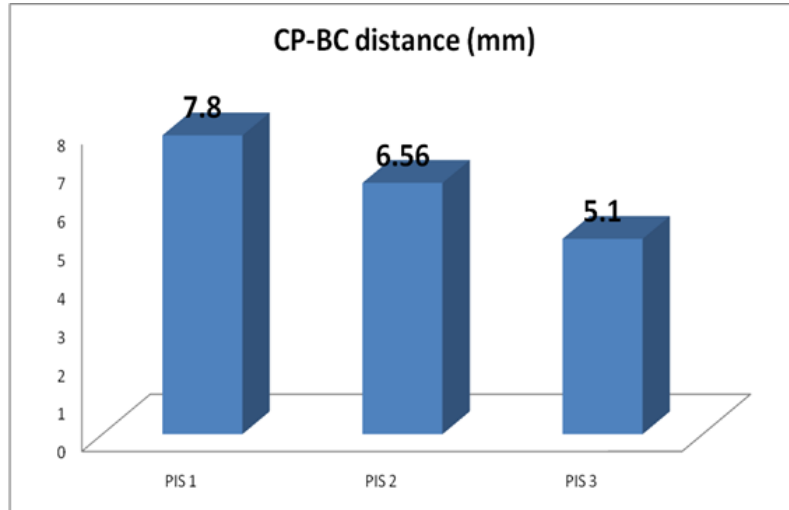
** Correlation is significant at the 0.01 level (2-tailed).

Table V. Incidence of Food Lodgement according to modified papilla index score and embrasure space area.

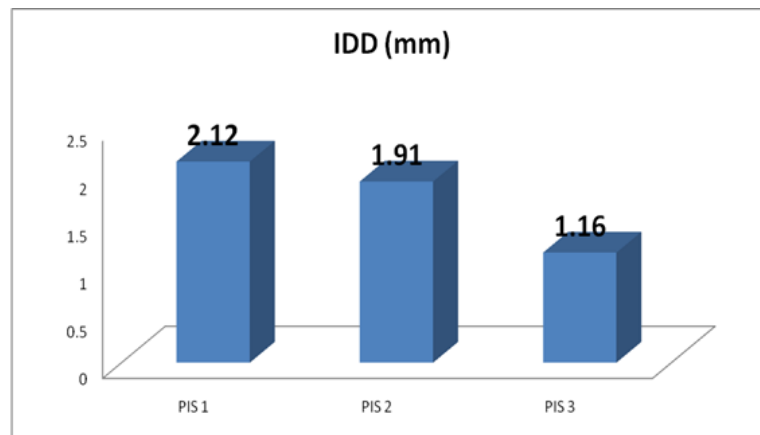
		No of sites with the presence of Food Lodgement N (%)	Chi-Square Value	p value
PIS	1	60 (38%)	2.634	0.268
	2	181 (31.6%)		
	3	183 (31.4%)		
EA (mm ²)	1	42 (31.1%)	2.778	0.427
	2	193 (31.4%)		
	3	84 (31.8%)		
	≥8	110 (36.2%)		

Graph 1. Distribution of modified papilla index score in the study population.

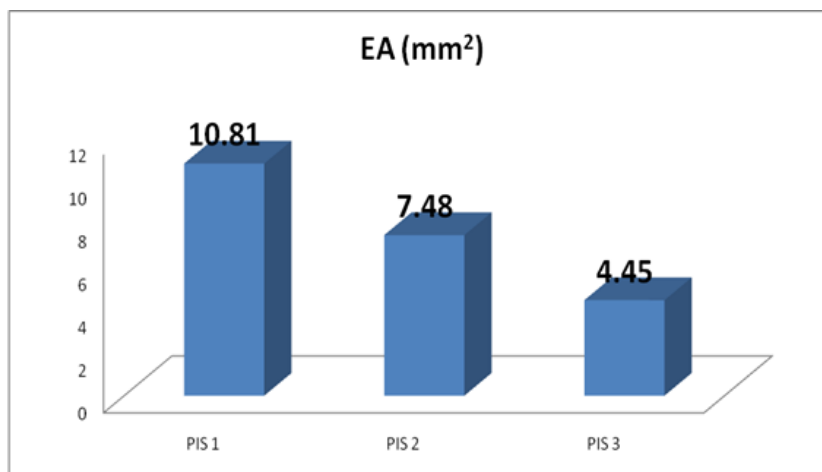
Graph 2. Distribution of mean CP-BC Distance (mm) with respect to modified papilla index score.



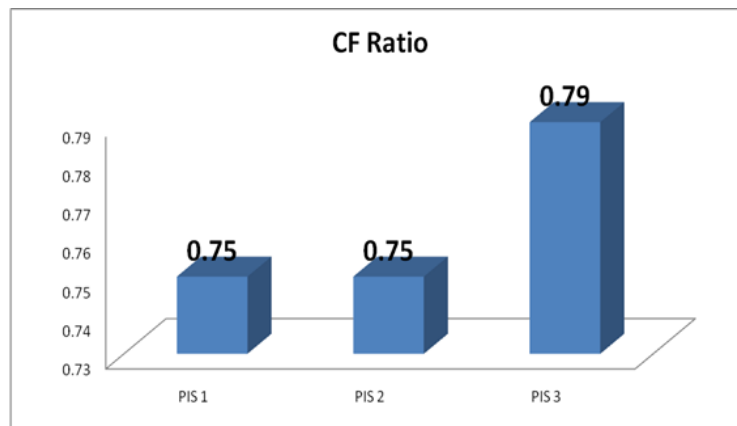
Graph 3. Distribution of mean interdental distance (mm) with respect to modified papilla index score.



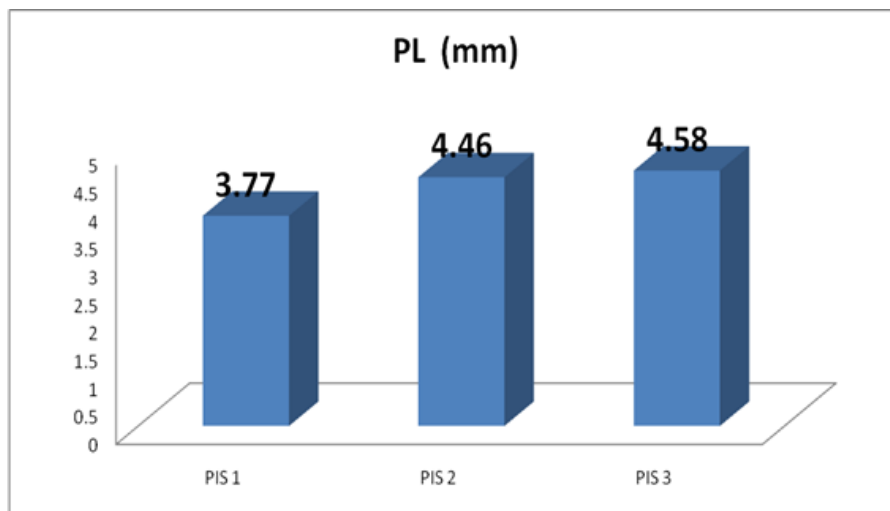
Graph 4. Distribution of mean embrasure area (mm²) with respect to modified papilla index score.



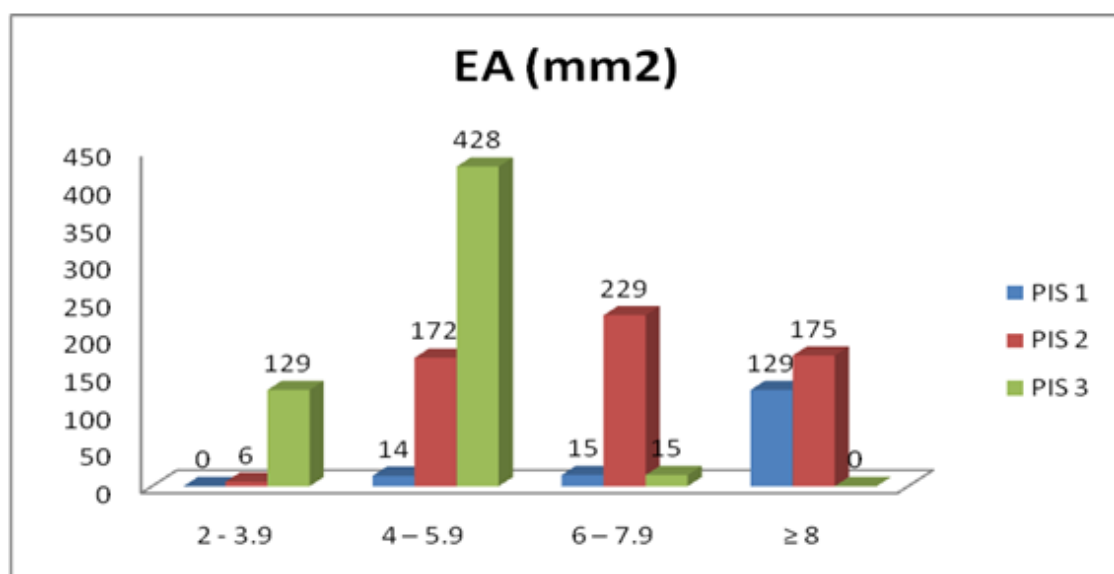
Graph 5. Distribution of mean crown form (ratio) with respect to modified papilla index score.



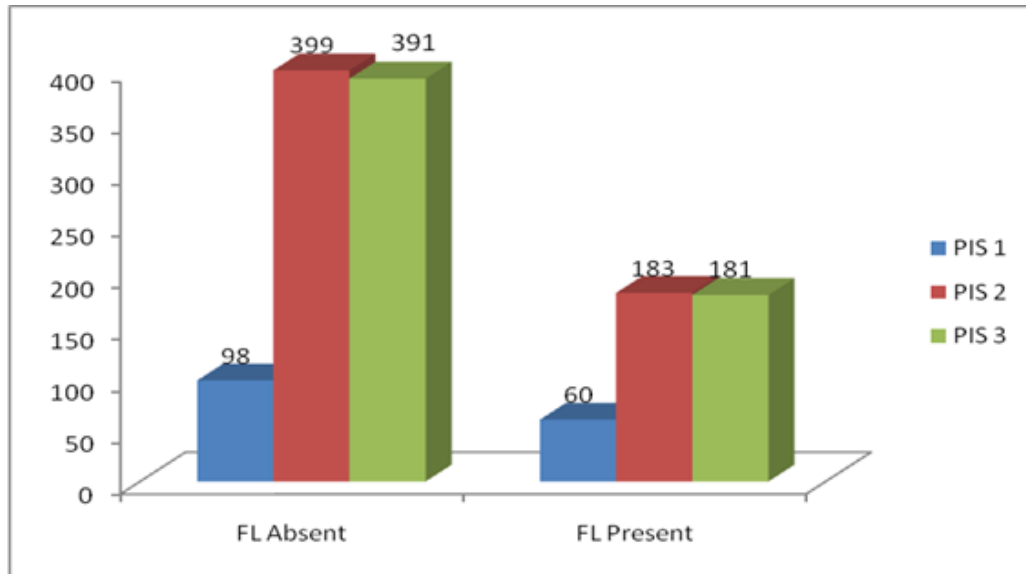
Graph 6. Distribution of mean papilla length (mm) with respect to modified papilla index score.



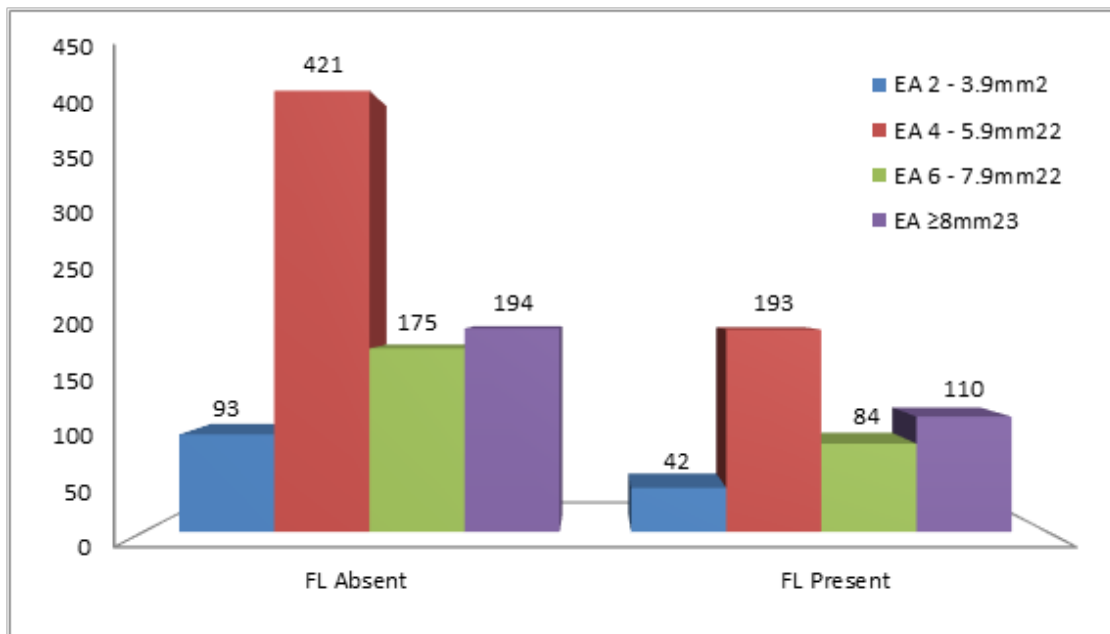
Graph 7. Incidence of papilla fill according to embrasure space area (mm²)



Graph 8. Distribution of mean embrasure area (mm²) with respect to modified papilla index score.



Graph 9. Incidence of Food Lodgement according to embrasure space area (mm²)



Discussion

The presence or recession of the interdental papilla especially in the maxillary anterior region is of concern to both dentists and patients. Several factors influence the complete fill of the papilla in the interdental embrasure space. The present study aimed at determining the influence of such interdental anatomical and morphological factors on the papilla fill in the interdental embrasure space where subjects aged 18-58 years underwent clinical examination and radiographic assessment of the maxillary anterior region. The interdental anatomical measurements assessed in the present study were distance between contact point and bone crest (CP-BC distance), interdental distance (IDD),

interdental embrasure area (EA), crown form (CF) and papilla length (PL). Researchers have recorded these factors using invasive and non-invasive methods. The former method includes assessment of these factors after surgically reflecting the periodontal flap 13 or by bone sounding [1,17]. Among the latter methods, researchers have measured the factors directly on intraoral periapical radiographs using a ruler [3-6,9,10,12,15,16] or grid method [25]. Though IOPAs offer noninvasive means of measurements, their accuracy remains questionable. Some degree of marginal error is assumed to be associated in spite of the use of grids. Alternatively, recent studies have recommended to measure by digitizing the radiographs and record-

ing them on a computer. Literature search has revealed only one study 18 to have digitized intraoral periapical radiographs and assessed the interdental anatomical factors using a computer. Hence, in the present study, IOPAs obtained by paralleling cone technique were digitized and analyzed with the help of a calibrated software (Image J Pro-Express), that served as a standard tool. The results of the present study revealed significant relationship of the interdental papilla with the interdental anatomical measurements which are CP-BC distance, IDD, EA, CF and PL.

The following are important considerations with regard to the study objectives:

- A.** Influences of interdental anatomical and morphological factors on modified papilla index score (PIS) and optimal values of interdental anatomical measurements required for complete fill of papilla.
- B.** Assessment of interdental embrasure area, degree of papilla fill and their correlation with incidence of food lodgement.
- C.** Intercorrelation of the interdental anatomical factors.

Since periapical radiographs are commonly taken for certain dental procedure and are often necessary to discuss the treatment plan with the patient, they may serve as an additional diagnostic tool to determine the embrasure area and interdental distance. In situations where digitizing the radiographs is not possible, the measurements can directly be made on the radiographs using a graduated periodontal probe or simply a ruler. Within the limitations of the present study, the optimal measurements obtained may be very useful in the diagnosis and treatment of the open interdental embrasure space and surgical reconstruction of the papilla wherein no invasive or complicated aid has to be used by the clinician.

Conclusion

The clinical and radiographic assessment of 1312 interdental papillae revealed the following:

- a)** CP-BC distance, IDD, EA, CF and PL significantly influenced the degree of papilla fill.
- b)** Out of these factors, CP-BC distance, IDD and EA had an inverse influence on the degree of papilla fill, whereas CF and PL had a direct influence.
- c)** The optimal values of these parameters in order to achieve complete fill of the papilla were elucidated as 5.1mm for CP-BC distance, 1.16mm for IDD, 4.45mm²

for EA, 0.79 for CF and 4.58mm for PL; beyond which papilla will not be able to completely fill the interdental embrasure space.

- d)** Furthermore, the intercorrelation of these factors showed that the CP-BC distance and IDD had a linear correlation and both these factors directly influence the EA.
- e)** A triangular crown form depicted an increased CP-BC distance, increased IDD and eventually increased EA.
- f)** PL reduced with an increase in IDD, EA and triangular crown form.
- g)** The present study highlighted the possible occurrence of food lodgment in patients with open embrasures.

There is no constant value for embrasure anatomical parameters and papillary height will vary widely among individuals. These parameters influence each other independently or in combination. Interdental papillary deficiency may be considered a relative phenomenon since it is an outcome of net influence of all the other parameters.

Based on these conclusions, the directions for the treatment planning would be as follows:

- If the open embrasure space is due to soft tissue (papilla) deficiency where the interdental anatomical factors are within their optimal limits, then surgical reconstruction of the papilla can be attempted. However, papilla loss due to disease process has to be dealt with regenerative techniques.
- If an open embrasure space is resultant of interdental anatomical factors extending beyond the illustrated optimal values, then orthodontic, prosthodontic or restorative treatment should be employed to restore the interdental anatomical values to achieve an $EA \leq 4.45\text{mm}^2$ (approximately) to be completely filled by papilla.

Conflict of Interest

There is no conflict of interest to declare.

References

- [1] Cho HS, Jang SH, Kim DK et al. The effect of interproximal distance between roots on the existence of interdental papillae according to the distance from the contact point to the alveolar crest. *J Periodontol* 2006; 77:1651-1657.

- [2] Choquet V, Hermans M, Adriaenssens P, Daelemans P, Tarnow DP, Malevz C. Clinical and radiographic evaluation of the papilla level adjacent to single-tooth dental implants: A retrospective study in the maxillary anterior region. *J Periodontol* 2001; 72:1364-1371.
- [3] Chang LC. The presence of a central papilla is associated with age but not gender. *J Dent Sci* 2006; 1:161:167.
- [4] Chang LC. Age-Related Central Papilla Recession in Different Embrasure Morphologies. *Chin J Periodontol* 2007; 12:71-82.
- [5] Martegani P, Silvestri M, Mascarello F et al. Morphometric study of the interproximal unit in the esthetic region to correlate anatomic variables affecting the aspect of soft tissue embrasure space. *J Periodontol* 2007; 78:2260-2265.
- [6] Wu YJ, Tu YK, Huang SM and Chan CP. The influence of the distance from the contact point to the crest of bone on the presence of interproximal dental papilla. *Chang Gung Med J* 2003; 26:822-8.
- [7] Lee DW, Kim CK, Park KH, Cho KS and Moon IS. Non-invasive method to measure the length of soft tissue from the top of the papilla to the crestal bone. *J Periodontol* 2005; 76:1311-1314.
- [8] Prato GP, Rotundo R, Cortellini P, Tinti C, Azzi R. Interdental papilla management: A review and classification of the therapeutic approaches. *Int J Periodontics Restorative Dent* 2004; 24:246-255.
- [9] Chang LC. The central papilla height in association with age and gender – assessed with a new method. *Chin J Periodontol* 2006; 11:271:279.
- [10] Chang LC. Assessment of parameters affecting the presence of the central papilla using a non-invasive radiographic method. *J Periodontol* 2008; 79:603-609.
- [11] Zetu L, Wang HL. Management of inter-dental/inter-implant papilla. *J Clin Periodontol* 2005; 32:831-839.
- [12] Chang LC. Criteria for predicting the presence of the central papilla by a noninvasive method. *J Dent Sci* 2007; 2:88-96.
- [13] Tarnow DP, Magner AW, Fletcher P. The Effect of the Distance From the Contact Point to the Crest of Bone on the Presence or Absence of the Interproximal Dental Papilla. *J Periodontol* 1992; 63:995-996.
- [14] Cardaropoli D, Stefania MD and Corrente G. The Papilla Presence Index (PPI): A new system to assess interproximal papillary levels. *Int J Periodontics Restorative Dent* 2004; 14:488-492.
- [15] Chang LC. The association between embrasure morphology and central papilla recession. *J Clin Periodontol* 2007; 34:432-436.
- [16] Kurth JR and Kokich VG. Open gingival embrasures after orthodontic treatment in adults: Prevalence and etiology. *Am J Orthod Dentofacial Orthop* 2001; 120:116-23.
- [17] Gastaldo JF, Cury PR and Sendyk WR. Effect of the vertical and horizontal distance between adjacent implants and between a tooth and an implant on the incidence of interproximal papilla. *J Periodontol* 2004; 75:1242-1246.
- [18] Chen MC, Liao YF, Chan CP et al. Factors influencing the presence of interproximal dental papillae between maxillary anterior teeth. *J Periodontol* 2010; 81:318-324.
- [19] Cohen B. Morphological factors in the pathogenesis of periodontal disease. *Brit Den J* 1959; 107:31-39.
- [20] Kohl JT, Zander HA. Morphology of interdental gingival tissues. *Oral Surg Oral Med Oral Pathol* 1961; 60:287-295.
- [21] Matherson DG, Zander HA. Evaluation of osseous surgery in monkeys. *J Dent Res* 1963; 42 (Spec. Issue) 116.
- [22] Stahl SS. Morphology and healing pattern of human. *NY State Dent J* 1963; 29:307-311.
- [23] Lee DW, Park KH and Moon IS. Dimension of keratinized mucosa and the interproximal papilla between adjacent implants. *J Periodontol* 2005; 76:1856-1860.
- [24] Ryser MR, Block MS and Mercante DE. Correla-

- tion of papilla to crestal bone levels around single tooth implants in immediate or delayed crown protocols. *J Oral Maxillofac Surg* 2005; 63:1184-1195.
- [25] Chow YC, Eber RM, Tsao YP et al. Factors associated with the appearance of gingival papillae. *J Clin Periodontol* 2010; 37:719-727.
- [26] Montevicchi M, Checchi V, Piana L et al. Variables Affecting the Gingival Embrasure Space in Aesthetically Important Regions: Differences between Central and Lateral Papillae. *The Open Dentistry Journal* 2011; 5:126-135.
- [27] Nozawa T, Yamaguchi S, Ookame Y et al. The distances between the facial and palatal papillae in the maxillary anterior dentition. *Eur J Esthet Dent* 2011; 6:88-93.
- [28] Nordland WP and Tarnow DP. A classification system for loss of papillary height. *J Periodontol* 1998; 69:1124-1126.
- [29] Jemt T. Regeneration of gingival papillae after single-implant treatment. *Int J Periodont Rest Dent* 1997; 17:327-333.
- [30] Nemcovsky CE, Moses O and Artzi Z. Interproximal papillae reconstruction in maxillary implants. *J Periodontol* 2000; 71:308-314.
- [31] Nemcovsky CE. Interproximal Papilla Augmentation Procedure: A Novel Surgical Approach and Clinical Evaluation of 10 Consecutive Procedures. *Int J Periodontics Restorative Dent* 2001; 21:553-559.
- [32] Kanteshwari IK. A Modified Horizontal Gingival Incision: An approach to Endo-Perio lesions-Two case reports. *J PFA* 2011; 25:35-44.
- [33] Salama H, Salama MA, Garber D, Adar P. The interproximal height of bone: a guidepost to predictable aesthetic strategies and soft tissue contours in anterior tooth replacement. *Pract Periodontics Aesthet Dent* 1998; 10(9):1131-41.
- [34] Heins PJ and Wieder SM. A Histologic Study of the Width and Nature of Inter-radicular Spaces in Human Adult Pre-molars and Molars. *Journal of Dental Research* 1986; 65:6948-951.
- [35] LaSota EP. Orthodontic considerations in prosthetic and restorative dentistry. *Dental Clinics of North America* 1988; 32(3):447-456.
- [36] Kokich VG. Esthetics: The Orthodontic-Periodontic Restorative connection. *Seminars in Orthodontics* 1966; 2(1):21-30.
- [37] Kois JC. Predictable single tooth peri-implant esthetics: five diagnostic keys. *Comp of Cont Edu in Dent* 2001; 22(3):199-206.
- [38] Kois JC, Kan JY. Predictable peri-implant gingival aesthetics: surgical and prosthodontic rationales. *Pract Proced Aesthet Dent*. 2001; 13(9):691-8.
- [39] Kois JC. Predictable single tooth peri-implant esthetics: five diagnostic keys. *Comp of Cont Edu in Dent* 2004; 25(11):895-906.
- [40] Atherton JD. The gingival response to orthodontic tooth movement. *American Journal of Orthodontics* 1970; 58:179-186.
- [41] Clark DJ. Restoratively Driven Papilla Regeneration: Correcting the Dreaded "Black Triangle". *Canadian Journal of Restorative Dentistry and Prosthodontics* 2008; Aug:21-27.
- [42] Tarnow D, Elian N, Fletcher P, Froum S, Magner A, Cho SC, Salama M, Salama H and Garber DA. Vertical Distance from the Crest of the Bone to the Height of the Interproximal Papilla Between Adjacent Implants. *J Periodontol* 2003; 74:1785:17

Please cite this paper as:

Kedia S, Kanteshwari K, Raja S, Parwani S, Tekade Iranaq S, Warekar A; Influence of interdental embrasures on interdental papilla. *J Craniomaxillofac Res* 2021; 8(4): 197-209