



## Traumatic ophthalmic injuries ophthalmic injuries in mid-facial trauma: A decade long survey

Ramin Foroughi<sup>a\*</sup>, Forouzan Faghani<sup>b</sup>, Sara Gharib<sup>c</sup>, Soraya Khafri<sup>d</sup>

<sup>a</sup> Department of Oral and Maxillofacial Surgery, Dental Material Research Center, Shahid Beheshti Hospital, University of Babol, Babol, Iran

<sup>b</sup> Dental Student, School of Dentistry, Babol University of Medical Sciences, Babol, Iran

<sup>c</sup> Department of Ophthalmology, Ayatollah Rohani Hospital, Babol University of Medical Sciences, Babol, Iran

<sup>d</sup> Department of Biostatic and Epidemiology, School of Medicine, Babol University of Medical Sciences, Babol, Iran

### ARTICLE INFO

Article Type:

Original Article

Received: 31 May 2015

Revised: 27 Jun 2015

Accepted: 29 Jul 2015

\*Corresponding author:

Ramin Foroughi

Department of Oral and Maxillofacial Surgery, Shahid Beheshti Hospital, University of Babol, Babol, Iran

Tel: +98-1132291408

Fax: +98-1132291408

Email: raminomfs99@yahoo.com

### ABSTRACT

**Introduction:** The main purpose of this study was to evaluate the prevalence of ophthalmic injuries associated with mid-facial fractures in patients admitted to Shahid Beheshti University Hospital in Babol, Iran, from 2002 to 2012.

**Materials and Methods:** A cross-sectional, retrospective study was undertaken to determine the prevalence of ophthalmic injuries associated with mid-facial fractures in patients admitted to a university hospital over a decade (2002-2012). Relevant data, including history, operation notes, and consultation sheets, were collected using patients' medical records. The types and frequencies of maxillofacial and concurrent ophthalmic injuries were derived and represented by figures and percentages.

**Result:** A total of 196 medical charts of patients with mid-facial trauma were reviewed. Coexistent ophthalmic injuries were seen in 106 cases (93 males and 13 females). The mean age at the time of trauma was  $31.01 \pm 12.40$ . The most common cause of mid-facial trauma was motor-vehicle accidents (85.5%). Patients as a whole had 169 fractures. A bilateral orbital fracture was the most common fracture detected in this study (37.4% of the patients). Overall, 197 ophthalmic injuries were observed. Peri-orbital ecchymosis (68.3%) and blurred vision (12%) were the most common types of minor and major injuries, respectively.

**Conclusion:** Serious ophthalmic injuries, such as permanent visual loss, retinal hemorrhage, laceration of cornea, and globe rupture, were at the low ebb in this survey; however, they must be ruled out in all mid-facial fractures by meticulous ophthalmologic examination. Because mid-facial fractures are potentially detrimental to orbital contents, an ophthalmologic consultation is mandatory and must be prioritized before embarking on performing maxillofacial surgical interventions.

**Keywords:** Ophthalmic Injuries, Mid-facial Fractures, Zygomaticomaxillary Complex Fractures

### Introduction

The face, orbit, and eyes have a relatively prominent position in the human body making this area more susceptible to trauma. A variety of ophthalmic injuries associated with mid-facial fractures has been reported in the literature [1, 2]. This wide range of reported ophthalmic injuries may be caused by numerous factors such as the retrospective paradigm of most studies, distinct methods of classification, and diversity of clinical ophthalmologic examinations [3]. The severity of an injury is

related to the site of the fracture and direction of the incoming force. The outcome may range from mild injury such as sub-conjunctival hemorrhage (SCH) to severe damage like globe rupture or permanent visual loss [1, 4].

Ophthalmic injuries can be divided into minor and major groups based on the possibility of causing permanent visual loss [5]. SCH, peri-orbital ecchymosis, ptosis, crepitation, and laceration of the eyelids are considered as minor injuries. Laceration of the sclera and cornea, ophthalmic infection, traumatic injury of the optic nerve, globe rupture, limitation of eye movements, enophthalmos, proptosis, blurred vision,

diplopia, retinal hemorrhage, hyphema, and permanent visual loss are categorized as major injuries. Motor-vehicle accidents, assault, falling down injuries, occupational, and sport accidents are generally considered as common etiologies of maxillofacial fractures. Early diagnosis of potentially serious ophthalmic injuries is paramount not only in minimizing long-term complications of mid-facial fractures but also from a medico-legal standpoint. The management of the ophthalmic injuries must be considered as the first priority. Repairing the fractures before treatment of ophthalmic injuries may further compromise visual outcomes, leading to visual loss [5].

Signs and symptoms are usually helpful in diagnosing ophthalmic injuries, but occasionally due to the severity of the incoming trauma, patients may not be able to describe their symptoms as they may be unconscious or intubated [6].

Therefore, considering the fact that potentially serious ophthalmic injuries may ensue in mid-facial fractures, and may inadvertently be overlooked, a retrospective study was designed to evaluate the prevalence of such injuries in patients admitted to a university hospital over a decade (2002-2012).

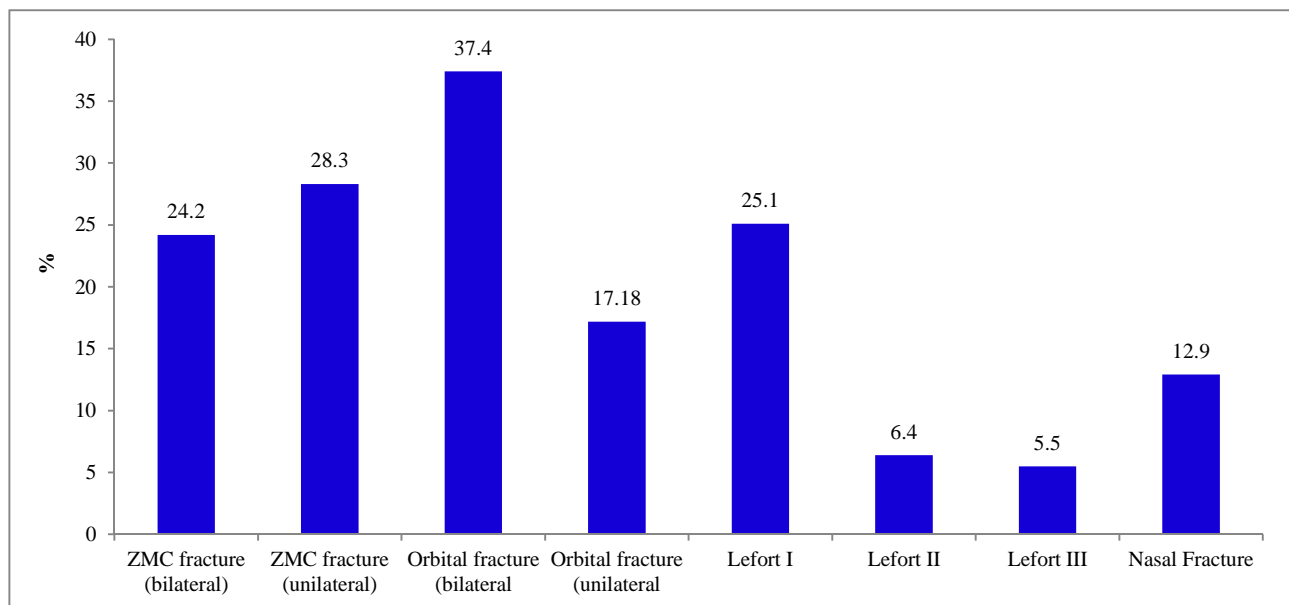
## Material and Methods

A cross-sectional, retrospective study was conducted to investigate the prevalence of associated ophthalmic injuries in patients admitted with mid-facial fractures, in a university hospital during 2002-2012. Data were collected using patients' medical records filed upon admission to the hospital. Most of the information obtained was derived from patients' history, operation notes, and consultation sheets. Collected data were categorized based on age, gender, etiology of injury, type of mid-facial fracture, and type of ophthalmic injury. All types of mid-facial fracture were

included in the study except for isolated nasal fractures. The variables frequencies represented by figures and percentage.

## Results

This study comprised 196 medical records pertaining to mid-facial trauma patients among which 106 cases with concurrent ocular injuries were detected. The mean age at the time of trauma was  $31.01 \pm 12.43$ , and the sex distribution was 93 males to 13 females. Common etiologic factors of the mid-facial trauma included motor-vehicle accident (85.5%), assault (6.6%), falling down (3.8%), sport accidents (1.9%), and occupational accidents (1.9%). Patients as a whole had 169 fractures including zygomaticomaxillary complex (ZMC) fracture, maxillary fracture, orbital fracture, and nasal fracture. 64 cases had multiple fractures in two or three sites of the facial skeleton (Figure 1). The bilateral orbital fracture was the most common fracture detected in this study (37.4%). Many patients had more than one type of ocular injury. Altogether, 197 ophthalmic injuries were recorded from the charts. Most patients had minor injuries such as peri-orbital ecchymosis (68.3%) and SCH (43%). Major injuries such as globe rupture (1.8%), retinal hemorrhage (4.5%), and permanent visual loss (2.7%) were infrequent. Symptomatic diplopia was noted in 7 cases (6.6%) and traumatic optic nerve injury was detected in 3 cases (2.7%) (Figure 2). It was determined that motor-vehicle accidents had led to the injury in 83.9% of males and 100% of females. It was also noted that 25% of victims injured by falling down had permanent loss of vision and that peri-orbital ecchymosis was seen in 100% of cases of assaults (Table 1). Permanent visual loss, retrobulbar hemorrhage, proptosis, orbital infection, erythema, and pruritus were not detected in females suffering from ophthalmic injuries (Figure 3).



**Figure 1.** Frequency of mid-facial fractures (due to association of numerous ophthalmic injuries with some victims total sum of the percentages is more than 100)

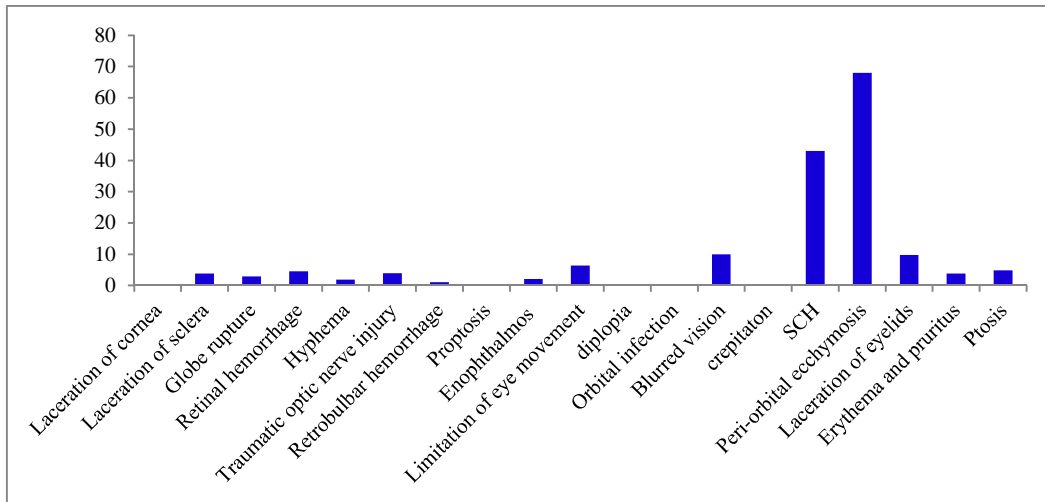


Figure 2. Frequency of ocular injuries (due to association of numerous ophthalmic injuries with some victims total sum of the percentages is more than 100)

Table 1. Frequency of ophthalmic injuries (in percent) based on the etiologic factor

Ophthalmic injuries	Etiologic factor				
	Motor- vehicle accident	Assault	Falling down	Occupational accident	Sport accident
Permanent visual loss	2.2		25		
Laceration of cornea	2.2				
Laceration of sclera	2.2	14.3			
Globe rupture	2.2				
Retinal hemorrhage	5.5				
Hyphema	1.1				
Traumatic optic nerve injury	2.2			50	
Retrobulbar hemorrhage				50	
Proptosis	1.1		25		
Enophthalmos	1.1	14.3			
Limitation of eye movement	6.6	14.3			
Crepitation	1.1		25		
SCH	45.1	42.9	25		50
Peri-orbital ecchymosis	67.1	100	75	50	50
Ptosis	5.5			50	
Laceration of eyelids	9.9			50	50
Infection	2.2			25	
Blurred vision	9.9	57.2			
Erythema and pruritus	4.4		25		
Diplopia	6.6	14.3			

SCH: Sub-conjunctival hemorrhage

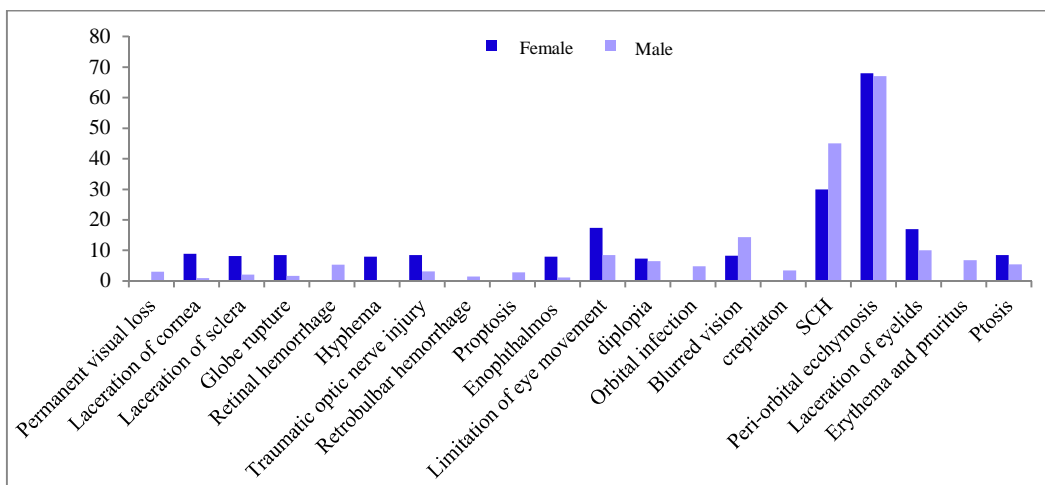


Figure 3. Distribution of ocular injuries in males and females

## Discussion

Several studies have been carried out with the aim of investigating the prevalence of associated ophthalmic injuries in maxillofacial fractures. Because ophthalmic injuries are diverse and numerous, and can range from mild to severe, and since there has been no uniform consensus in classifications used by various researchers, we encountered difficulties in comparing the present study with other researches [4]. Nonetheless, we performed retrospective chart review by studying diverse variables such as age, sex distribution, etiology of trauma, and the type of fracture [5].

High prevalence of concomitant ophthalmic injuries in mid-facial fractures can be noted in many studies [7]; however, most of these studies have focused on a specific ophthalmic injury like diplopia or traumatic optic nerve injury. Urolagin et al. [8] found that the probability of optic nerve injuries in maxillofacial trauma was 2.25%; in our study, we found that 2.7% of patients had an optic nerve injury.

Zachariades et al. [9] reported that the Le-Fort Type III fracture to be the main reason of permanent visual loss in their study; while zygomatic fracture was considered as the main cause in the study of Magarakis et al. in 2012 [2]. The results of our study showed only 3 cases out of 168 patients had permanent visual loss, 2 of which were caused by Le-Fort Type II fractures.

We classified ophthalmic injuries as minor and major, similar to the study of Jamal et al. [5] that analyzed 96 victims with ZMC fractures. According to this classification, our study showed minor injuries such as SCH in 43%, laceration of eyelids in 10.1%, and ptosis in 5.5% of cases. Jamal et al. reported SCH in 55% of their cases. Ioannides et al. [4] analyzed 127 patients with orbital fractures and noted that 13.3% of cases had eyelid laceration, and 7.08% of cases had ptosis, which was similar to our study.

In our study, we observed major injuries such as diplopia (6.5%), optic nerve injury (2.7%), permanent visual loss (2.7%), retinal hemorrhage (4.5%), hyphema (0.9%), and globe rupture (1.7%). In contrast, Kamath et al. [10] noted no cases of diplopia or optic nerve injury observed in their study. Jamal et al. [5] found retinal hemorrhage (4%), hyphema (2%), and globe rupture (1.8%) that is approximately similar to our findings.

We included all types of ophthalmic injuries in this study. Contrary to a study by Ioannides et al. [4] in which minor ophthalmic injuries were excluded on the belief that only those injuries leading to ophthalmic dysfunction or needing an intervention should be evaluated [1, 11].

Furthermore, Nagase et al. [12] excluded minor ophthalmic injuries from their study because ophthalmologic examination had been performed only for patients who complained from an ocular symptom or those who developed a problem during treatment or follow-up sessions.

Kamath et al. [10] found out that etiology and prevalence of maxillofacial fractures in different countries can be

influenced by some factors such as geographical location, culture, socioeconomic status, and the transportation system.

Our study showed that ophthalmic injuries as a consequence of the mid-facial fractures were 7 times more common in males than females with a preponderance of young adults. This finding, which was similar to that of other studies [1, 3, 7, 11, 13-18], implies that young males seem to have more outdoor activities, may have more aggressive behavior, and might be less likely to observe traffic rules, than females [10].

The present study showed that the most common cause of the injury leading to facial bone fractures was motor-vehicle accident (85.5%). According to the World Health Organization, road traffic accident kills one million people annually and causes damage to the 15-20 million people [10]. Researchers in countries such as India [8, 10], Singapore [11], and United Kingdom [13, 15], have found that road traffic accidents comprise the most common cause of mid-facial fractures in those countries which is comparable to our findings. Other etiologies in our study, included assault (6.6%), falling down (3.8%), occupational accident (1.9%), and sport accident (1.9%) in contrast, Barry et al. [3] from Ireland, reported assault was the most commonly documented mechanism of injury, accounting for 38% of victims, followed by sporting injuries (30%), falling down (17%), motor-vehicle accidents (11%), and farming accidents (4%) [3].

Due to the diversity in primary physical examinations and measured variables, and the type of study (retrospective or prospective) various results have been reported in relation to the prevalence of facial bone fractures [4].

Based on the results of our study, the prevalence of bilateral orbital fracture has been significantly more than other types of the fractures (37.4%). Amrith et al. [11] reported that orbital fracture was the most prevalent fracture in severe injuries. Al-Qurainy et al. [15], Read and Sires [18], and Magarakis et al. [2], also confirmed this statement by results of their studies. Nagase et al. [12] showed that the rate of major ophthalmic injuries in patients with 3 or 4 sites of fractures in the orbits was significantly more than patients who had no orbital fractures. Based on our findings, there was a significant difference between ocular injuries caused by unilateral (17.8%) and bilateral fractures (37.4%) of the orbit; that is contrary to the results of obtained by Roh et al. in 2014 [19], which described no significant difference between the rate of ophthalmic injuries caused by bilateral and unilateral orbital fractures.

## Conclusion

Our findings showed that 26% of all associated ophthalmic injuries were major and 73% were minor. Albeit the low prevalence of major ophthalmic injuries such as permanent visual loss, retinal hemorrhage, laceration of cornea, and globe rupture in this survey, they must be ruled out in all

mid-facial fractures by meticulous ophthalmologic examination. Because the mid-facial fractures are potentially detrimental to orbital contents, an ophthalmologic consultation is imperative and must be prioritized before embarking on performing maxillofacial surgical interventions. Considering the high pivotal role of motor-vehicle incidents in maxillo-facial and ophthalmic injuries, improved road, and vehicle safety should be insisted upon.

### Acknowledgement

We express our appreciation to the center and archive's unit staff Babol Shahid Beheshti hospital for cooperating in collecting data.

*Conflict of Interest: 'None declared'.*

### References

- [1] Karabekir HS, Gocmen-Mas N, Emel E, Karacayli U, Koymen R, Atar EK, et al. Ocular and periocular injuries associated with an isolated orbital fracture depending on a blunt cranial trauma: anatomical and surgical aspects. *J Craniomaxillofac Surg.* 2012; 40(7): e189-e193.
- [2] Magarakis M, Mundinger GS, Kelamis JA, Dorafshar AH, Bojovic B, Rodriguez ED. Ocular injury, visual impairment, and blindness associated with facial fractures: a systematic literature review. *Plast Reconstr Surg.* 2012; 129(1): 227-33.
- [3] Barry C, Coyle M, Idrees Z, Dwyer MH, Kearns G. Ocular findings in patients with orbitozygomatic complex fractures: a retrospective study. *J Oral Maxillofac Surg.* 2008; 66(5): 888-92.
- [4] Ioannides C, Treffers W, Rutten M, Noverraz P. Ocular injuries associated with fractures involving the orbit. *J Craniomaxillofac Surg.* 1988; 16(4): 157-9.
- [5] Jamal BT, Pfahler SM, Lane KA, Bilyk JR, Pribitkin EA, Diecidue RJ, et al. Ophthalmic injuries in patients with zygomaticomaxillary complex fractures requiring surgical repair. *J Oral Maxillofac Surg.* 2009; 67(5): 986-9.
- [6] Roth J, Hingst V, Lenz JH. Blindness following severe midfacial trauma--case report and review. *J Craniomaxillofac Surg.* 2012; 40(7): 608-13.
- [7] He D, Blomquist PH, Ellis E, III. Association between ocular injuries and internal orbital fractures. *J Oral Maxillofac Surg.* 2007; 65(4): 713-20.
- [8] Urolagin SB, Kotrashetti SM, Kale TP, Balihallimath LJ. Traumatic optic neuropathy after maxillofacial trauma: a review of 8 cases. *J Oral Maxillofac Surg.* 2012; 70(5): 1123-30.
- [9] Zachariades N, Papavassiliou D, Christopoulos P. Blindness after facial trauma. *Oral Surg Oral Med Oral Pathol Oral Radiol Endod.* 1996; 81(1): 34-7.
- [10] Kamath RA, Bharani S, Hammannavar R, Ingle SP, Shah AG. Maxillofacial trauma in central karnataka, India: an outcome of 95 cases in a regional trauma care centre. *Craniomaxillofac Trauma Reconstr.* 2012; 5(4): 197-204.
- [11] Amrith S, Saw SM, Lim TC, Lee TK. Ophthalmic involvement in cranio-facial trauma. *J Craniomaxillofac Surg.* 2000; 28(3): 140-7.
- [12] Nagase DY, Courtemanche DJ, Peters DA. Facial fractures - association with ocular injuries: A 13-year review of one practice in a tertiary care center. *Can J Plast Surg.* 2006; 14(3): 167-71.
- [13] Guly CM, Guly HR, Bouamra O, Gray RH, Lecky FE. Ocular injuries in patients with major trauma. *Emerg Med J.* 2006; 23(12): 915-7.
- [14] Gerber B, Kiwanuka P, Dhariwal D. Orbital fractures in children: a review of outcomes. *Br J Oral Maxillofac Surg.* 2013; 51(8): 789-93.
- [15] Al-Qurainy IA, Stassen LF, Dutton GN, Moos KF, el-Attar A. Diplopia following midfacial fractures. *Br J Oral Maxillofac Surg.* 1991; 29(5): 302-7.
- [16] Cobb A, Jeelani N, Ayliffe P. Orbital fractures in children. *Journal of Oral and Maxillofacial Surgery.* 2013; 51(1): 41-6.
- [17] Mao CJ, Yan H. [Clinical characteristics of mechanical ocular injury and application of ocular trauma score]. *Zhonghua Yan Ke Za Zhi.* 2012; 48(5): 432-5.
- [18] Read RW, Sires BS. Association between orbital fracture location and ocular injury: a retrospective study. *J Craniomaxillofac Trauma.* 1998; 4(3): 10-5.
- [19] Roh JH, Jung JW, Chi M. A clinical analysis of bilateral orbital fracture. *J Craniofac Surg.* 2014; 25(2): 388-92.

#### *Please cite this paper as:*

Foroughi R, Faghani F, Gharib S, Khafri S. Traumatic ophthalmic injuries ophthalmic injuries in mid-facial trauma: A decade long survey. *J Craniomax Res* 2015; 2(3-4): 128-132.