



Pleomorphic adenoma of buccal minor salivary gland: A case report

Melike Baygin Durak ^{1*}, Mustafa Mert Açıköz ², Banu Gürkan Köseoğlu ²

1. Istanbul University Institute of Health Sciences Oral, Dental and Maxillofacial Surgery PhD Program, İstanbul, Turkey.

2. Istanbul University Faculty of Dentistry, Oral, Dental and Maxillofacial Surgery, İstanbul, Turkey.

ARTICLE INFO

Article Type: Case Report

Received: 3 May. 2022

Revised: 1 Jul. 2022

Accepted: 10 Aug. 2022

*Corresponding author:

Melike Baygin Durak

Istanbul University Institute of Health Sciences
Oral, Dental and Maxillofacial Surgery PhD Program,
İstanbul, Turkey.

Tel: +90-532-3445318

Email: melikebaygin.mb@gmail.com

ABSTRACT

Pleomorphic adenoma is a benign salivary gland tumor that is frequently seen in the parotid gland. It is very rare in minor salivary glands. The case we present is a case of pleomorphic adenoma originating from the buccal minor salivary gland, which is very rare in this localization.

Keywords: Pleomorphic adenoma; Minor salivary gland; Buccal; Salivary gland tumors.

Introduction

Pleomorphic adenoma is a mixed tumor composed of epithelial and myoepithelial cells separated from the surrounding tissues by a fibrous capsule [1]. It is usually round or oval shaped. The size of the tumor varies between 1-7cm [2]. Two-thirds of salivary gland neoplasms are pleomorphic adenomas. It is most common in the parotid gland (85%), followed by the minor salivary glands (10%) and the submandibular gland (5%) [3]. The World Health Organization defined pleomorphic adenoma as “a tumor of mucoid tissue, myxoid tissue and chondroid masses that is intertwined, of epithelial origin,

pleomorphic or mixed”. The etiology of pleomorphic adenoma is unknown. It has been reported that tobacco use, genetic factors and exposure to chemicals may play a role in the etiology [4].

Case

A 52-year-old female patient applied to the Department of Oral and Maxillofacial Surgery of Istanbul University Faculty of Dentistry in May 2022 due to swelling in her mouth. In the anamnesis, it was reported that the

swelling has been present for about 10-12 years, grows slowly and painless. The patient stated that she applied to our clinic because the swelling reached large dimensions and made it difficult to eat. She had systemic hypertension. No bone involvement or erosion was found on the patient's panoramic radiograph. In the oral examination, it was observed that the oral hygiene was quite poor. There was a rubbery and mobile swelling extending to the upper lip in the vestibule sulcus at the level of teeth 14 and 17 on the right side of the maxilla (Picture 1). No fluctuation or pulsation was detected in the lesion. Its temperature was normal. Differential diagnoses of lipoma or fibroma were prioritized due to the location of the swelling, its painless nature and consistency. The lesion was excised under local anesthesia, adhering to surgical principles. The lesion was approximately 5.7x4.5x3.2 in size (Picture 2). When the lesion, whose color is yellow-pink, was divided into two from the center, mucus-like areas were observed in places. The completely excised lesion was sent to Istanbul University Oncology Institute, Department of Tumor Pathology and Oncology Cytology for histopathological examination (Picture 3). Diagnosis of pleomorphic adenoma was made as a result of histopathological examination.

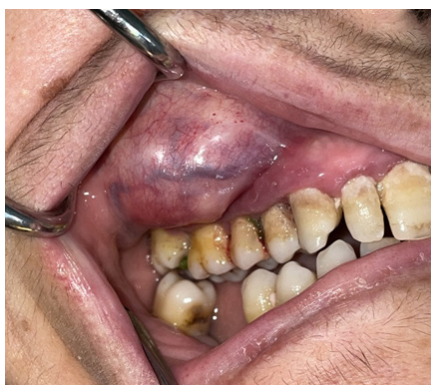

Figure 1. Preoperative intraoral view of the lesion.

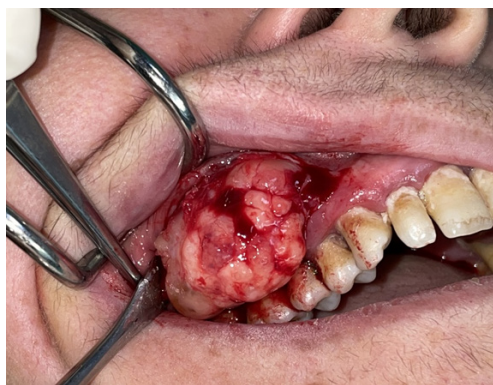

Figure 2. Operation view of the lesion.

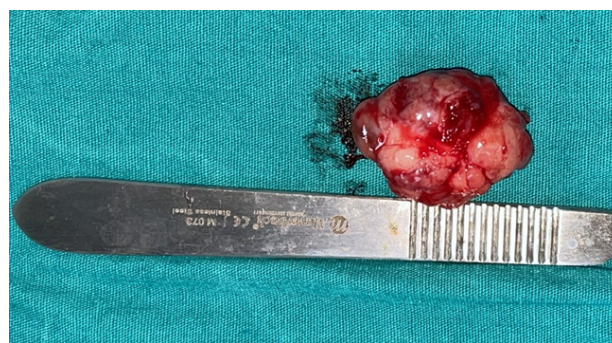


Figure 3. Excision of the lesion.

Discussion

In the oral cavity, there are approximately 800-1000 minor salivary glands in the buccal, labial, lingual mucosa, soft palate, hard palate and floor of the mouth. These minor salivary glands do not contain capsules, unlike the major salivary glands [5]. 45-50% of tumors seen in minor salivary glands are pleomorphic adenomas [6]. Pleomorphic adenoma is most common in the superficial lobe of the parotid gland. In the case we presented, the vestibular mucosa with pleomorphic adenoma is very rare in terms of localization. Although pleomorphic adenoma is frequently seen in the parotid gland, it has been reported in the literature that it can be found in quite different localizations. Sankari et al. [7] in the buccal mucosa, Dongol et al. [8] in the external ear canal, Chhabra et al. [9] in tongue, Kim et al. [10] in the subcutaneous tissue in the nasolabial fold, Bhatia et al. [11] in the upper lip, Mouzali et al. [12] in the nasal wing, Baron et al. [13] reported cases of pleomorphic adenoma in the nasal septum. It has been reported that these atypical localizations originate from ectopic salivary glands and are very rare.

Nouri et al. [14] In the case series presentation of 7 cases showing atypical pleomorphic adenoma localizations, it was reported that pleomorphic adenoma was seen on the hard palate, soft palate, nasal septum, upper lip and lower eyelid. In this presentation, it was reported that atypical localization of pleomorphic adenoma is quite rare, but should be considered as a differential diagnosis. Li et al. [15]. In a case report of 52 cases with an unusual localization in the mouth, they defined the intraoral regions other than the sublingual gland and hard palate as atypical for pleomorphic adenoma. Among these atypical locations, pleomorphic adenoma was most frequently observed on the upper lip, followed by the buccal mucosa, tongue, lower lip and retromolar ridge.

Pleomorphic adenoma occurs mostly in young and middle-aged adults aged 30-60 years. It is more common in women than men and is rare in children [1,6]. In our case, the age and gender of the patient are compatible with the literature. The consistency of the pleomorphic adenoma, which may be encapsulated or unencapsulated, is generally elastic, grows slowly, painlessly, well circumscribed. Although it can reach very large sizes, it is usually asymptomatic and does not involve the facial nerve when observed in the parotid. Patients usually present with small, painless nodules that gradually increase in size [3]. Our patient's findings are consistent with the literature. Inadequate excision, rupture of the capsule or shedding of tumor cells during excision may cause recurrence. Therefore, incisional biopsy for pleomorphic adenoma is contraindicated. Removal of the tumor without its capsule and incisional biopsy for diagnostic purposes increase morbidity. The success of the treatment depends on the removal of the tumor along with its capsule.

The diagnosis of pleomorphic adenoma is made by a joint study of anamnesis, clinical examination, cytology and pathology. In the differential diagnosis of the lesion, cyst, hemangioma, neurofibroma, foreign body reaction, fibroma, abscess, lipoma, carcinoma and adenocarcinoma can be counted. For the diagnosis of abscess, there must be a devital tooth associated with the lesion in the surrounding of the lesion. Odontogenic or nonodontogenic cysts are differentiated if their consistency is not elastic like a pleomorphic adenoma. Clinically negative shear test and histological absence of lipomatous components rule out the diagnosis of lipoma [12]. We prioritized the differential diagnosis of fibroma and lipoma due to the patient's history, localization of the lesion, its consistency, painless and slow growth.

Malignant transformation was observed in approximately 3% of cases of pleomorphic adenoma in minor salivary glands. The malignant transformation of pleomorphic adenoma is pleomorphic adenocarcinoma. It is also called ex-pleomorphic adenoma. Pleomorphic adenoma is clinically very similar to adenoid cystic carcinoma, but there is no pain and ulceration in pleomorphic adenoma. Histomorphological examination is essential to decide on the treatment option and to determine whether the lesion is benign or malignant. The treatment of pleomorphic adenomas is excision. The probability of recurrence is low. The cause of relapse is usually related to inadequate surgical procedure. The presence of capsules reduces the risk of residual. Long-term follow-up is required [13].

Conclusion

Pleomorphic adenoma is a benign tumor that is frequently seen in the major salivary glands and differs from other tumors due to its histological features. Although it is most common in the parotid, it can also be seen in various minor salivary glands. In the case we presented, the localization of the lesion is very rare. Therefore, pleomorphic adenoma should be considered in the differential diagnosis of painless, elastic swellings. The treatment is excision. Long-term follow-up is recommended due to the risk of recurrence.

Conflict of Interest

There is no conflict of interest to declare.

References

- [1] Jorge J, Pires FR, Alves FA, Perez DE, Kowalski LP, Lopes MA, Almeila OP. Juvenile intraoral pleomorphic adenoma: report of five cases and review of the literature. *Int J Oral Maxillofac Surg.* 2002 Jun; 31(3):273-5. doi: 10.1054/ijom.2002.0206. PMID: 12190133.
- [2] Periasamy S, Manoharan A, Garg H, Kumar SP. Pleomorphic Adenoma of the Cheek: A Case Report. *Cureus.* 2019 Aug 3; 11(8):e5312. doi: 10.7759/cureus.5312. PMID: 31592367; PMCID: PMC6773457.
- [3] Almeslet AS. Pleomorphic Adenoma: A Systematic Review. *Int J Clin Pediatr Dent.* 2020 May-Jun; 13(3):284-287. doi: 10.5005/jp-journals-10005-1776. PMID: 32904077; PMCID: PMC7450192.
- [4] Martinelli M, Martini F, Rinaldi E, et al. Simian virus 40 sequences and expression of the viral large T antigen oncoprotein in human pleomorphic adenomas of parotid glands. *Am J Pathol.* 2002; 161(4):1127-1133. doi: 10.1016/S0002-9440(10)64389-1.
- [5] Khandekar S, Dive A, Munde P, Wankhede ND. Pleomorphic adenoma of the buccal salivary gland. *J Oral Maxillofac Pathol.* 2015 Jan-Apr; 19(1):111. doi: 10.4103/0973-029X.157222. PMID: 26097328; PMCID: PMC4451658.
- [6] Pramod Krishna B. Pleomorphic Adenoma of Minor Salivary Gland in a 14 year Old Child. *J Maxillofac Oral Surg.* 2013 Jun; 12(2):228-31. doi: 10.1007/s12663-010-0125-5. Epub 2010 Nov 30. PMID: 24431845; PMCID: PMC3681990.

- [7] Sankari SL, Dhanavelu P, Priya PS, Jimson S. Keratinizing pleomorphic adenoma: A rare variant in an unusual location. *J Oral Maxillofac Pathol*. 2021 Sep-Dec; 25(3):557. doi: 10.4103/jomfp.jomfp_362_21. Epub 2022 Jan 11. PMID: 35281182; PMCID: PMC8859603.
- [8] Dongol K, Karki UR. Pleomorphic adenoma in the external auditory canal: Arising at an atypical location. *SAGE Open Med Case Rep*. 2021 Dec 8; 9:2050313X211063790. doi: 10.1177/2050313X211063790. PMID: 34900261; PMCID: PMC8664305.
- [9] Chhabra S, Bhutani N, Jain P, Gill M, Nishisth N, Sen R. 'Pleomorphic adenoma of the tongue: A common entity at the uncommon location'. *Ann Med Surg (Lond)*. 2018 Dec 23; 38:34-36. doi: 10.1016/j.amsu.2018.12.004. PMID: 30619605; PMCID: PMC6312764.
- [10] Kim YH, Yoon HW, Kim J, Kim SW. Ectopic pleomorphic adenoma on subcutaneous plane of the cheek. *Arch Craniofac Surg*. 2019 Feb; 20(1):55-57. doi: 10.7181/acfs.2018.01949. Epub 2019 Feb 1. PMID: 30703863; PMCID: PMC6411524.
- [11] Bhatia JSS. Pleomorphic Adenoma of Upper Lip: A Rare Case Presentation. *Indian J Otolaryngol Head Neck Surg*. 2019 Oct; 71(Suppl 1):755-758. doi: 10.1007/s12070-018-1537-7. Epub 2018 Nov 15. PMID: 31742058; PMCID: PMC6848401.
- [12] Mouzali A, Lameche S, Slimani A, Zemirli O. Pleomorphic Adenoma of the Ala Nasi: A Case Report. *Clin Med Insights Ear Nose Throat*. 2019 Dec 11;12:1179550619886561. doi: 10.1177/1179550619886561. PMID: 31853210; PMCID: PMC6906341.
- [13] Baron S, Koka V, El Chater P, Cucherousset J, Paoli C. Pleomorphic adenoma of the nasal septum. *Eur Ann Otorhinolaryngol Head Neck Dis*. 2014 Apr; 131(2):139-41. doi: 10.1016/j.anorl.2013.03.007. Epub 2013 Oct 15. PMID: 24139072.
- [14] Nouri H, Ziad T, Rochdi Y, Aderdour L, Raji A. Adénome pléomorphe à localisation inhabituelle: à propos d'une série de sept cas [Unusual location of pleomorphic adenoma: A series of 7 cases]. *Rev Laryngol Otol Rhinol (Bord)*. 2014; 135(4-5):201-5. French. PMID: 26521369.
- [15] Li Y, Xiao N, Dai Y, Guo S, Zhang Y, Wang D, Cheng J. Comprehensive characterization of pleomorphic adenoma at intraoral unusual sites. *Oral Surg Oral Med Oral Pathol Oral Radiol*. 2022 Jan; 133(1):21-27. doi: 10.1016/j.oooo.2021.05.006. Epub 2021 May 24. PMID: 34511341.

Please cite this paper as:

Baygin Durak M, Mert Açıkgoz M, Gürkan Köseoğlu B. Pleomorphic adenoma of buccal minor salivary gland: A case report. *J Craniomaxillofac Res* 2022; 9(3): 158-161