



## Evaluation of correspondence between clinical and pathological margins in oral squamous cell carcinoma

Abbas Karimi<sup>1</sup>, Ata Garajei<sup>2\*</sup>, Hesam Nazari<sup>3</sup>, Azadeh Emami<sup>4</sup>

1. Department of Oral and Maxillofacial Surgery, School of Dentistry, Tehran University of Medical Sciences, Tehran, Iran.

2. Department of Oral and Maxillofacial Surgery, School of Dentistry, Tehran University of Medical Sciences, Tehran, Iran AND Department of Head and Neck Surgical Oncology and Reconstructive Surgery, The Cancer Institute, School of Medicine, Tehran University of Medical Sciences, Tehran, Iran.

3. Department of Oral and Maxillofacial Surgery, School of Dentistry, Kermanshah University of Medical Sciences, Kermanshah, Iran.

4. Department of Anesthesiology, Iran University of Medical Sciences, Tehran, Iran.

### ARTICLE INFO

#### Article Type: Original Article

Received: 11 Apr. 2022

Revised: 2 May. 2022

Accepted: 10 Sep. 2022

#### \*Corresponding author:

Ata Garajei

Department of Oral and Maxillofacial Surgery, School of Dentistry, Tehran, Iran AND Department of Head and Neck Surgical Oncology and Reconstructive Surgery, The Cancer Institute, School of Medicine, Tehran University of Medical Sciences, Tehran, Iran.

Tel: +98-21-66581544

Fax: +98-21-66428655

Email: atagarajei@Tums.ac.ir

### ABSTRACT

**Background:** Microscopically, oral Squamous Cell Carcinoma (SCC) spreads more than the gross tumor. Thus it is recommended to resect the tumor with a proper safe margin. The aim of this study was to evaluate the correspondence between clinical and histopathological margins in oral SCC.

**Materials and Methods:** Samples were collected from patients diagnosed with oral SCC and referred to Iran Cancer Institute in 2015. All margins of tumors were determined by a marker and then the tumors were resected with 1cm safe margin. The superior, inferior, left and right borders were marked and examined microscopically. The lowest distance between tumor cells and border of resected tissue was considered as pathological margin. The cases with pathological margin less or more than 5 millimeters were classified as close and free margin groups, respectively.

**Results:** Forty-four specimens (20 females and 24 males), definitely diagnosed as SCC, were examined. The mean age was 61 years old. 19 cases (43.2%) were in the mandible; 23 cases (52.3%) in the tongue and 2 cases (4.5%) in the maxilla. 16 cases (38.4%) were free margin and 28 cases (63.6%) were close margin and the mean pathological margin was 3.52mm.

**Conclusion:** For some cases, especially SCCs of the mandible, 1-centimeter margin is not adequate to achieve free margins, thus evaluating tumor location, size and stage for more resection seems worthwhile and advisable and can decrease the risk of relapse after resection.

**Keywords:** Squamous cell carcinoma; Clinical margin; Histopathological margin.

### Introduction

Squamous Cell Carcinoma (SCC) is the most common of oral cavity that accounts for almost 91% of total malignancies of the mouth. Etiology of SCC is said to be multifactorial and external factors such as tobacco, syphilis and sun light as well as internal factors such as iron deficiency can play a role in its development. The

oral cancer is more prevalent in developing countries and Smokers and alcoholics are 6-15 times more at risk [1]. Despite the developments in cancer therapy, the five-year survival rate of patients with SCC is almost 40%. The main reason of failure is local relapse, which directly correlates with histopathological margins after tumor resection [2,3].

During resection, the clinically-normal surrounding tissue is always removed partially and histopathologically, this margin is classified into clear (more than 5mm), close (1 to 5mm) and involved (less than 1mm) margins based on UK Royal College of Pathologists' classification [4,5]. A margin is classified as positive when the tumor cells are seen at the vicinity of the margin. Histopathologically, 5mm of margin is accepted as adequate and since tumor cells spread more than gross tumor, it is recommended to resect with 1 centimeter margin in order to obtain 5mm of normal tissue [6]. Tissue shrinkage after resection, laboratory procedures and pathological processing on the specimens may result in reduced margins and more false-positive involved margins [7,8]. The amount of this shrinkage has been assessed in lung [9] and colorectal [10] cancers, but overlooked in studies of oral SCCs. This study was designed to assess the correspondence between clinical and histopathological margins of oral SCCs and evaluate whether 1cm safe margin is adequate.

## Materials and Methods

The samples were collected from patients diagnosed with oral SCC and referred to Iran Cancer Institute from March 2015 to March 2016. All patients underwent biopsy examination and the ones diagnosed as SCC were selected. The inclusion criteria was a definite histopathology report of the biopsy, possibility of obtaining 1cm safe margin and adequacy of resected tissue for Histopathology examinations. The samples were excluded when Histopathology margin could not be determined. The study was done according to the principles of the Declaration of Helsinki, and approved by the institutional review board of Imam Khomeini Hospital (approval number: 2013041601) with written informed consents obtained from all patients. The lesions were assessed using CT scan. All margins of tumors with 1cm clinically normal surrounding tis-

sue were marked and then tumors were resected with 1cm safe margin. All resections were done by one surgeon. The superior, inferior, left and right borders were marked and examined microscopically. The lowest distance between tumor cells and border of resected tissue was considered as histopathological margin. Samples with histopathological margins less or more than 5mm were classified as close and free margin group, respectively. According to tumor location cases were divided into three groups: buccal and mandibular mucosa, mouth floor and retromolar trigone as the first group; oral part of the tongue as the second group; and maxilla and palate as the third group. The proportion of histopathological margin to clinical margin was calculated for each sample. The higher the percentage, the more correspondence and better prognosis. Data was analyzed using Statistical Package for the Social Sciences 22 with Chi-Squared and T-test. P-value less than 0.05% was considered statistically significant.

## Results

Forty-four resected tumor specimens (20 females and 24 males), definitely diagnosed as SCC, were examined. The mean age of the patients was  $61 \pm 10.12$  years (Figures 1 and 2). Regarding anatomic location of the tumor, 19 cases (43.2%) were in the mandible; 23 cases (52.3%) in the tongue and 2 cases (4.5%) were in the maxilla (Figure 3). The mean pathological margin was  $3.52 \pm 2.97$  mm (0-8mm) and 16 cases (38.4%) were free margin and 28 cases (63.6%) were close margin (Table 1). The correspondence percentage was not statistically different between males and females ( $P=0.647$ ). On the other hand, it was different in the anatomical groups, as the correspondence percentages of tumors of the mandible were less than that of tumors of the tongue or maxilla ( $P=0.008$ ) (Figure 4 and 5 and Table 2).

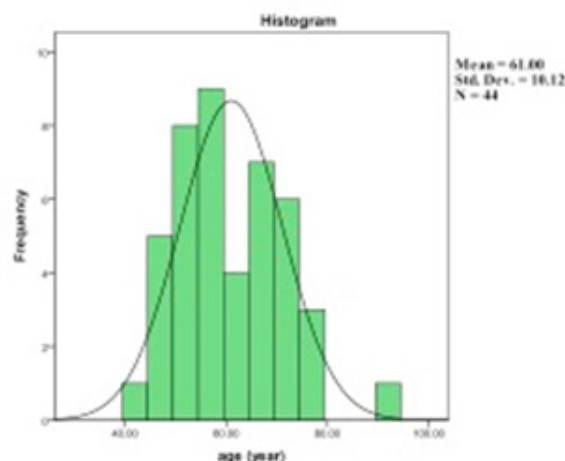


Figure 1. Age distribution of patients.

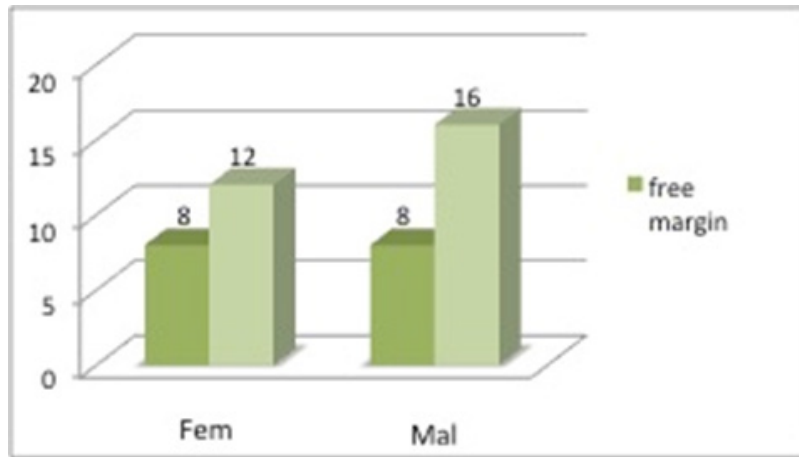


Figure 2. Sex distribution of patients in terms of histopathological margin.

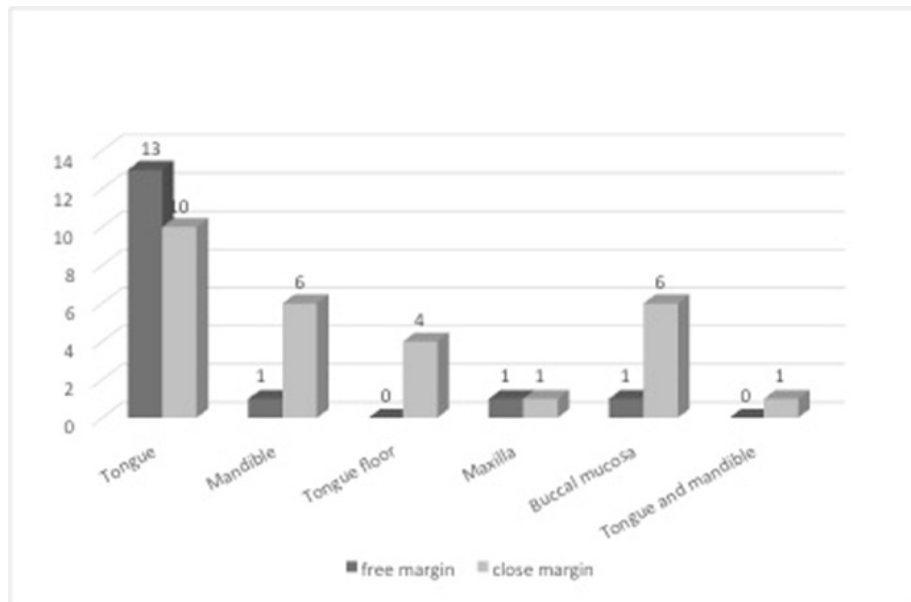


Figure 3. Frequency of anatomic location of tumor in terms of histopathological margin.

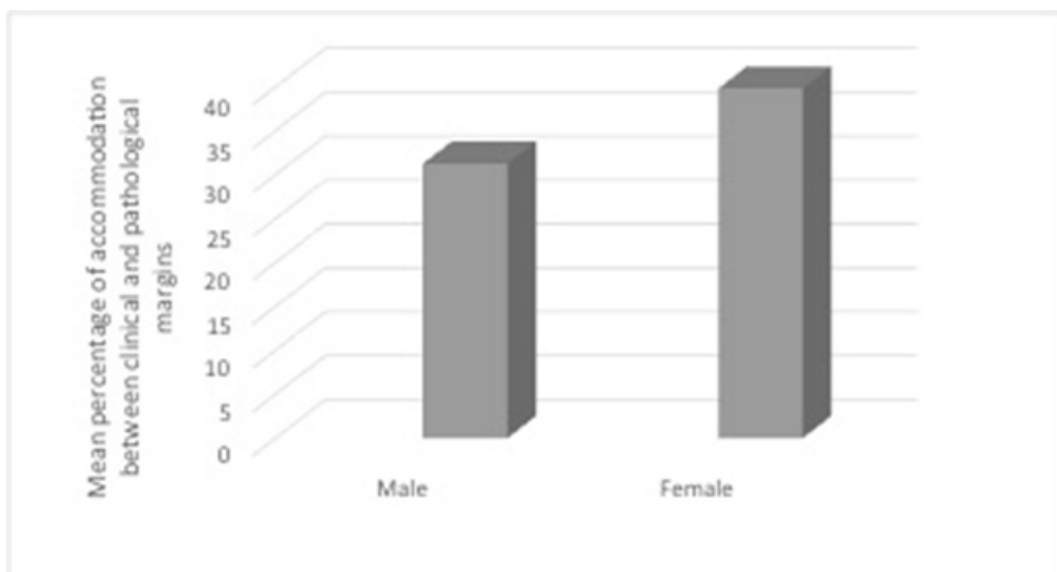


Figure 4. Mean percentage of correspondence between clinical and histopathological margins in terms of patients' sex.

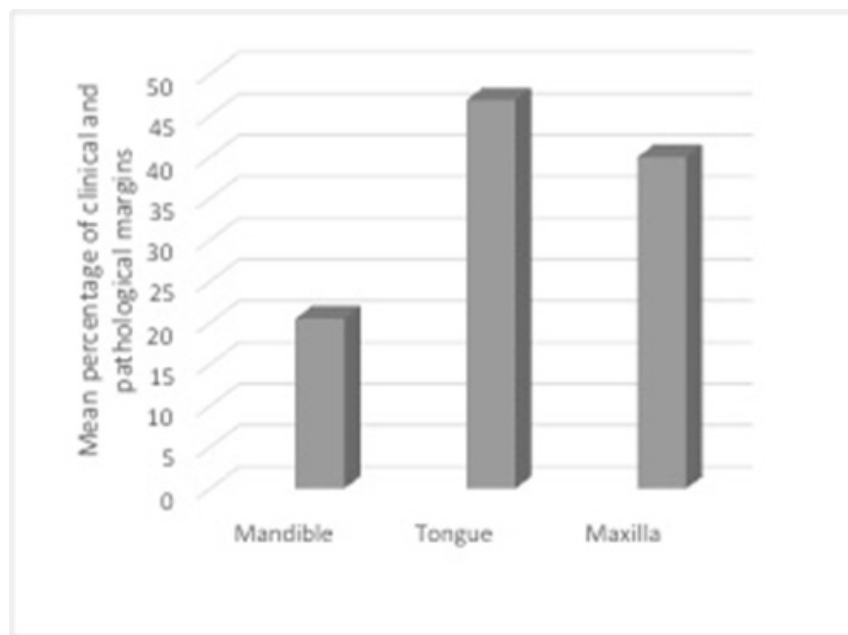


Figure 5. Mean percentage of correspondence between clinical and pathological margins in terms of anatomic location of the tumor.

Table 1. Comparison of sex and anatomic location in terms of tumor margin.

Variables		Free margin (N=16)	Close margin (N=38)	Statistical test
Age (Mean±SD)		61.87±11.21	60.50±9.62	P=0.670
Sex	Male (%)	8 (50%)	12 (42.9%)	P=0.647
	Female (%)	8 (50%)	16 (57.1%)	
Anatomic location	Mandible	2 (12.5%)	17 (60.7%)	P=0.008
	Tongue	13 (81.3%)	10 (35.7%)	
	Maxilla	1 (6.3%)	1 (3.6%)	

Table 2. Comparison of correspondence percentage between clinical and histopathological margins in terms of sex and anatomic location.

Variables		Mean±SD of correspondence percentage	Statistical test
Sex	Male	31.29±30.42	P=0.348
	Femal	39.85±28.98	
Anatomic location	Mandible	20.53±23.34	P=0.014
	Tongue	46.87±29.51	
	Maxilla	40.00±42.42	

## Discussion

Determination of appropriate clinical margins is important to reduce the risk of relapse after primary resection. The risk of marginal involvement is dependent upon tumor location and stage [5]. Also, mucosa elasticity is said to be important, in which performing transoral tumor resection of buccal mucosa in the maximum opening of the mouth needs more safe margin to achieve margin-negative resection, than extraoral approach which is done when mouth is closed. There is no standard procedure to achieve margin negative resection [11], but usually smaller tumors have higher percentage of free margins [12], greater survival rate and lesser relapse [7].

In this study tumors of the tongue were almost free-margin while tumors of the mandible (mouth floor, buccal mucosa and mandible) were mostly close-margin ( $P=0.008$ ). It seems that concerning tumor location maybe helpful in achieving margin-negative resection [12] [7] [13]. Also, correspondence between clinical and pathological margins might help assess prognosis. The higher correspondence proportion may indicate better prognosis. The least and the most correspondence proportions in this study were noted in the mandible and tongue, respectively. Chang et al also reported that correspondence proportion in tumors of tongue was higher than that of other regions ( $P=0.013$ ) [14].

Some suggest that tumors should be resected with 1cm margin [7] [5], not only this concept is dated [15] and is not appropriate for all cases [16] [14] [17], but also due to possible limitations, resecting with appropriate margin is impossible in some areas [11]. In such situations, chemotherapy or adjuvant radiotherapy is recommended to prevent relapse [7]. Furthermore, there has been some debates on determining the margin for each individual based on several factors including stage and anatomical location [13] [12] [7]. Since tumor stage is correlated with relapse rate and margin condition, it was better if this study analyzed all cases regarding their size and stage. This study also lacks long-term follow-ups and some relapses may have been missed. Finally, it seems that defining adequate margin for resection of oral SCCs require precise evaluation of tumor size and stage in order to minimize the risk of relapse.

## Conclusions

Regarding the findings of this study, we concluded that in some cases, especially SCCs of the mandible,

1cm margin for resection was not adequate to achieve free margins, thus evaluating tumor location, size and stage for more resection seems worthwhile and advisable and can decrease the risk of relapse after resection.

## Conflict of Interest

There is no conflict of interest to declare.

## References

- [1] Neville BW, Damm DD, Chi AC, Allen CM. Oral and maxillofacial pathology: Elsevier Health Sciences; 2015.
- [2] The effect of topical application of pure honey on radiation-induced mucositis: a randomised clinical trial. *BDJ*. 2008; 205(5):257-.
- [3] Telfer MR, Shepherd JP. Psychological distress in patients attending an oncology clinic after definitive treatment for maxillofacial malignant neoplasia. *International Journal of Oral and Maxillofacial Surgery*. 1993; 22(6):347-9.
- [4] Helliwell T, Woolgar J. Dataset for histopathology reporting of mucosal malignancies of the oral cavity. London: The Royal College of Pathologists. 2013.
- [5] Woolgar JA, Triantafyllou A. A histopathological appraisal of surgical margins in oral and oropharyngeal cancer resection specimens. *Oral Oncology*. 2005; 41(10):1034-43.
- [6] Alicandri-Ciufelli M, Bonali M, Piccinini A, Marra L, Ghidini A, Cunsolo EM, et al. Surgical margins in head and neck squamous cell carcinoma: what is 'close'? *European Archives of Oto-Rhino-Laryngology*. 2013; 270(10):2603-9.
- [7] Chen T-C, Wang C-P, Ko J-Y, Yang T-L, Lou P-J. The impact of pathologic close margin on the survival of patients with early stage oral squamous cell carcinoma. *Oral oncology*. 2012; 48(7):623-8.
- [8] Weijers M, Snow GB, Bezemer DP, van der Wal JE, van der Waal I. The status of the deep surgical margins in tongue and floor of mouth squamous cell carcinoma and risk of local recurrence; an analysis of 68 patients. *International Journal of Oral and Maxillofacial Surgery*. 2004; 33(2):146-9.
- [9] Hsu P-K, Huang H-C, Hsieh C-C, Hsu H-S, Wu Y-C, Huang M-H, et al. Effect of formalin fixation on tumor size determination in stage I non-small

cell lung cancer. *The Annals of thoracic surgery*. 2007; 84(6):1825-9.

- [10] Goldstein NS, Soman A, Sacksner J. Disparate surgical margin lengths of colorectal resection specimens between in vivo and in vitro measurements: the effects of surgical resection and formalin fixation on organ shrinkage. *American journal of clinical pathology*. 1999; 111(3):349-51.
- [11] Anderson CR, Sisson K, Moncrieff M. A meta-analysis of margin size and local recurrence in oral squamous cell carcinoma. *Oral oncology*. 2015; 51(5):464-9.
- [12] Girardi FM, Zanella VG, Kroef RG. Correlation between clinical and pathological data and surgical margins in patients with squamous cell carcinoma of the oral cavity. *Brazilian journal of otorhinolaryngology*. 2013; 79(2):190-5.
- [13] Brandwein-Gensler M, Teixeira MS, Lewis CM, Lee B, Rolnitzky L, Hille JJ, et al. Oral squamous cell carcinoma: histologic risk assessment, but not margin status, is strongly predictive of local disease-free and overall survival. *The American journal of surgical pathology*. 2005; 29(2):167-78.
- [14] Cheng A, Cox D, Schmidt BL. Oral Squamous Cell Carcinoma Margin Discrepancy After Resection and Pathologic Processing. *Journal of Oral and Maxillofacial Surgery*. 2008; 66(3):523-9.
- [15] Yuen PW, Lam KY, Chan ACL, Wei WI, Lam LK. Clinicopathological analysis of local spread of carcinoma of the tongue. *The American journal of surgery*. 1998; 175(3):242-4.
- [16] Tirelli G, Zacchigna S, Biasotto M, Piovesana M. Open questions and novel concepts in oral cancer surgery. *European Archives of Oto-Rhino-Laryngology*. 2015:1-11.
- [17] Upile T, Fisher C, Jerjes W, El Maaytah M, Searle A, Archer D, et al. The uncertainty of the surgical margin in the treatment of head and neck cancer. *Oral oncology*. 2007; 43(4):321-6.

*Please cite this paper as:*

Karimi A, Garajei A, Nazari H, Emami A. Evaluation of correspondence between clinical and pathological margins in oral squamous cell carcinoma. *J Cranio-maxillofac Res* 2022; 9(4): 170-175