



## A new osteotomy for mandibular sagittal split osteotomy

Amirmohammad Arabi Daredor, Alireza Parhiz \*, Amirali Asadi

Craniofacial Research Center, Tehran University of Medical Sciences, Tehran, Iran; Department of Oral and Maxillofacial Surgery, School of Dentistry, Tehran University of Medical Sciences, Tehran, Iran.

### ARTICLE INFO

Article Type:  
Technical Note

Received: 1 Feb. 2023

Revised: 20 Mar. 2023

Accepted: 29 Mar. 2023

\*Corresponding author:

Alireza Parhiz

Craniofacial Research Center, Tehran University of Medical Sciences, Tehran, Iran; Department of Oral and Maxillofacial Surgery, School of Dentistry, Tehran University of Medical Sciences, Tehran, Iran.

Tel: +98-21-84902473

Fax: +98-21-84902473

Email: alirezaparhiz@gmail.com

### ABSTRACT

Sagittal split ramus osteotomy is one of the most efficient osteotomy techniques for orthognathic surgery. This technical note presents a new technique of mandibular osteotomy to prevent bony interferences with simultaneous maxillary impactions. As well as increase in bone contact for great mandibular advancements which results in better bone healing. furthermore, Fixation of bony segments in this area is far from third molar alveolar socket if extraction is done and is not involved in the process.

**Keywords:** Orthognathic surgery; Mandible; Osteotomy; Maxilla; Impaction.

## Introduction

Sagittal split ramus osteotomy is one of the most efficient osteotomy techniques for orthognathic surgery [1]. At the beginning we review the history for Mandibular different osteotomy techniques. Early types of osteotomies were extra-oral with the horizontal cut above the lingula. This presented a few problems such as small surface of contact between the bone fragments. Complications related to extra-oral osteotomy were facial nerve problems, pseudoarthrosis and open bite. Soon the technique was modified by Schuchardt and Obwegeser [2] cut the medial cortical surface of the ramus above the lingula, and the external surface 10mm below the first cut. After that Obwegeser and Trauner [3,4] increased this distance

to 25mm, which allowed for a larger contact area. They also introduced intra-oral access for mandibular sagittal split osteotomy. Dal Pont [5] revised Obwegeser's technique to be used for other anomalies besides prognathism, such as open bite and retrognathism. This modification resulted in smaller displacement of the proximal segment because of jaw elevator muscle activities. Dal Pont described Retro-molar osteotomy at the distal level of second molar, which started from external oblique line to the inferior border of the mandible. Hunsuck [6] extended the medial osteotomy to the posterior region of the lingula, with no need for involvement of the posterior border of the ramus. But He suggested lateral osteotomy, at the junction of the ramus

and body of the mandible. Epker [7] suggested not extending the dissection of medial tissue to the posterior border of the ramus and only for visualization of inferior alveolar neurovascular bundle and elevation up, without posterior extension. His osteotomy is similar to Hunsuck, But the inferior cut, completely involves the basilar region, that makes sagittal split easier. Especially when the treatment plan consists of maxillary impaction, the surgeon may have problem with bony interferences, here we describe our innovation for mandible sagittal osteotomy to solve this potential problem.

### Surgical Technique

The technique presented below is performed under general anesthesia and nasotracheal intubation. An incision is made on the mandibular ramus mucosa, extending bilaterally below the mucogingival border to the mental foramen. Subperiosteal elevation is accomplished with preservation of the mental nerve branches. A Kocher forceps is positioned above the lingula, and a periosteal elevator is used for medial access to the mandibular ramus. A channel retractor is employed for elevation of the buccal tissues of the mandibular body and ramus. Langenbeck retractors can be used for accessing the anterior soft tissue of the mandible. Our technique presently suggested, in contrast to previous methods, includes osteotomy of the ramus and body, to be performed above the lingula and extending slightly behind it with reciprocating saw. Lateral cut of osteotomy is also done with reciprocating saw in the region of the mandibular body at the level of the mesial of the second molar. Figure 1 a,b.

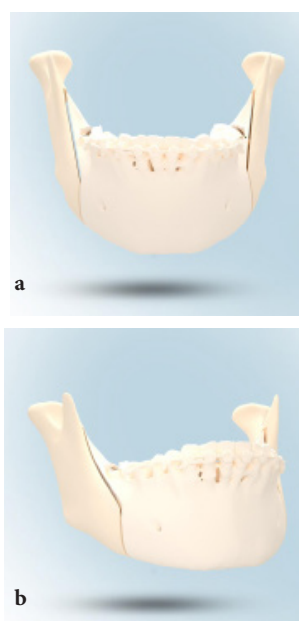


Figure 1. Schematic osteotomy design.

Osteotomes used for splitting, are sequentially malleted, beginning in the retromolar region with Kocher forceps oriented to the sigmoid notch, then osteotomy cut is done. Especial care procedures to avoid injury to the inferior alveolar bundle, are of fundamental importance. Lateral thickness of the proximal fragment is maintained, also direction of osteotome parallel to the buccal cortical, are emphasized. After osteotomy sagittal gap is opened, which allows the visual inspection of all nerve extension and loosening of the inferior alveolar bundle, when it is exposed. After completion of the fracture, a 2,0mm straight miniplate and monocortical screws are used for rigid internal fixation. Size of the plate and screws will depend on the size of the planned movement.

### Conclusion

This technical note presents many possible advantages. In maxillary impactions, we may have bony interferences, this osteotomy will help to reduce this problem. Also the area of bone contact is considerably increased, particularly in cases of great mandibular advancements, which results in better bone healing. Remodeling of the bone is assured without interference with the area of fixation. When extending osteotomy to mesial of second molar, intraoral access is easier therefore the need of transcutaneous access for insertion of screws is removed. The flat bone surface facilitates adaptation of the plate. Application of plate instead of positional screws in this area may also make it easier for removal. Fixation of bony segments in this area is far from third molar alveolar socket if extraction is done and is not involved in the process.

### Conflict of Interest

There is no conflict of interest to declare.

### References

- [1] Wolford LM: The sagittal split ramus osteotomy as the preferred treatment for mandibular prognathism. *J Oral Maxillofac Surg.* 2000, 58: 310-312. 10.1016/S0278-2391(00)90062-4
- [2] Obwegeser H: The sagittal splitting of the mandible procedure. *Mandibular growth anomalies—terminology—aetiology—diagnosis—treatment.* Edited by: Obwegeser H. 2001, Berlin: Springer-Verlag, 12: 359-384.
- [3] Trauner R, Obwegeser H: The surgical correction of mandibular prognathism and retrognathia with

consideration of genioplasty. Oral Surg Oral Med Oral Pathol. 1957, 10: 677-689. 10.1016/S0030-4220(57)80063-2.

- [4] Obwegeser H: The indications for surgical correction of mandibular deformity by the sagittal splitting technique. Br J Oral Surg. 1964, 2: 157-171.
- [5] Dal Pont G: Retromolar osteotomy for the correction of prognathism. J Oral Surg Anesth Hosp Dent Serv. 1961, 19: 42-47.
- [6] Hunsuck EE: A modified intraoral sagittal splitting technique for correction of mandibular prognathism. J Oral Surg. 1968, 26: 250-253.
- [7] Epker BN: Modifications in the sagittal osteotomy of the mandible. J Oral Surg. 1977, 35: 157-159.

*Please cite this paper as:*

Arabi Daredor A, Parhiz A, Asadi A. A new osteotomy for mandibular sagittal split osteotomy. J Cranio-maxillofac Res 2023; 10(2): 79-81