



## Soft Tissue Sarcoma of the Scalp Infiltrating the Occipital Bone: A Case Report

Ayoub Bakhil \*<sup>id</sup>, Adam Benbachir, Amina Kahoul, Hicham Sabani, Lahcen Khalfi, Jalal Hamama, Karim El Khatib

Department of Maxillofacial Surgery Hmimv Rabat Morocco, Mohammed V University Rabat Morocco, Morocco.

### ARTICLE INFO

#### Article Type: Case Report

Received: 12 March 2024

Revised: 18 April 2024

Accepted: 19 June 2024

\*Corresponding author:

Ayoub Bakhil

Department of Maxillofacial Surgery Hmimv Rabat Morocco, Mohammed V University Rabat Morocco, Morocco.

Email: ayoub.bakhil95@gmail.com

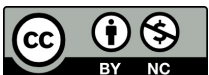### ABSTRACT

Soft tissue sarcomas are rare, histologically heterogeneous malignant tumors. Head and neck localization accounts for 10% of cases, with a poor prognosis in the presence of infiltration of the skull bones or endocranial extension. Management remains essentially surgical plus or minus radiotherapy. We report the case of a young patient admitted for management of a large-volume atypical scalp sarcoma with infiltration of the occipital bone, necessitating surgical resection with cranioplasty.

**Keywords:** Sarcoma; Scalp; Cranioplasty.

#### Please cite this Article as:

Bakhil A, Benbachir A, Kahoul A, Sabani H, Khalfi L, Hamama J, et al. Soft Tissue Sarcoma of the Scalp Infiltrating the Occipital Bone: A Case Report. J Craniofac Res 2024; 11(3): 186-189. DOI:



Copyright © 2024 Tehran University of Medical Sciences.

This work is licensed under a Creative Commons Attribution-NonCommercial 4.0 International license (<https://creativecommons.org/licenses/by-nc/4.0/>). Non-commercial uses of the work are permitted, provided the original work is properly cited.

## Introduction

Soft-tissue sarcomas are rare and histologically highly heterogeneous malignant tumors. Types of sarcoma are defined by the nature of the proliferating tissue, and tumor cell differentiation, irrespective of the tissue in which the sarcoma develops. Head and neck sarcomas account for less than 5% of soft tissue sarcomas, but have a poorer prognosis given their proximity to noble organs such as eyeballs and brain, making them difficult to manage and requiring a multidisciplinary center. Through a case report and an updated review of the literature, we will demonstrate the management of a giant scalp sarcoma infiltrating the occipital bone.

## Case Report

A 22-year-old patient with a history of a cutaneous scalp tumor operated on 7 months ago, whose histological examination was consistent with a round-cell sarcoma. The patient was lost to follow-up and then returned with a local recurrence of considerable volume. Clinical examination on admission revealed an asthenic patient with an antalgic attitude (head in hands) in generally poor condition. Examination of the scalp revealed a mass in the occipital region, conical in shape, poorly defined and irregular, with areas of ulceration that were very painful and bled easily on contact, approximately 7cm tall and 12cm high (Figure 1). Examination of the lymph nodes and the rest of the somatic examination were unremarkable. In view of this clinical picture, radiological exploration was imperative, and a cerebral CT scan was performed first, which came back in favor of a malignant lesioned process infiltrating the occipital bone, its outer table, but without endocranial extension (Figure 2).

This process is characterized by significant contrast uptake, attesting to its hypervascularized nature. According to the hypervascular nature of the lesion, an angioscanner was performed, confirming the hypervascular nature of the lesion with the presence of two branches of the occipital artery feeding the tumor (Figure 3). The patient's case was discussed at the multidisciplinary concertation meeting, where the decision to proceed with surgery, including cranial occipital surgery and reconstruction. The surgical procedure was performed under general anesthesia, in the presence of two surgical teams, maxillofacial and neurosurgical. The lesion was traced, with 2cm margins, during the intubation procedure, trauma to the tumor caused significant hemorrhage, leading to hemorrhagic shock,

necessitating transfusion of packed red blood cells and fresh-frozen plasma, and the initiation of vasoactive therapy. After stabilization of the patient's hemodynamic condition, monobloc excision of the tumor with occipital bone flap was performed, which also controlled the hemorrhage (Figure 4). A cementum cranioplasty was performed after controlling the bleeding and suspending the dura, then the cementum was covered by a bucket-handle scalp flap harvested from the two superficial temporal pedicles instead of a microsurgical long dorsal flap that was normally planned because of the hemorrhagic accident. The donor zone was covered at day 10 by a thin skin graft, pending completion of the therapeutic project for treatment of the alopecic zone by skin expansion (Figure 5).

The evolution was marked by the appearance of a drop in visual acuity with oculomotor disorders; intracranial hypertension was suspected and then confirmed by a fundus examination, which showed macular edema. The patient was then put on a carbonic anhydrase inhibitor with a good evolution and total recovery of visual acuity and eyeball motricity. At the operative site, the posterior sutures were loosened, exposing part of the cranioplasty cementum. Antibiotic coverage and directed healing with pro-inflammatory dressings enabled closure of the dehiscence (Figure 6). An anatomopathological study confirmed the diagnosis of round-cell sarcoma infiltrating the outer table of the occipital bone, with healthy excision margins. The patient's case was discussed again at a multidisciplinary consultation meeting, and given the size of the tumor and its recurrent nature, adjuvant radio-chemotherapy was initiated with a good outcome.

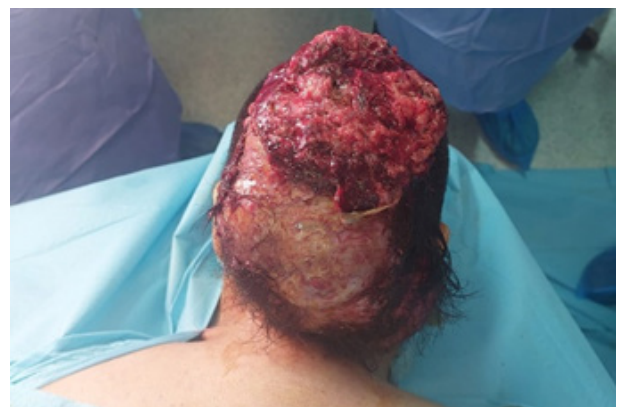

Figure 1. Preoperative tumor lesion (posterior view).

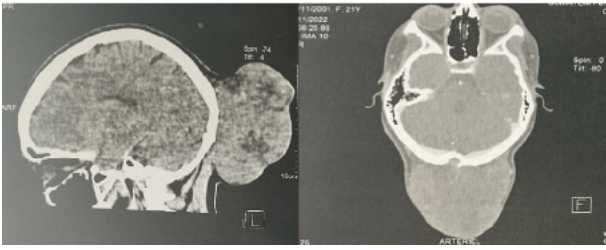


Figure 2. CT scan images of the tumor lesion.

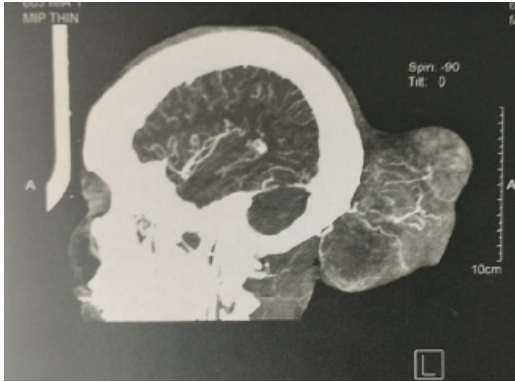


Figure 3. Angioscanner showing the hypervascular nature of the lesion.

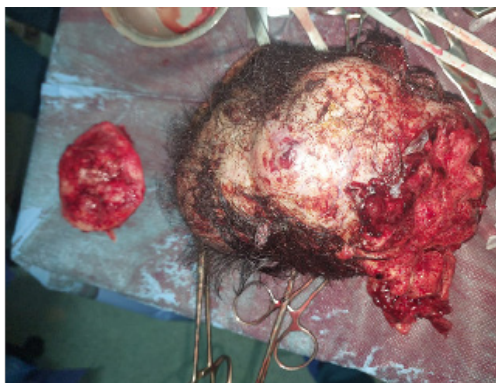

Figure 4. Removal part.

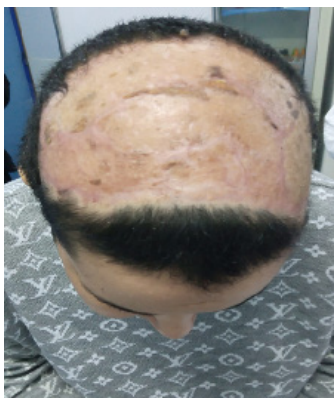

Figure 5. Grafting of the donor zone.

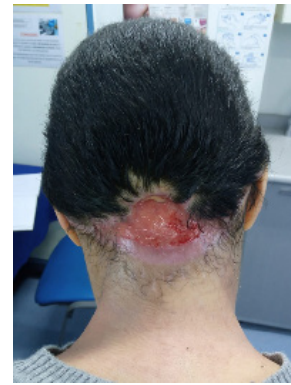

Figure 6. Dehiscence of the posterior scalp flap area.

## Discussion

The majority of sarcomas occur sporadically. However, certain genetic disorders are associated with a higher risk of sarcoma, particularly in children and young adults: type I neurofibromatosis increases the risk of peripheral sheath malignancy and rhabdomyosarcoma, Li-Fraumeni syndrome is autosomal [1], and radiotherapy is now recognized as a risk factor, responsible for 3% of sarcomas [2]. The more or less complete diagnostic triad associating pain, mass and functional discomfort. Tumor growth is centrifugal, with compression and invasion of adjacent structures. Differential diagnosis is sometimes difficult with benign tumors. 70% of soft tissue sarcomas measure over 5cm at diagnosis, and any mass over 5cm should be considered and investigated as a sarcoma until proven otherwise [3]. There is no characteristic sarcomatous appearance on imaging. Thick, irregular, intratumoral septa, irregular contour, areas of intratumoral necrosis and early and prolonged contrast enhancement are suggestive.

A benign appearance on imaging, with a round, homogeneous image diffusely taking on contrast, is perfectly compatible with a genuine sarcoma, and it is essential in such cases to evoke the diagnosis so that the rules for biopsy can be respected [1]. Cytopuncture is not recommended, given the tumor heterogeneity of sarcomas, and the need for representative samples including the various tumor contingents. The initial surgical biopsy can be replaced by needle microbiopsies under radiological guidance, with high sensitivity (greater than 90%) and lower sensitivity (60-70% in the case of low-grade tumors [4]). The biopsy path is tattooed for removal during surgical excision. In well-trained teams, surgical biopsy is now performed only when microbiopsy has failed [4]. According to the risk of metastatic disease, extension workup is systematically performed. Surgical treatment is the cornerstone

of management, and the quality of excision is a major factor in prognosis. However, craniofacial localization exposes the patient to a higher risk of initial inoperability and insufficient resection, given the proximity of noble and vital organs [5]. The modalities of resection are defined preoperatively in relation to anatomical notions of tumor extension and imaging data. Surgery must include removal of biopsy scars or scars from previous surgery, as well as removal of unnecessary skin detachments and distant drainages. In patients who have undergone previous surgery and whose diagnosis of sarcoma is unknown, as in our patient's case, repeat surgery should always be discussed. Noria et al. found 30% residual disease after initial inappropriate surgery. Tumor fragmentation (specified by the surgeon who performed the initial operation or by the histological report) or the notion of a dissection plane around the capsule is always synonymous with tumor invasiveness and, in the short term, exposes the patient to local recurrence. Surgical revision, if possible, is much more effective in ensuring local control than radiotherapy, which cannot make up for an R1 resection, let alone an R2 resection [6].

Free flaps should be widely used, as they enable wide exereses to be envisaged, reduce functional sequelae and avoid communicating the site where the flap is harvested with the exeresis site [1]. The notion of radioresistance in soft-tissue sarcomas is no longer current, and radiotherapy now has a large place in the therapeutic regimen. Recent studies show that radiotherapy combined with surgical treatment improves local control in high-grade sarcomas [7], and is most often administered postoperatively [8]. Because of the surgical difficulties associated with the anatomical constraints of the craniofacial region, chemotherapy is proposed in high-grade chemosensitive histologies to promote resectability and quality of resection.

### Conflict of Interest

There is no conflict of interest to declare.

### References

- [1] B. Hammami et al., "Les sarcomes de la tête et du cou," *Ann. d'Oto-Laryngologie Chir. Cervico-Faciale*, vol. 125, no. 6, pp. 294–300, 2008, doi: 10.1016/j.aorl.2008.09.001.
- [2] C. Cha, C. R. Antonescu, M. L. Quan, S. Maru, and M. F. Brennan, "Long-term results with resection of radiation-induced soft tissue sarcomas," *Ann. Surg.*, vol. 239, no. 6, pp. 903–910, Jun. 2004, doi: 10.1097/01.sla.0000128686.51815.8b.
- [3] J. Fayette and J. Y. Blay, "Les sarcomes des tissus mous: Prise en charge multidisciplinaire et nouveaux concepts," *Rev. Med. Suisse*, vol. 1, no. 30, pp. 1979–1984, 2005.
- [4] I. Ray-Coquard et al., "Evaluation of core needle biopsy as a substitute to open biopsy in the diagnosis of soft-tissue masses," *Eur. J. Cancer*, vol. 39, no. 14, pp. 2021–2025, Sep. 2003, doi: 10.1016/s0959-8049(03)00430-1.
- [5] Z. Gil et al., "Analysis of prognostic factors in 146 patients with anterior skull base sarcoma: an international collaborative study," *Cancer*, vol. 110, no. 5, pp. 1033–1041, Sep. 2007, doi: 10.1002/cncr.22882.
- [6] S. Noria et al., "Residual disease following unplanned excision of soft-tissue sarcoma of an extremity," *J. Bone Joint Surg. Am.*, vol. 78, no. 5, pp. 650–655, May 1996, doi: 10.2106/00004623-199605000-00003.
- [7] H. Strander, I. Turesson, and E. Cavallin-Ståhl, "A systematic overview of radiation therapy effects in soft tissue sarcomas," *Acta Oncol.*, vol. 42, no. 5–6, pp. 516–531, 2003, doi: 10.1080/02841860310014732.
- [8] B. O'Sullivan et al., "Preoperative versus postoperative radiotherapy in soft-tissue sarcoma of the limbs: a randomised trial," *Lancet (London, England)*, vol. 359, no. 9325, pp. 2235–2241, Jun. 2002, doi: 10.1016/S0140-6736(02)09292-9.