



## Investigating Effective Factors in Maxillary Sinus Membrane Rupture and Its Treatment Methods: A Review

Nima Dehghani <sup>1\*</sup> , Mohadeseh Azarsina <sup>2</sup>, Xaniar Mahmoudi <sup>3</sup>, Rahil Barani <sup>4</sup>, Sahar Hassantash <sup>5</sup>

Neshatafarin Manouchehri <sup>6</sup>

1. Department of Oral and Maxillofacial Surgery, School of Dentistry, Tehran University of Medical Sciences, Tehran, Iran.
2. Esthetic and Restorative Dentist, Tehran, Iran.
3. Department of Oral and Maxillofacial Surgery, Tabriz University of Medical Sciences, Tabriz, Iran.
4. Private Practice, Tehran, Iran.
5. Department of Public Health, University of Miami, Miami, FL USA.
6. Department Periodontics, Nova Southeastern University, Davie, FL, USA.

### ARTICLE INFO

Article Type:  
Review Article

Received: 12 April 2024

Revised: 12 May 2024

Accepted: 11 June 2024

\*Corresponding author:

Nima Dehghani

Department of Oral and Maxillofacial Surgery,  
school of Dentistry, Tehran University of Medical  
Sciences, Tehran, Iran.

Tel: +98-21-22273471

Fax: +98-21-88497390

Email: nimadt2002@gmail.com

### ABSTRACT

**Introduction:** Maxillary sinus floor augmentation (MSFA) surgery is a reliable treatment for patients with atrophic posterior maxilla, which can be performed concurrently with or after implant installation. This study aimed to estimate the rate of sinus membrane perforation (SMP) during MSFA surgeries and examine various risk factors associated with SMP. The efficacy of perforation treatments was also evaluated.

**Materials and Methods:** A systematic search of Scopus, PubMed, and Web of Science databases was conducted using the search terms: Implant AND Sinus AND Membrane AND Risk factor. Statistical analyses and graph creation were performed using Comprehensive Meta-Analysis (CMA) version 3. A total of 635 publications were screened, and 11 studies met the inclusion criteria, involving 1362 patients who underwent 1603 MSFA surgeries through the lateral window technique (LWT).

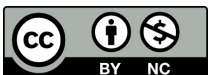**Results:** The prevalence of maxillary sinus membrane perforation among patients who had implants placed was 40.8% (Event: 0.331, 95% CI: 0.26-0.4). Implants placed near repaired perforated membranes demonstrated an average survival rate of 97.68%, whereas implants placed on intact sinus membranes had an average survival rate of 98.88%. Infection was identified as the primary complication associated with the repair of perforated sinus membranes.

**Conclusion:** Despite the high incidence of sinus membrane perforation during MSFA surgeries, the survival rates of implants near repaired membranes are comparable to those placed on intact membranes. Appropriate antibiotic prescriptions can prevent infections, contributing to favorable surgical outcomes.

**Keywords:** Maxillary sinus; Membrane rupture; Antibiotics; Survival rate.

Please cite this Article as:

Dehghani N, Azarsina M, Mahmoudi X, Barani R, Hassantash S, Manouchehri N. Investigating Effective Factors in Maxillary Sinus Membrane Rupture and Its Treatment Methods: A Review. J Craniomaxillofac Res 2024; 11(3): 138-145. DOI:



Copyright © 2024 Tehran University of Medical Sciences.

This work is licensed under a Creative Commons Attribution-NonCommercial 4.0 International license (<https://creativecommons.org/licenses/by-nc/4.0/>). Non-commercial uses of the work are permitted, provided the original work is properly cited.

## Introduction

**M**axillary sinus floor augmentation (MSFA) surgery is a well-established treatment modality for patients with atrophic posterior maxilla, facilitating implant-supported rehabilitation by providing sufficient bone substance [1,2]. Following tooth extraction, bone crest loss may reduce the ridge, particularly in the posterior maxilla [3]. The sinus floor elevation (SFE) technique, first proposed by Tatum and later refined by Boyne and James, provides adequate bone height for implant placement. This procedure can be executed in a single stage with implant insertion or in a two-stage process for significant atrophies [4]. The survival rates of implants placed using MSFA are comparable to those in unaltered bone. SFE can be performed either in a single stage with simultaneous implant insertion or in a two-stage process in situations where significant maxillary atrophy prevents achieving satisfactory primary stability [5,6].

During surgery, the sinus membrane may be perforated due to iatrogenic factors stemming from sub-optimal surgical techniques or individual anatomical variations, which can complicate the procedure [7]. Common errors associated with poor surgical technique include inappropriate selection of surgical instruments or the application of excessive force on the sinus membrane, leading to iatrogenic perforation. Additionally, anatomical factors such as a thin sinus membrane, lower friability and elasticity, and stronger bonds with bone surfaces and sinus septa can contribute to these complications [1]. Sinus membrane perforation (SMP) is the most prevalent complication associated with SFE, with reported prevalence rates ranging from 10.0% to 60.0%. SMP can result in implant failure and issues related to impaired augmentation post-surgery [8].

Surgeons may encounter several risk factors during SFE that could impact the surgery's outcome [8]. Numerous studies have investigated various potential causative factors, including anatomical variations of the maxillary sinus and different SFE methods, in relation to their propensity to cause SMP [8-11]. Membrane perforation remains the most common adverse event following SFA surgery, with reported incidences ranging from 7% to 60% [12-14]. This study aims to estimate the rate of SMP and identify various risk factors associated with this complication. Additionally, the efficacy of perforation treatment was evaluated during subsequent follow-up visits.

## Materials and Methods

### Search strategy

This systematic review and meta-analysis were conducted following the Preferred Reporting Items for Systematic Reviews and Meta-Analyses (PRISMA) guidelines. Databases including Scopus, PubMed, and Web of Science were systematically searched. The search terms used were: "Implant AND Sinus AND Membrane AND Risk factor." Using Endnote software for citation management, we searched for and cataloged English-language publications. All articles included in this study were published between 2000 and January 2023. Studies were screened and selected based on inclusion criteria by reviewing the titles, abstracts, and full texts of the search results. Inclusion criteria comprised studies focusing on risk factors for maxillary sinus membrane rupture, original cohort studies, case-control studies, and clinical trials. Exclusion criteria included studies with less than six months of follow-up, case reports, review articles, and duplicate studies. No primary human or animal research was conducted for this review; thus, IRB approval and informed consent were not required. All studies included were independently reviewed and approved by their respective ethical boards.

### Quality assessment and data extraction

The Rayyan platform was used to screen and extract data from the included studies. Two researchers performed the quality assessment using the nine-point Joanna Briggs Institute critical appraisal checklist for studies, resolving any disagreements through consensus. The included studies met more than half of the quality assessment criteria. Data extracted from the studies included publication year, country, number of subjects, sinus elevation technique, perforation occurrence, management of perforation complications, and mean follow-up period. Additionally, statistical data such as publication year, study design, research question, number and type of articles, language and country of the study, type of device used, and participants' profile data were obtained.

### Statistical Analysis

Statistical analysis and graph creation were performed using Comprehensive Meta-Analysis (CMA) version 3 (Biostat Inc., Englewood, NJ), utilizing a random effects model based on forest plots, suitable for heterogeneous populations compared to fixed models. Data summary included the calculation of the standard deviation of the mean with a 95% confidence interval.

The I-squared ( $I^2$ ) test was employed to determine sample heterogeneity. Visual bias was assessed using a funnel plot, and Egger’s regression test was used to verify it, with  $P < 0.05$  indicating a statistically significant publication bias.

### Results

Based on the purpose of the study, 635 publications from the Scopus, PubMed, and Web of Science databases were examined. After eliminating duplicate articles and screening according to the inclusion and exclusion criteria, nine studies were deemed eligible for full-text review (Figure 1). This investigation included studies with retrospective, prospective, case-control, and cohort designs. Table 2 presents the data extracted from each study, including authors, publication year, study type, number of patients treated, number of MSFAs performed using lateral approaches, number of perforations that occurred during surgery, percentage of perforations reported, management of perforations, and the main consequences observed when Schneiderian membrane perforation occurred. The eleven studies included a total of 1362 patients, with a mean age of 56 years, who underwent 1603 MSFA surgeries through

lateral windows. The average rate of Schneiderian membrane perforation was 40.8% (540 perforations). The perforations were managed using various methods, including clot formation, sutures, collagen membranes, platelet-rich fibrin (PRF), hemostatic agents, laminar bone, and block grafts. The most frequent postoperative complication associated with perforated sinus membranes was the presence of infections. Park et al. reported higher rates of postoperative complications in patients with perforated membranes, such as bleeding at the perforation site, cystic fluid or purulent discharge, dislocation of the graft into the sinus, nasal bleeding, and facial swelling [15]. Membrane perforation is the most frequent complication in maxillary sinus floor augmentation. Based on the meta-analysis of the nine studies presented in Figure 2, the prevalence of maxillary sinus membrane perforation was 40.8% (Event: 0.331, 95% CI: 0.26-0.4) among patients who received implants.

### Publication bias

A bias test was conducted using Egger’s method, which revealed no significant bias in the prevalence of perforation according to Egger’s test.

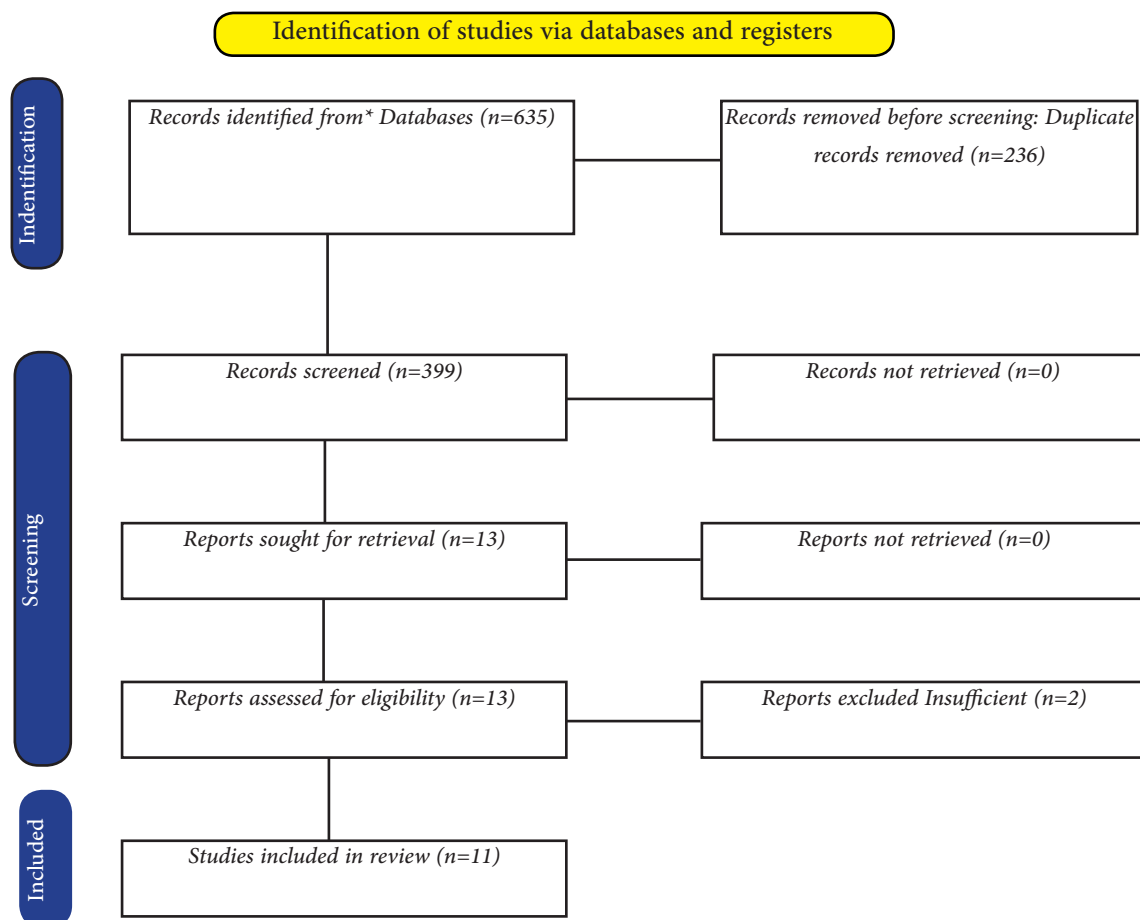
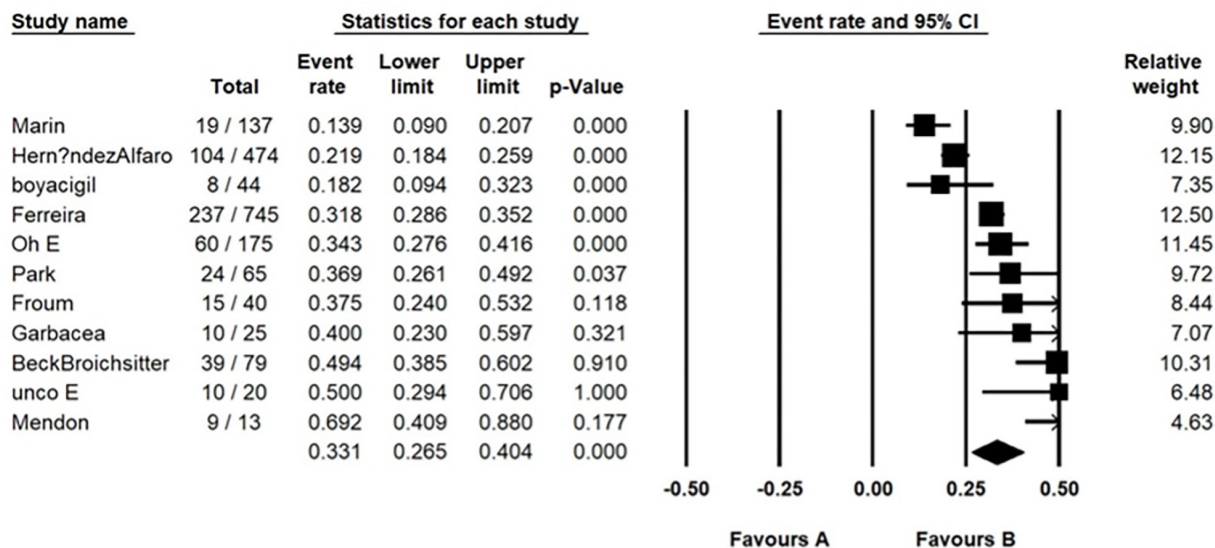


Figure 1. PRISMA flowchart.

**Table 1.** Number of treated patients, number of perforations, percentage of recorded perforations, management of perforation performed and main complications in selected studies.

Author/ Year	Type of study	Patients (num- ber)	Sinus lift (num- ber)	Perfo- rations (number)	Perforations rate	Management of Perfo- rations	Complications	Ref
Park et al. 2019	Retrospective Cohort	63	65	24	39%	Clot formation	Infection	(15)
Boyacıgil eta l. 2021	Prospective Cohort	25	-	8	1802%	Crestal sinus grafting	infection, bleeding, swelling	(30)
de Almeida Malzoni et al. 2021	Following case series	13	-	9	69%	Clot formation	Infection- mucus	(13)
Garbacea et al. 2012	Retrospective Cohort	25	25	10	40%	-	Infection- Pain	(31)
Marin et al. 2019	Retrospective Cohort	137	40	19	13.9%	bone block	Pain	(8)
Beck- Bro- ichsitter et al. 2018	Retrospective cohort	63	79	37	49.3%	<5 mm: collagen memb or fibrin glue or clot. >5 mm: suturing + collagen memb	Periimplantitis	(32)
De Almei- da Ferreira et al. 2017	Retrospective cohort	531	745	237	31.8%	Collagen membr + Reabsorbable suture for all perforationsc	Areas with chronic in- flammatory infiltration	(20)
Öncü E et al. 2017	Retrospective cohort	16	20	10	50%	PRF (<10 mm)	-	(25)
Froum et al. 2013	Retrospective cohort	23	40	15	37/5%	Resorbable collagen membrane (< 10 mm)	-	(33)
Oh et al. 2011	Retrospective cohort	128	175	60	34%	Resorbable hemo- static agente Surgicel (small-moderate perfo- rations)	Infection in 3 of the 60 perfo- rations	(34)
Hernán- dez- Alfaro et al. 2008	Retrospective cohort	338	474	104	22%	0-5 -collagen membr o suturing 5- 10 -collagen memb + laminar Bone >10 -laminar bone, buc- cal fat pad, mandibular bone block	Pain/sensitivity	(18)
Total	-	1362	1603	540	40.8%	The main treatment was collagen Membrane	Infection was the most frequent compli- cation	



Meta Analysis

Figure 2. Membrane perforation prevalence in MSFA.

Table 2. Information on the total number of implants placed, the number of implants placed under perforated membranes, the number of implants placed under non-perforated membranes and their survival rate (%), and the average period after each Day.

Author/year	Implants (number)	Implants inserted under perforated membranes (number)	Implants inserted under intact membranes (number)	Implant survival rate in perforated membranes	Implant survival rate in intact membranes	Mean follow-up (months)
Park et al. 2019	122	44	78	100%	100%	Perforation group: 11.52 (±6.6) Control group: 10.38 (6.73)
Beck- Broichsitter et al. 2018	175	92	89	9/98%	100%	Perforation group: 31 (±24) Control group: 20 (±18)
De Almeida Ferreira et al. 2017	1588	523	1065	1/97%	7/97%	Perforation group: 24 Control group: 24
Öncü E et al. 2017	35	15	20	100%	100%	Perforation group: 6-12 Control group: 6-12
Froum et al. 2013	80	35	45	100%	5/95%	Perforation group: 6-32 Control group: 6-32
Oh et al. 2011	438	134	304	01/97%	99%	32-6
Hernández- Alfaro et al. 2008	1166	272	894	9081%	100%	12
<b>Total</b>	<b>3604</b>	<b>1115</b>	<b>2495</b>	<b>68/97%</b>	<b>88/98%</b>	

## Discussion

The lateral window technique enables MSFA procedures with either simultaneous or delayed implant placement [16]. The success of this procedure depends on preserving the Schneiderian membrane and effectively sealing any perforations that occur [1,17]. During MSFA procedures utilizing the lateral window technique, membrane perforation is the most common intraoperative complication [1]. In this systematic review, which included 1362 patients undergoing 1603 MSFA procedures with lateral access, the mean perforation rate was 40.8%. Despite the widespread use and familiarity with MSFA, there are no established criteria for halting the procedure or evidence-based guidelines for sealing defects. Most reported cases involved the use of collagen membranes for repair, albeit in various manners. Based on the study results, it can be inferred that perforations smaller than 5 mm can be repaired by folding the membrane itself or using absorbable sutures [1,18]. For perforations between 5mm and 10mm, a slowly resorbable collagen membrane is preferred as it facilitates perforation repair and seals the defect. Additional treatments may include absorbable hemostatic agents, absorbable sutures, or platelet-rich fibrin (PRF) [19].

Ferreira et al. used adhesives to fix a collagen membrane to the perforations and secure the graft material [20]. Testori et al. noted that significant defects might cause collagen membrane displacement during grafting material placement, leading to inadequate graft accommodation [21]. They recommended that repair membranes be rigid enough to prevent collapsing into holes when wet and cover the hole and the surrounding area. After repairing the hole, sinus augmentation should be delayed for 3-6 weeks [22]. This waiting period allows the membrane to heal, facilitating the re-entry process. Conversely, defects treated with collagen membranes exhibited a high degree of fibrosis, inflammatory infiltrate, and epithelial deficiency [23,24].

PRF stimulates angiogenesis and the vascularization [25]. The fibrin network in PRF ensures that implant particles do not enter the sinuses. Additionally, activated platelets gradually release various proteins and growth factors (BMPs, PDGFs, IGFs, VEGF, TGF- $\beta$ 1, TGF- $\beta$ 2) that contribute to the healing of bone tissue and regulate inflammation and infection [1]. However, this method is recommended only for perforations up to 5 mm due to its inherent difficulty, limited accessibility, and membrane fragility [26,27]. This systematic review highlights the importance of accurately the size

of the membrane perforation to select the appropriate treatment. While many treatment reports published, comprehensive guidelines are limited. Upon membrane perforation, MSFA should be performed without further enlarging the hole [28,29].

## Conclusion

This systematic review revealed that implants placed near repaired perforated membranes have an average survival rate of 97.68%. While implants placed on intact membranes have an average survival rate of 98.88%. Infection was identified as the primary complication associated with the repair of perforated membranes. The use of antibiotics can prevent these adverse outcomes and contribute to a natural recovery and favorable surgical results.

## Conflict of Interest

There is no conflict of interest to declare.

## References

- [1] Díaz-Olivares LA, Cortés-Bretón Brinkmann J, Martínez-Rodríguez N, Martínez-González JM, López-Quiles J, Leco-Berrocal I, et al. Management of Schneiderian membrane perforations during maxillary sinus floor augmentation with lateral approach in relation to subsequent implant survival rates: A systematic review and meta-analysis. *International journal of implant dentistry*. 2021; 7:1-13.
- [2] Lombardi T, Bernardello F, Berton F, Porrelli D, Rapani A, Camurri Piloni A, et al. Efficacy of alveolar ridge preservation after maxillary molar extraction in reducing crestal bone resorption and sinus pneumatization: a multicenter prospective case-control study. *BioMed research international*. 2018; 2018.
- [3] Couso-Queiruga E, Stuhr S, Tattan M, Chambrone L, Avila-Ortiz G. Post-extraction dimensional changes: A systematic review and meta-analysis. *Journal of Clinical Periodontology*. 2021; 48(1):127-45.
- [4] Avila-Ortiz G, Vegh D, Mukaddam K, Galindo-Moreno P, Pjetursson B, Payer M. Treatment alternatives for the rehabilitation of the posterior edentulous maxilla. *Periodontology 2000*. 2023; 93(1):183-204.
- [5] Maddalone M, Mirabelli L, Venino PM, Karanxha

- L, Porcaro G, Del Fabbro M. Long-term stability of autologous bone graft of intraoral origin after lateral sinus floor elevation with simultaneous implant placement. *Clinical implant dentistry and related research*. 2018; 20(5):713-21.
- [6] Lundgren S, Cricchio G, Hallman M, Jungner M, Rasmusson L, Sennerby L. Sinus floor elevation procedures to enable implant placement and integration: techniques, biological aspects and clinical outcomes. *Periodontology 2000*. 2017; 73(1):103-20.
- [7] Díaz-Olivares LA, Brinkmann JC-B, Martínez-Rodríguez N, Martínez-González JM, López-Quiles J, Leco-Berrocal I, et al. REVIEW Open Access. 2021.
- [8] Marin S, Kirnbauer B, Rugani P, Payer M, Jakse N. Potential risk factors for maxillary sinus membrane perforation and treatment outcome analysis. *Clinical implant dentistry and related research*. 2019; 21(1):66-72.
- [9] Lee C-T, Choksi K, Shih M-C, Rosen PS, Ninneman S, Hsu Y-T. The Impact of Sinus Floor Elevation Techniques on Sinus Membrane Perforation: A Systematic Review and Network Meta-analysis. *International Journal of Oral & Maxillofacial Implants*. 2023; 38(4).
- [10] Krennmair S, Gugenberger A, Weinländer M, Krennmair G, Malek M, Postl L. Prevalence, risk factors, and repair mechanism of different forms of sinus membrane perforations in lateral window sinus lift procedure: a retrospective cohort study. *Clinical Implant Dentistry and Related Research*. 2021; 23(6):821-32.
- [11] Krennmair S, Malek M, Forstner T, Krennmair G, Weinländer M, Hunger S. Risk Factor Analysis Affecting Sinus Membrane Perforation During Lateral Window Maxillary Sinus Elevation Surgery. *International Journal of Oral & Maxillofacial Implants*. 2020; 35(4).
- [12] Kormas I, Pedercini A, Alassy H, Wolff LF. The Use of biocompatible membranes in oral surgery: the past, present & future directions. A narrative review. *Membranes*. 2022; 12(9):841.
- [13] de Almeida Malzoni CM, Nicoli LG, da Col dos Santos Pinto G, Pigossi SC, Zotesso VA, Verzola MHA, et al. The effectiveness of L-PRF in the treatment of Schneiderian membrane large perforations: long-term follow-up of a case series. *Journal of Oral Implantology*. 2021; 47(1):31-5.
- [14] Vanderburg NJ, Kolhatkar S, Bhola M. Management of a Large Schneiderian Membrane Perforation and Repair of the Missing Maxillary Lateral Wall Using a Collagen Barrier Alone in a Patient With Human Immunodeficiency Virus/Acquired Immunodeficiency Syndrome. *Clinical Advances in Periodontics*. 2015; 5(2):116-23.
- [15] Park WB, Han JY, Kang P, Momen-Heravi F. The clinical and radiographic outcomes of Schneiderian membrane perforation without repair in sinus elevation surgery. *Clinical implant dentistry and related research*. 2019; 21(5):931-7.
- [16] Raghoobar GM, Onclin P, Boven GC, Vissink A, Meijer HJ. Long-term effectiveness of maxillary sinus floor augmentation: A systematic review and meta-analysis. *Journal of Clinical Periodontology*. 2019; 46:307-18.
- [17] Aarbu HM, Iancu SA, Jarjour Mirea I, Mignogna MD, Samet N, Calvo-Guirado JL. Management of Schneiderian membrane perforations during sinus augmentation procedures: a preliminary comparison of two different approaches. *Journal of clinical medicine*. 2019; 8(9):1491.
- [18] Hernández-Alfaro F, Torradeflot MM, Marti C. Prevalence and management of Schneiderian membrane perforations during sinus-lift procedures. *Clinical oral implants research*. 2008; 19(1):91-8.
- [19] Soldatos NK, Stylianou P, Koidou VP, Angelov N, Yukna R, Romanos GE. Limitations and options using resorbable versus nonresorbable membranes for successful guided bone regeneration. *Quintessence International*. 2017; 48(2).
- [20] de Almeida Ferreira CE, Martinelli CB, Novaes Jr AB, Pignaton TB, Guignone CC, de Almeida ALG, et al. Effect of Maxillary Sinus Membrane Perforation on Implant Survival Rate: A Retrospective Study. *International Journal of Oral & Maxillofacial Implants*. 2017; 32(2).
- [21] Testori T, Wallace SS, Del Fabbro M, Taschieri S, Trisi P, Capelli M, et al. Repair of large sinus membrane perforations using stabilized collagen barrier membranes: surgical techniques with histologic and radiographic evidence of success. *The International journal of periodontics & restorative*

- dentistry. 2008; 28(1):9-17.
- [22] Boreak N, Maketone P, Mourlaas J, Wang W, Yu P. Decision tree to minimize intra-operative complications during maxillary sinus augmentation procedures. *J Oral Biol.* 2018; 5(1):8.
- [23] Von Arx T, Broggini N, Jensen SS, Bornstein MM, Schenk RK, Buser D. Membrane durability and tissue response of different bioresorbable barrier membranes: a histologic study in the rabbit calvarium. *International Journal of Oral & Maxillofacial Implants.* 2005; 20(6).
- [24] Bozkurt A, Apel C, Sellhaus B, van Neerven S, Wessing B, Hilgers RD, et al. Differences in degradation behavior of two non-cross-linked collagen barrier membranes: an in vitro and in vivo study. *Clinical Oral Implants Research.* 2014; 25(12):1403-11.
- [25] Öncü E, Kaymaz E. Assessment of the effectiveness of platelet rich fibrin in the treatment of Schneiderian membrane perforation. *Clinical implant dentistry and related research.* 2017; 19(6):1009-14.
- [26] Hassani A, Fazli salehi O. Complications of Sinus Grafting and the Atrophic Maxilla. *Complex Dental Implant Complications.* 2020:239-89.
- [27] Tufah HM. The Effectiveness of Different Surgical Techniques in the Management of Oro-Antral Communication and Fistula: University of Baghdad; 2022.
- [28] Ulm C, Bertl K, Strbac GD, Esfandeyari A, Stavropoulos A, Zechner W. Multiple perforations of the sinus floor during maxillary sinus floor augmentation to provide access to the bone marrow space: A technical report. *Implant Dentistry.* 2017; 26(6):956-60.
- [29] Alves D. Hard and soft tissue augmentation for implant placement in the aesthetic zone. 2013.
- [30] Boyacıgil DU, Er N, Karaca Ç, Koç O. The effect of residual bone height and membrane thickness on sinus membrane perforation in crestal sinus grafting: A prospective clinical study. *International Journal of Oral and Maxillofacial Surgery.* 2021; 50(2):251-7.
- [31] Garbacea A, Lozada JL, Church CA, Al-Ardah AJ, Seiberling KA, Naylor WP, et al. The incidence of maxillary sinus membrane perforation during endoscopically assessed crestal sinus floor elevation: a pilot study. *Journal of Oral Implantology.* 2012; 38(4):345-59.
- [32] Beck-Broichsitter BE, Westhoff D, Behrens E, Wiltfang J, Becker ST. Impact of surgical management in cases of intraoperative membrane perforation during a sinus lift procedure: a follow-up on bone graft stability and implant success. *International Journal of Implant Dentistry.* 2018; 4:1-8.
- [33] Froum SJ, Khouly I, Favero G, Cho SC. Effect of maxillary sinus membrane perforation on vital bone formation and implant survival: a retrospective study. *Journal of periodontology.* 2013; 84(8):1094-9.
- [34] Oh E, Kraut RA. Effect of sinus membrane perforation on dental implant integration: a retrospective study on 128 patients. *Implant dentistry.* 2011; 20(1):13-9.