



Pleomorphic Adenoma in Palatal Region of a Young Patient: A Case Report

Adel Sharifi Rayeni, Arian Yeganeh *

Department Of Oral and Maxillofacial Surgery, Bahonar Hospital, Kerman, Iran.

ARTICLE INFO

Article Type: Case Report

Received: 29 March 2024

Revised: 1 May 2024

Accepted: 11 June 2024

*Corresponding author:

Arian Yeganeh

Department of Oral Maxillofacial Surgery, Bahonar Hospital, Kerman, Iran.

Tel: +98-21-84903747

Fax: +98-21-84903747

Email: ygharian@yahoo.com

ABSTRACT

Pleomorphic adenoma is the most common benign tumor of the salivary glands. Its gender tendency is in females and mostly in the age of 20-45 years. mixed tumor has a firm consistency and no bone involvement. The mucosal memberan on it is healthy and has a normal color. It grows slowly and expands slowly. The parotid region, as the major salivary gland and the minor salivary gland, especially the palatal is the main site of this lesion. Cases of malignant changes have been found in it and it can turn into carcinoma. The patient is an 11-year-old girl without any underlying disease who referred to the outpatient clinic of Maxillofacial Surgery in Bahonar Kerman Hospital in Iran. The patient complained of a swelling in the left plat region, which he said had started about three months ago and was getting bigger. In examining the consistency of the lesion, it was firm and its color was pink like the mucosa of the normal palate. The uniformity of the mucosa was preserved on it. The dimensions of the lesion were about 3 x 2.5 square centimeters. The patient did not express pain or discomfort. First, a panoramic radiograph (OPG) was prepared. And then CBCT images were prepared with one millimeter slices. In the examination of the lesion, expansion is seen along with specific limits of the borders. The lesion did not destroy the palatine bone and did not invade the maxillary sinus. No pus drainage, inflammation, or redness was evident in the examination, and tenderness was not reported by the patient. then she refered to the endodontics part for examination of vitality tests. All of the teeth were vital. After performing diagnostic work, the patient was prepared for biopsy and enucleation and curettage of the lesion. After explaining to the patient and his parents and obtaining informed consent for the treatment and surgery. At first aspiration was done and the result was negative, then a sulcular incision was made from the area of the 4th upper right tooth to the 7th upper left mesial. After dissection, the mass was completely removed and enucleated. The mucosa of the floor of the nose remained healthy, and the area was completely curettage with a curet while maintaining the health of the nasal mucosa. Soft tissue sutured with 0-4 vicryl. Then, she underwent periodical follow-ups and the sample was sent for pathology examination. And the answer was diagnosed by seeing epithelial and myoepithelial cells in a chondromyxoid field with a capsule with well defined border, Pleomorphic Adenoma. Minor salivary glands are scattered throughout the upper respiratory-digestive system and their number is between 450-1000 and more in the oral cavity [13]. In a study conducted by Tselcos and his colleagues in 2022, the most common pleomorphic site of oral adenoma was diagnosed in the palatal region [14]. There is a difference of opinion in the treatment of pleomorphic adenoma of the palate. Some believe that enucleation with preservation of the upper mucus and some suggest extensive excision. Due to the nature of the capsule, which of course is thick in some patients and thin in some patients and attached to the palatal mucosa or absent [1], wide excision with a safe margin of 1cm is suggested by most surgeons. excision and shaving of the palatal bone in the form of an osteotomy was not needed to reduce the recurrence of the lesion, because the nature of the tumor is not an osteoblast stimulator for bone formation.

Keywords: Pleomorphic adenoma; Palatal area; Enucleation.

Please cite this Article as:

Sharifi Rayeni A, Yeganeh A. Pleomorphic Adenoma in Palatal Region of a Young Patient: A Case Report. J Craniofac Res 2024; 11(3): 190-194. DOI: [10.18502/jcr.v11i3.17662](https://doi.org/10.18502/jcr.v11i3.17662)



Copyright © 2024 Tehran University of Medical Sciences.

This work is licensed under a Creative Commons Attribution-NonCommercial 4.0 International license (<https://creativecommons.org/licenses/by-nc/4.0/>). Non-commercial uses of the work are permitted, provided the original work is properly cited.

Introduction

Pleomorphic adenoma is the most common salivary gland tumor, which affects minor and major glands. Its most common location is in the major salivary glands, parotid, and in the minor salivary glands, the palate. This benign mixed tumor has a gender tendency towards females and occurs mostly in the age group of 20-75 years [1,2]. In 1972, the World Health Organization (WHO) reported pleomorphic adenoma as a benign tumor with well-defined boundaries and including various epithelial, mucoid, myxoid and chondroid compositions [3] found in routine physical examinations [4,5]. Clinically, it is a painless submucosal mass with a firm consistency. It grows slowly and increases in size over the years. The mucosa on the lesion is healthy and intact, and if a wound is observed, it can indicate trauma or previous sampling [6]. The risk of malignancy in minor salivary glands is high and this doubt is strengthened when a mass is in these areas [7-9]. Imaging plays a vital role in diagnosis. Preparation of initial panoramic radiography and then preparation of facial spiral CT scan images with fine cuts of 1.5mm can determine the extent of bone involvement and the extent of tumor invasion to the surrounding structures [10]. Sampling and histological examination is a powerful tool in accurate diagnosis of the lesion. Pleomorphic adenoma is composed of epithelial and myoepithelial cells. Which sometimes is surrounded by a fibrous tissue called pseudocapsule. This pseudocapsule is complete in major salivary glands but sometimes incomplete in minor salivary glands [11,12].

Case Presentation

The patient is an 11-year-old girl without any underlying disease who referred to the outpatient clinic of Maxillofacial Surgery in Bahonar Kerman Hospital in Iran. The patient complained of a swelling in the left palat region, which she said had started about three months ago and was getting bigger. In examining the consistency of the lesion, it was firm and its color was pink like the mucosa of the rest of the palate. The uniformity of the mucus was preserved on it. The dimensions of the lesion were about 3 x 2.5 square centimeters. The patient did not express pain or discomfort. First, a panoramic radiograph (OPG) was prepared. And then CBCT images were prepared with one millimeter slices. In the examination of the lesion, expansion is seen along with specific limits of the borders. The lesion did not destroy the palatine bone and did not invade the maxillary sinus. No pus drainage,

inflammation, or redness was evident in the examination, and tenderness was not reported by the patient. then she referred to the endodontics part for examination of vitality tests. All of the teeth were vital. After performing diagnostic work, the patient was prepared for sampling and enucleation and curettage of the lesion. After explaining to the patient and his parents and obtaining informed consent for the treatment and surgery, the patient was taken to the operating room. Then she underwent nasal intubation from the right nostril. After preparation and drape and injection of lidocaine anesthesia containing epinephrine, first aspiration was done with a 10cc syringe and the result was negative, then a sulcular incision was made from the area of the 4th upper right tooth to the 7th upper left mesial. Dissection was performed and minor nasopalatine artery bleeding was controlled. And the greater palatine artery remained undamaged. After exposing the mass with a clear thick capsule, it was decided to completely dissect the mass from the palatal mucosa. After dissection, the mass was completely removed and enucleated. The mucosa of the floor of the nose remained healthy, and the sharp bones in the empty space were punched with a rongeur to prevent perforation of the mucosa, and the area was completely curetted with a medium-sized curet while maintaining the health of the nasal mucosa.

Then the area was completely washed with normal saline. And after checking the position and making sure that there is no remaining lesion and placing gel foam to control hemostasis and prevent possible hematoma, the soft tissue and the papillae were sutured with 0-4 vicryl. Then a sterile gauze with tetracycline ointment 1% was placed in the area as a compress dressing. The patient was extubated and transferred to recovery. And after partial recovery, she was transferred to the ward and under the antibiotic regimen of cefazolin 500 mg every 6 hours and dexamethasone 4 mg every 8 hours for two days and 0.2% chlorhexidine mouthwash twice a day and using ice pack and head elevation 45 degree. She discharged after three days. Then, she underwent periodical follow-ups and the sample was sent for pathology examination. And the answer was diagnosed by seeing epithelial and myoepithelial cells in a chondromyxoid field with a capsule with well defined border, pleomorphic adenoma.

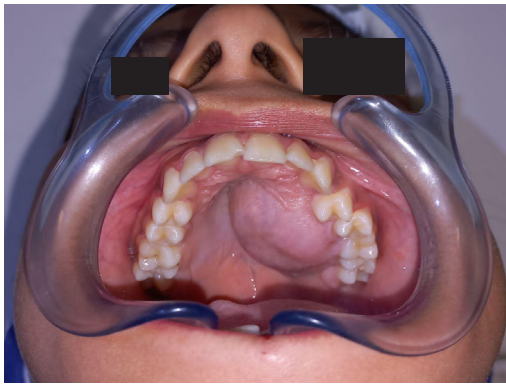


Figure 1. Clinical view of mass in left side of palate.

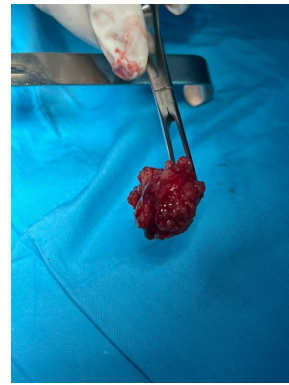


Figure 5. The gross complete lesion.

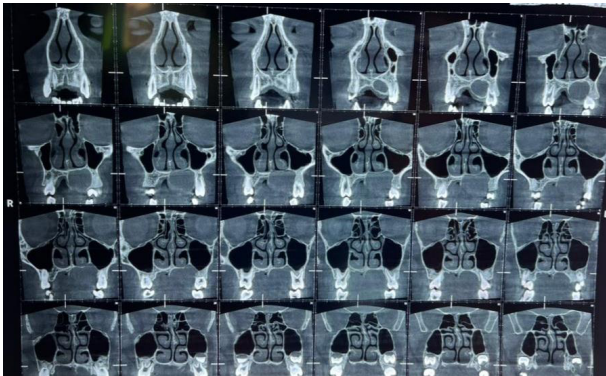


Figure 2. Coronal cut of CBCT-expansion of the lesion but not invasive to the maxillary sinus.

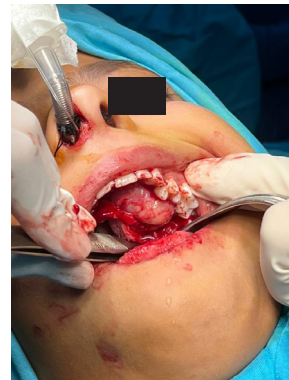

Figure 6. Tumor dissection.

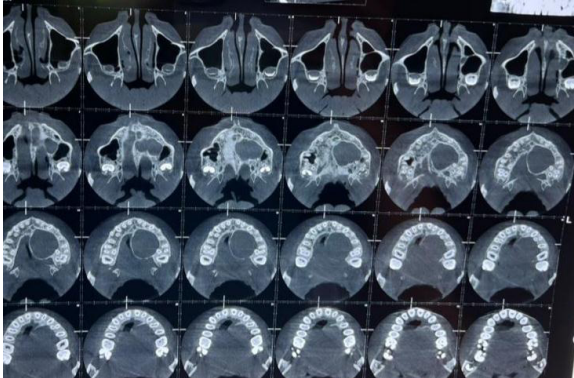


Figure 3. Axial cut of CBCT-extension of the lesion.

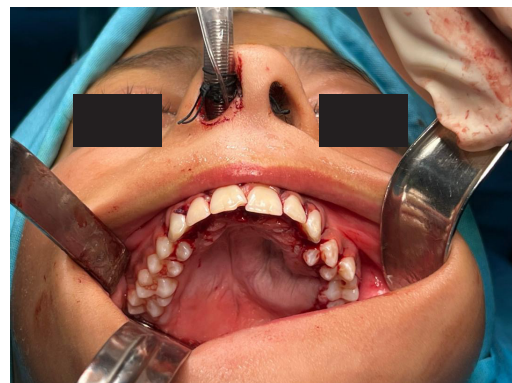


Figure 7. After suturing the palatal mucosa.

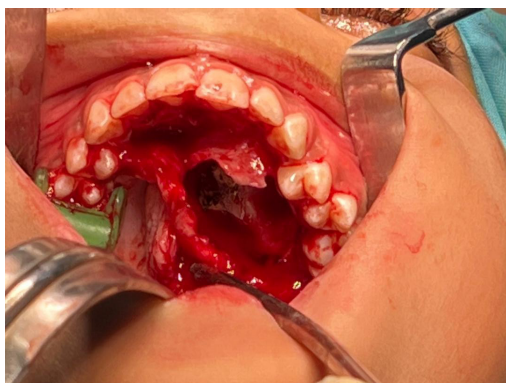


Figure 4. The palatal bone after complete enucleation and curettage is limited to midline.

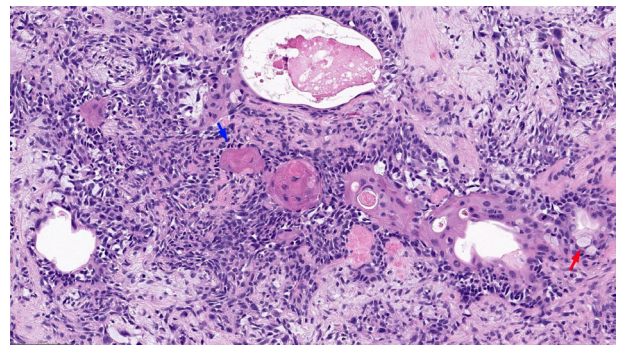


Figure 8. Pleomorphic Adenoma histologic features.

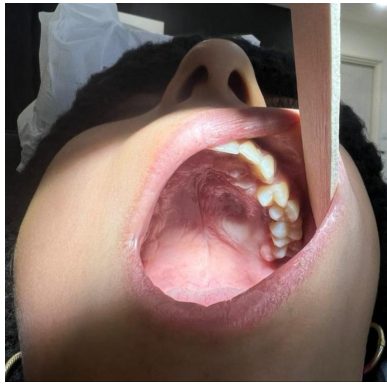

Figure 9. 3 month after operation follow up.

Discussion

Minor salivary glands are scattered throughout the upper respiratory-digestive system and their number is between 450-1000 and more in the oral cavity [13]. In a study conducted by Tselcos and his colleagues in 2022, the most common pleomorphic site of oral adenoma was diagnosed in the palatal region [14]. There is a difference of opinion in the treatment of pleomorphic adenoma of the palate. Some believe that enucleation with preservation of the upper mucosa and some suggest extensive excision. Due to the nature of the capsule, which of course is thick in some patients and thin in some patients and attached to the palatal mucosa or absent [1], wide excision with a safe margin of 1cm is suggested by most surgeons. excision and shaving of the palatal bone in the form of an osteotomy was not needed to reduce the recurrence of the lesion, because the nature of the tumor is not an osteoblast stimulator for bone formation. In a study conducted by Abbate and his colleagues in Italy in 2019, he examined the long-term follow-up of patients who underwent surgery in 2002-2016. And he examined the complications caused by the removal of the

pleomorphic adenoma tumor in the parotid and other places, most of which were hematoma and hypoesthesia in the removal of the superficial lobe of the parotid, and then temporary damage to the facial nerve and Frey's syndrome were noted [15]. In a retrospective study conducted by Studart Soares and et al in 2016 on the Brazilian population, different approaches to pleomorphic adenoma surgery in the palatal region were discussed, including tumor excision by removing the mucosa covering it, tumor removal with bone osteotomy around the lesion. And the last method was the spontaneous regression of the lesion following an incisional biopsy. The most complications were patient discomfort and dysphonia. Soares considered the most effective treatment to be the complete removal of the

tumor and its covering mucosa with or without osteotomy [16]. In 2021, a study was done by Tamba and his colleagues in Senegal on a 61-year-old woman with giant pleomorphic adenoma measuring 24x35x47 (mm), and after two months, a prosthesis was placed to reconstruct the palate, and after 6 months of follow-up, no recurrence was reported [17].

Conflict of Interest

There is no conflict of interest to declare.

References

- [1] Wu YC, Wang YP, Cheng SJ, Chen HM, Sun A, Chang JY: Clinicopathological study of 74 palatal pleomorphic adenomas. *J Formos Med Assoc.* 2016, 115:25-30.
- [2] Mukul SK, Kumar A, Mokhtar EA, Pandey S: Pleomorphic adenoma of buccal mucosa: an uncommon presentation among cheek swellings. *IP Indian J Anat Surg Head Neck Brain.* 2017, 3:48-50
- [3] Traiger J, Rosen MB. Mixed tumor of the cheek; report of a case. *Oral Surg Oral Med Oral Pathol,* 1965; 19:711-714.
- [4] Berdal P, Hall JG. Parapharyngeal growth of parotid tumours. *Acta Otolaryngol Suppl,* 1969; 263:164-6.
- [5] Carr RJ, Bowerman JE. A review of tumors of the deep lobe of the parotid salivary gland. *Br J Oral Maxillofac Surg,* 1986; 24:155-68.
- [6] Moon SY: Surgical management of the palatal pleomorphic adenoma. *J Craniofac Surg.* 2019, 30:e580-2.
- [7] Gao M, Hao Y, Huang MX, et al.: Salivary gland tumours in a northern Chinese population: a 50-year retrospective study of 7190 cases. *Int J Oral Maxillofac Surg.* 2017, 46:343-9.
- [8] Chaturvedi M, Jaidev A, Thaddanee R, Khilnani AK: Large pleomorphic adenoma of hard palate. *Ann Maxillofac Surg.* 2018, 8:124-6.
- [9] Da Silva LP, Serpa MS, Viveiros SK, et al.: Salivary gland tumors in a Brazilian population: a 20-year retrospective and multicentric study of 2292 cases. *J Craniofac Surg.* 2018, 46:2227-33.
- [10] Hiyama T, Kuno H, Sekiya K, Oda S, Kobayashi T: Imaging of malignant minor salivary gland tumors of the head and neck. *Radiographics.* 2021,

41:175-91.

- [11] Berrerhdoche Z, Lachkar A, Benfadil D, Elayoubi F: Pleomorphic adenoma of the palate: a case report . *Cureus*. 2022, 14:e31003.
- [12] De Lima FF, Bezerra CP, Rocha AC, Martins IS, Bernaola-Paredes WE: Surgical management of palatal pleomorphic adenoma (PPA) recurrence after 10 years, treated at a Brazilian Center - a case report. *Ann Maxillofac Surg*. 2020, 10:533-6.
- [13] Tian Z, Li L, Wang L, Hu Y, Li J: Salivary gland neoplasms in oral and maxillofacial regions: a 23-year retrospective study of 6982 cases in an eastern Chinese population. *Int J Oral Maxillofac Surg*. 2010, 39:235-42.
- [14] Antonios Tsekos · Dimitris Tatsis · Anastasia Fotiadou · Nikolaos Kechagias · Konstantinos Vahtsevanos, Pleomorphic Adenoma of Palatal Minor Salivary Glands with Bone Infiltration: Case Report with Long-term Follow-up, *Comprehensive Clinical Medicine* (2022) 4:215 <https://doi.org/10.1007/s42399-022-01297-9>.
- [15] Paola Bonavolontà, Department Neurosciences, Reproductive and Odontostomatological Sciences, Federico II University of Naples, Naples, Italy, Giovanni Dell'Aversana Orabona Department Neurosciences, Reproductive and Odontostomatological Sciences, Federico II University of Naples, Naples, Italy, Postoperative complications after removal of pleomorphic adenoma from the parotid gland: A long-term follow up of 297 patients from 2002 to 2016 and a review of publications, *British Journal of Oral and Maxillofacial Surgery* Volume 57, Issue 10, December 2019.
- [16] Eduardo Costa Studart Soares , DDS, MS, PhD/ Federal University of Ceará (Professor Titular) and et al, Surgical approach to pleomorphic adenomas arising in the palate: a 10-year retrospective study in a Brazilian population, *J Oral Diag* [online]. 2016.
- [17] Babacar Tamba, Mamadou Diatta, Mouhammad Kane, Baidy Lo, Abdou Ba, Soukeye Dia Tine, Oral Surgery Department, Odontology and Stomatology Institute, Cheikh Anta Diop University, Dakar, Senegal, Odontostomatology Department, General Hospital Idrissa Pouy, Dakar, Senegal, Management of a giant pleomorphic adenoma of the palate: Case report, *Advances in Oral and Maxillofacial Surgery*, 2021.