



Third molar surgery: Insights from recent literature

Majid Beshkar^a, Mehrnoush Momeni^b, Mahboube Hasheminasab^{a*}

^a Craniomaxillofacial Research Center, Shariati Hospital, Tehran University of Medical Sciences, Tehran, Iran; ^b Craniomaxillofacial Research Center, Shariati Hospital AND Department of Oral and Maxillofacial Surgery, School of Dentistry, Tehran University of Medical Sciences, Tehran, Iran

ARTICLE INFO

Article Type:

Review Article

Received: 20 Apr 2014

Revised: 15 May 2014

Accepted: 30 May 2014

*Corresponding author: Mahboube Hasheminasab, Craniomaxillofacial Research Center, Shariati Hospital, Tehran University of Medical Sciences, Tehran, Iran

Tel: +98-2184902473

Fax: +98-2184902473

Email: mahboube.hasheminasab@gmail.com

ABSTRACT

Surgical removal of impacted third molars is amongst the most common surgical procedures performed by oral and maxillofacial surgeons. Every year many articles are published in different journals regarding different aspects in such surgeries. It is necessary to translate such vast amounts of data into simple and easily comprehensible sentences for the students of dentistry and oral surgery. This article is a modest and simple review of the recent literature and presents a number of tips, recommendations, and cautions intended to improve the quality of clinical practice in third molar surgery.

Keywords: Third Molar, Surgical Removal

Introduction

A great number of articles are published annually in various journals regarding different aspects of surgical extraction of impacted third molars. Some of these articles give insightful tips and reveal important findings that might be helpful in improving the knowledge and surgical competence of oral surgeons. Academic textbooks appear to be slow in incorporating these articles and presenting their valuable findings to their audience. It could be considered a waste of financial and human resources if such a large number of annually published data and statistics are not appropriately conveyed to dental students and oral surgery residents. The current article is a simple review of recent literature regarding tips, recommendations, and cautions intended to improve the quality of clinical practice in third molar surgery.

1.

There are a number of radiographic features that help the surgeon assess a close contact between the inferior alveolar canal and the tooth root when evaluating a preoperative panoramic radiograph for planning surgical extraction of an impacted mandibular third molar. These radiographic markers include: darkening of the root; interruption of the

radio opaque line that depicts the cortical roof of the canal; diversion of the canal, which is the result of a change in direction of the canal as it crosses the tooth; deflection of the root which can be seen as the tooth roots hook around the canal and narrowing of the canal (Figures 1 and 2). There is currently no clear answer to the questions of which radiographic feature can be more predictive of a true contact between the root and the canal or which markers are most probably associated with an increased risk of nerve injury during the surgical procedure. Different studies have identified different radiographic markers as being more reliable and the literature remains controversial in this regard. However, all these studies do agree that every one of these markers should be considered as an important preoperative finding by the surgeon and that the simultaneous presence of two or more of these markers is associated with an increased risk of nerve injury [1]. Moreover, the absence of any of these markers on a preoperative panoramic radiograph indicates a minimal chance of nerve injury [2].

If a patient's preoperative panoramic radiograph showed one or more of these radiographic markers, the higher risk of nerve injury should be explained preoperatively to the patient, and a written informed consent should be obtained to avoid future negligence lawsuits.

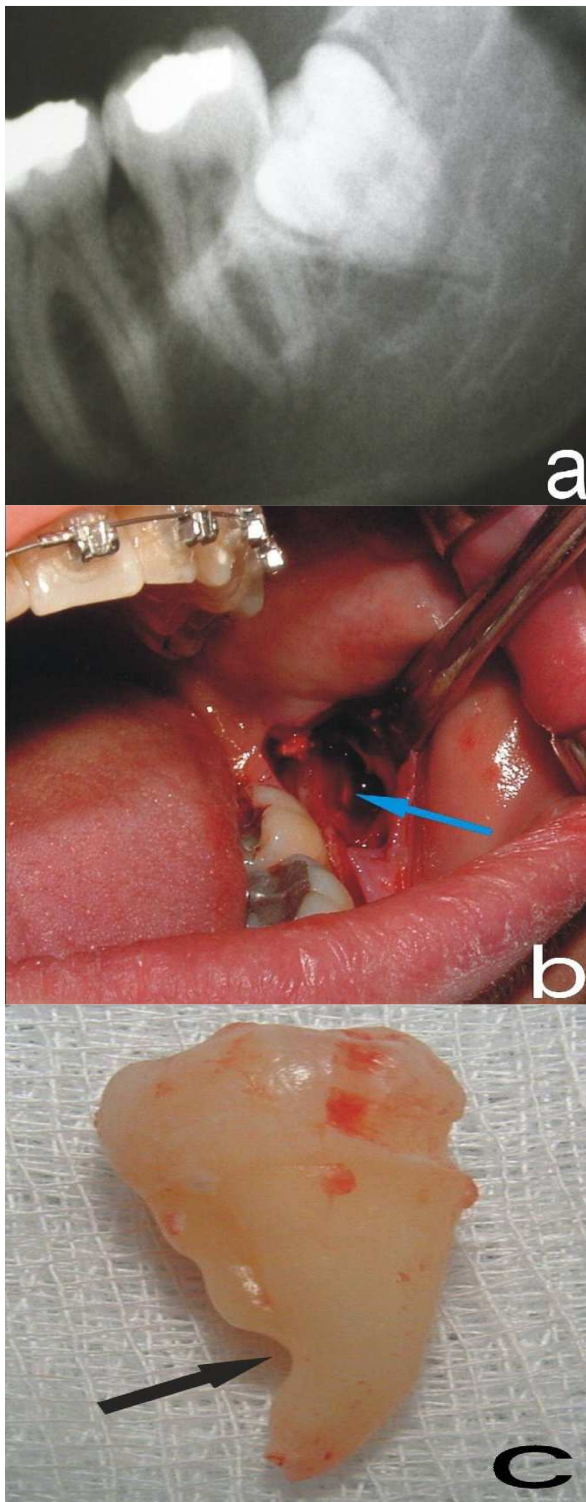


Figure 1. (a). Darkening of the root and slight narrowing and deflection of the canal are evident on the panoramic radiograph of the mandibular third molar (reproduced from Szalma et al [2]. with permission from Elsevier); (b). The inferior alveolar nerve (blue arrow) is clearly visible intraoperatively (reproduced from Szalma et al. [2] with permission from Elsevier); (c). After the extraction, a groove is seen on the lingual surface of the root (reproduced from Szalma et al [2] with permission from Elsevier)

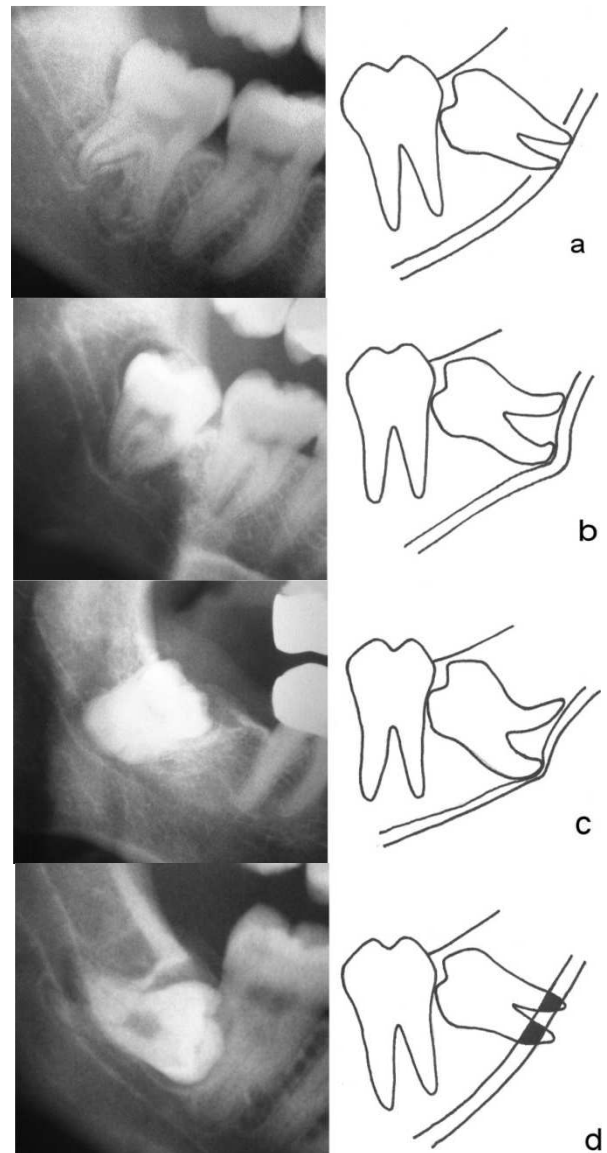


Figure 2. (a). Interruption of the superior cortical wall (reproduced from Szalma et al. [2] with permission from Elsevier); (b). Deflection of the canal (reproduced from Szalma et al. [2] with permission from Elsevier); (c). Narrowing of the canal (reproduced from Szalma et al. [2] with permission from Elsevier); (d). Darkening of the root (reproduced from Szalma et al. [2] with permission from Elsevier)

2.

Cone-beam computed tomography (CBCT) is significantly superior to panoramic radiography in predicting neurovascular bundle exposure during surgical extraction of impacted mandibular third molars. The sensitivity and specificity of CBCT and panoramic images in predicting the exposure are 93% and 77%, and 70% and 63%, respectively [3]. There is an increased risk of nerve injury during surgical procedures in cases with evidence of contact between the inferior alveolar canal and mandibular third molar root apices in preoperative CBCT images [4].

3.

Following the surgical removal of impacted mandibular third molars, the incidence of permanent dysfunction of the inferior alveolar nerve and the lingual nerve are 0.6% and 1.1%, respectively [5, 6].

4.

The neurovascular bundle occupying the inferior alveolar canal contains the inferior alveolar nerve, the inferior alveolar artery, and the inferior alveolar vein. The vein lies on top of the nerve in the 12 o'clock position, whereas the artery lies on the lingual side of the nerve, slightly superior to it. There is no change in this relationship from the lingula to the mental foramen [7]. Therefore, if the roof of the canal is exposed during the surgical procedure, the first element to come into contact with the surgical instrument or the root fragments will be the vein not the nerve.

5.

If a preoperative CBCT or panoramic radiograph reveals a dangerous proximity between the inferior alveolar canal and the root of the impacted third molar, the following surgical approaches should be strongly considered as viable alternatives to conventional surgical extraction: pericoronar osteotomy; coronectomy; staged removal of the tooth; and orthodontic-assisted surgical extraction.

Pericoronar osteotomy involves the following steps: removal of the bone all the way around the crown of a partially or fully impacted third molar in an attempt to eliminate any obstruction; slight dislocation or subluxation of the tooth to boost its eruptive potential; and repositioning the flap without suturing or with minimum number of sutures to prevent soft tissue obstruction [8]. This surgical approach promotes the potential future eruption of the tooth occlusally to a safe position away from the inferior alveolar canal. This may take 2 to 6 months to occur, after which the tooth can be safely removed with a decreased possibility of nerve injury.

Coronectomy involves exposing the tooth, cutting the crown, leaving the root in its place, and suturing the flap. This technique reduces the incidence of injury to the inferior alveolar nerve without increasing the risk of subsequent dry socket or periradicular infection [9].

In the staged removal approach, a portion of the crown is removed in the first surgery to provide a space into which the tooth could migrate. Then, 3 months later, the relationship between the roots and the canal is reexamined radiographically. If migration of the tooth has resulted in a safe position of the roots with respect to the canal, the tooth will be removed at the second surgery. Otherwise either a further portion of the residual crown will be cut away in this stage or more time is given to the tooth to migrate to a safe position where it can be surgically removed without significant risk of nerve injury [10].

Orthodontic-assisted surgical extraction involves the following steps: creation of an orthodontic anchorage; surgical exposure of the third molar crown; attaching an orthodontic bracket to the exposed crown; orthodontic extrusion of the third molar to a safe position; and finally extraction of the third molar (Figure 3) [11]. Orthodontic-assisted surgical extraction of deeply impacted mandibular third molars has a great advantage at the periodontal level, in addition to the decreased risk of nerve injury. This technique prevents periodontal involvement of the second molar by coronally raising the alveolar bone distal to the second molar as a result of the extrusive movement.

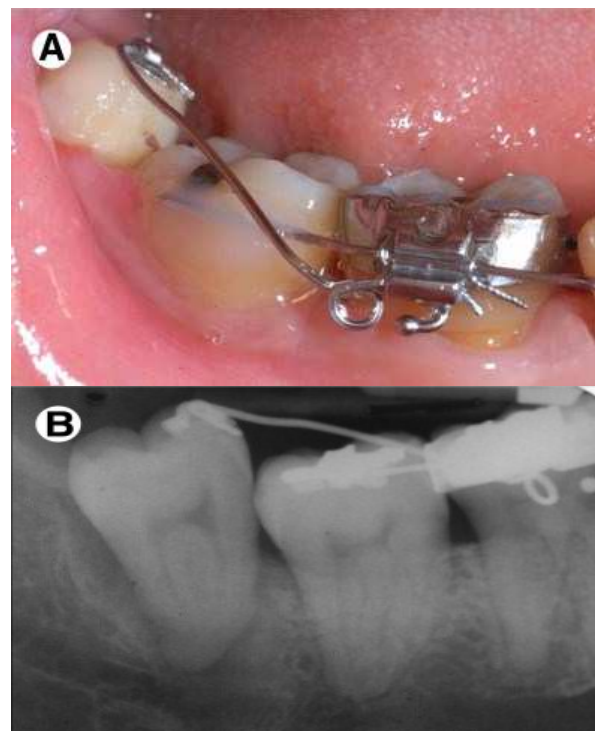


Figure 3 . A deeply impacted third molar of the right mandible (reproduced from Alessandri et al. [11] with permission from Elsevier); **(A)**. (A). After orthodontic extrusion of the tooth (reproduced from Alessandri et al. [11] with permission from Elsevier); **(B)**. (B). Radiographic view after orthodontic extrusion of the tooth (reproduced from Alessandri et al. [11] with permission from Elsevier)

6.

The use of ultrasound bone surgery significantly reduces the occurrence of postsurgical trismus and swelling in surgical removal of impacted mandibular third molars as compared to conventional rotary instruments [12].

7.

Dental follicles of all impacted third molars deserve at least an intraoperative clinical examination by the surgeon

for any abnormal findings such as induration or thickening. Do not hesitate to send the follicle of a surgically removed impacted third molar for histopathologic evaluation, if there is any abnormal clinical or radiographic finding around the crown of the tooth. Even the dental follicle of an impacted third molar with no clinical evidence of pathologic changes may reveal a malignant fibrosarcoma on histopathologic evaluation [13]. Furthermore, many asymptomatic and radiographically normal impacted mandibular third molars show histopathologic evidence of dentigerous cystic changes in their follicles [14].

8.

In case of surgical removal of impacted mandibular third molars, there is no significant difference between envelope and triangular flap in terms of postoperative pain, swelling, fever, wound infection, and the probing depth of adjacent teeth after healing [15].

9.

After removing the tooth and before suturing the surgical wound, sockets, reflected flap, and the surrounding soft tissues should be carefully and patiently inspected for any evidence of bleeding or unusual oozing. Suturing the wound in the presence of a bleeding vessel could result in serious postoperative complications such as retrobulbar hematoma [16].

After repositioning the reflected flap and before suturing, a clean gauze pad should be placed over the wound and the patient should be asked to bite over the pad for 2-3 minutes. If the gauze is soaked with significant amount of blood, the flap should be reflected for the bleeding vessel exploration.

10.

secondary closure of the surgical wound after removal of impacted mandibular third molars gives rise to significantly lesser amount of pain and swelling postoperatively compared to primary closure [17]. In primary closure, the socket is covered and sealed hermetically by the mucosal flap; while, in the secondary closure, the socket is not tightly sutured and remains in communication with the oral cavity to facilitate drainage of inflammatory products.

11.

After surgical extraction of an impacted mandibular third molar, closing the flap with an anchor suture as compared to a simple loop suture, is a better technique to prevent periodontal problems in the distal surface of the second molar [18].

12.

Patients should rest for a minimum of 15 minutes in the waiting room and not be discharged immediately after finishing the surgical procedure. This allows the surgeon to

inspect the patient again for any unusual signs and symptoms, thus preventing its progress into a catastrophic postoperative complication. For example, following surgical removal of an impacted upper third molar, periorbital ecchymosis and subconjunctival hemorrhage may appear within minutes and may imply a developing retrobulbar hematoma, which is a true medical emergency requiring prompt diagnosis and management to prevent optic nerve ischemia and blindness [16]. Loss of vision due to optic nerve ischemia may be irreversible after 90 to 120 minutes [19].

13.

After surgical removal of impacted mandibular third molars, intraoral and extraoral application of therapeutic laser do not significantly reduce the amount of postoperative pain, swelling, and trismus [20].

14.

The postoperative recovery period of the surgical removal of an impacted third molar is significantly shorter in terms of oral function and return to work when moxifloxacin (400 mg every 24 hours for 5 days) is administered orally as compared to amoxicillin and clavulanic acid (500/125 every 8 hours for 5 days) [21]. Therefore, moxifloxacin could be a useful antibiotic in patients who are allergic to beta-lactams, have oral flora resistant to macrolides, or are intolerant of either of these families of antibiotics.

15.

It has been demonstrated that administration of 2 g amoxicillin 1 hour before impacted third molar surgery significantly reduces the incidence of postoperative pain, fever, and wound infection [22]. However, administration of 1 g amoxicillin 1 hour preoperatively does not significantly reduce the postoperative infection rate, pain, swelling, and trismus [23].

16.

Patients with high anxiety have poorer postoperative recovery following surgical extraction of third molars. They feel significantly more pain and have greater trismus postoperatively compared to patients with low anxiety [24].

17.

Even uneventful surgical extraction of an impacted third molar in a healthy patient could give rise to potentially dangerous postoperative complications such as retrobulbar hematoma [16]. Although such terrifying complications are rare and should not be directly discussed with the patient in the preoperative session, the patient should be aware of these possibilities which may lead to a better cooperation in case of complications.

18.

Surgical removal of an impacted third molar could give rise to both central and peripheral sensitization of the trigeminal nociceptive system, lasting for at least one week after the surgery. This may result in the transition from acute postoperative pain to a chronic orofacial pain in susceptible individuals [25].

19.

If an impacted third molar is iatrogenically displaced into a difficult-to-access and critical anatomic location, image-guided navigational surgery should be considered as a viable option and a minimally invasive approach for precise localization and uncomplicated removal of the tooth [26].

Conflict of Interest: 'None declared'.

References

- [1] Sedaghatfar M, August MA, Dodson TB. Panoramic radiographic findings as predictors of inferior alveolar nerve exposure following third molar extraction. *J Oral Maxillofac Surg* 2005; 63(1): 3-7.
- [2] Szalma J, Lempel E, Jeges S, Szabo G, Olasz L. The prognostic value of panoramic radiography of inferior alveolar nerve damage after mandibular third molar removal: retrospective study of 400 cases. *Oral Surg Oral Med Oral Pathol Oral Radiol Endod* 2010; 109(2): 294-302.
- [3] Tantanapornkul W, Okouchi K, Fujiwara Y, Yamashiro M, Maruoka Y, Ohbayashi N, et al. A comparative study of cone-beam computed tomography and conventional panoramic radiography in assessing the topographic relationship between the mandibular canal and impacted third molars. *Oral Surg Oral Med Oral Pathol Oral Radiol Endod* 2007; 103(2): 253-9.
- [4] Nakayama K, Nonoyama M, Takaki Y, Kagawa T, Yuasa K, Izumi K, et al. Assessment of the relationship between impacted mandibular third molars and inferior alveolar nerve with dental 3-dimensional computed tomography. *J Oral Maxillofac Surg* 2009; 67(12): 2587-91.
- [5] Jerjes W, Upile T, Shah P, Nhembe F, Gudka D, Kafas P, et al. Risk factors associated with injury to the inferior alveolar and lingual nerves following third molar surgery-revisited. *Oral Surg Oral Med Oral Pathol Oral Radiol Endod* 2010; 109(3): 335-45.
- [6] Jerjes W, Swinson B, Moles DR, El-Maaytah M, Banu B, Upile T, et al. Permanent sensory nerve impairment following third molar surgery: a prospective study. *Oral Surg Oral Med Oral Pathol Oral Radiol Endod* 2006; 102(4): e1-e7.
- [7] Pogrel MA, Dorfman D, Fallah H. The anatomic structure of the inferior alveolar neurovascular bundle in the third molar region. *J Oral Maxillofac Surg* 2009; 67(11): 2452-4.
- [8] Tolstunov L. Pericoronar osteotomy as alternative treatment option for extraction of impacted mandibular third molars in proximity to inferior alveolar nerve. *J Oral Maxillofac Surg* 2010; 68(1): 231-2.
- [9] Renton T, Hankins M, Sproate C, McGurk M. A randomised controlled clinical trial to compare the incidence of injury to the inferior alveolar nerve as a result of coronectomy and removal of mandibular third molars. *Br J Oral Maxillofac Surg* 2005; 43(1): 7-12.
- [10] Landi L, Manicone PF, Piccinelli S, Raia A, Raia R. Staged removal of horizontally impacted third molars to reduce risk of inferior alveolar nerve injury. *J Oral Maxillofac Surg* 2010; 68(2): 442-6.
- [11] Alessandri BG, Bendandi M, Laino L, Checchi V, Checchi L. Orthodontic extraction: riskless extraction of impacted lower third molars close to the mandibular canal. *J Oral Maxillofac Surg* 2007; 65(12): 2580-6.
- [12] Barone A, Marconcini S, Giacomelli L, Rispoli L, Calvo JL, Covani U. A randomized clinical evaluation of ultrasound bone surgery versus traditional rotary instruments in lower third molar extraction. *J Oral Maxillofac Surg* 2010; 68(2): 330-6.
- [13] Leitner C, Hoffmann J, Krober S, Reinert S. Low-grade malignant fibrosarcoma of the dental follicle of an unerupted third molar without clinical evidence of any follicular lesion. *J Craniomaxillofac Surg* 2007; 35(1): 48-51.
- [14] Saravana GH, Subhashraj K. Cystic changes in dental follicle associated with radiographically normal impacted mandibular third molar. *Br J Oral Maxillofac Surg* 2008; 46(7): 552-3.
- [15] Monaco G, Daprile G, Tavernese L, Corinaldesi G, Marchetti C. Mandibular third molar removal in young patients: an evaluation of 2 different flap designs. *J Oral Maxillofac Surg* 2009; 67(1): 15-21.
- [16] Goshtasby P, Miremadi R, Warwar R. Retrobulbar hematoma after third molar extraction: case report and review. *J Oral Maxillofac Surg* 2010; 68(2): 461-4.
- [17] Danda AK, Krishna TM, Narayanan V, Siddareddi A. Influence of primary and secondary closure of surgical wound after impacted mandibular third molar removal on postoperative pain and swelling--a comparative and split mouth study. *J Oral Maxillofac Surg* 2010; 68(2): 309-12.
- [18] Cetinkaya BO, Sumer M, Tutkun F, Sandikci EO, Misir F. Influence of different suturing techniques on periodontal health of the adjacent second molars after extraction of impacted mandibular third molars. *Oral Surg Oral Med Oral Pathol Oral Radiol Endod* 2009; 108(2): 156-61.
- [19] Hayreh SS, Kolder HE, Weingeist TA. Central retinal artery occlusion and retinal tolerance time. *Ophthalmology* 1980; 87(1): 75-8.

- [20] Amarillas-Escobar ED, Toranzo-Fernandez JM, Martinez-Rider R, Noyola-Frias MA, Hidalgo-Hurtado JA, Serna VM, et al. Use of therapeutic laser after surgical removal of impacted lower third molars. *J Oral Maxillofac Surg* 2010; 68(2): 319-24.
- [21] Limeres J, Sanroman JF, Tomas I, Diz P. Patients' perception of recovery after third molar surgery following postoperative treatment with moxifloxacin versus amoxicillin and clavulanic acid: a randomized, double-blind, controlled study. *J Oral Maxillofac Surg* 2009; 67(2): 286-91.
- [22] Monaco G, Tavernese L, Agostini R, Marchetti C. Evaluation of antibiotic prophylaxis in reducing postoperative infection after mandibular third molar extraction in young patients. *J Oral Maxillofac Surg* 2009; 67(7): 1467-72.
- [23] Siddiqi A, Morkel JA, Zafar S. Antibiotic prophylaxis in third molar surgery: A randomized double-blind placebo-controlled clinical trial using split-mouth technique. *Int J Oral Maxillofac Surg* 2010; 39(2): 107-14.
- [24] Lago-Mendez L, Diniz-Freitas M, Senra-Rivera C, Seoane-Pesqueira G, Gandara-Rey JM, Garcia-Garcia A. Postoperative recovery after removal of a lower third molar: role of trait and dental anxiety. *Oral Surg Oral Med Oral Pathol Oral Radiol Endod* 2009; 108(6): 855-60.
- [25] Juhl GI, Jensen TS, Norholt SE, Svensson P. Central sensitization phenomena after third molar surgery: a quantitative sensory testing study. *Eur J Pain* 2008; 12(1): 116-27.
- [26] Campbell A, Costello BJ. Retrieval of a displaced third molar using navigation and active image guidance. *J Oral Maxillofac Surg* 2010; 68(2): 480-5.

Please cite this paper as: Beshkar M, Momeni M, Hasheminasab M. Third molar surgery: Insights from recent literature. *J Craniomax Res* 2014; 1(1-2): 2-7.